



“Osteología de cabeza, cuello, tronco y miembro torácico”


Cintya Borroni G. MV. Msc
cintyab@gmail.com

OSTEOLOGÍA DE CABEZA



[dreamstime.com](https://www.dreamstime.com/)

Topografía



- 1.–3. *regio nasalis* – nasal region
1. *regio dorsalis nasi* – dorsal region of nose (bridge of nose)
2. *regio lateralis nasi* – lateral region of nose
3. *regio naris* – region of nostril
- 4., 8. *regio oralis* – oral region
4. *planum nasolabiale* – nasolabial surface
5. *regio maxillaris* – maxillary region
6. *regio buccalis* – region of cheek
7. *regio mandibularis* – mandibular region
8. *regio labialis maxillaris et labialis mandibularis* – region of upper and lower lips
9. *regio mentalis* – region of chin
10. *regio frontalis* – frontal region (forehead)
11. *regio orbitalis (regio palpebralis superior et palpebralis inferior)* – orbital region (region of upper and lower eyelids)
12. *regio infraorbitalis* – infraorbital region
13. *regio masseterica* – masseteric region
14. *margo mandibular* – margin of mandible
15. *regio temporalis* – temporal region (temple)
16. *regio parietalis* – parietal region (poll)
17. *regio zygomatica* – zygomatic region
18. *regio articulationis temporomandibularis* – region of temporomandibular articulation
- 19., 20. *regio auricularis* – region of external ear
20. *auricula* – external ear
21. *regio parotidea* – parotid region
- 22., 23. *regio colli ventralis* – ventral region of neck
22. *regio laryngea* – laryngeal region
23. *plicae (plicae ventralis colli)* – ventral fold of neck
24. *processus transversus atlantis* – transverse process of atlas
25. *sulcus jugularis* – jugular sulcus
26. *cornu* – horn

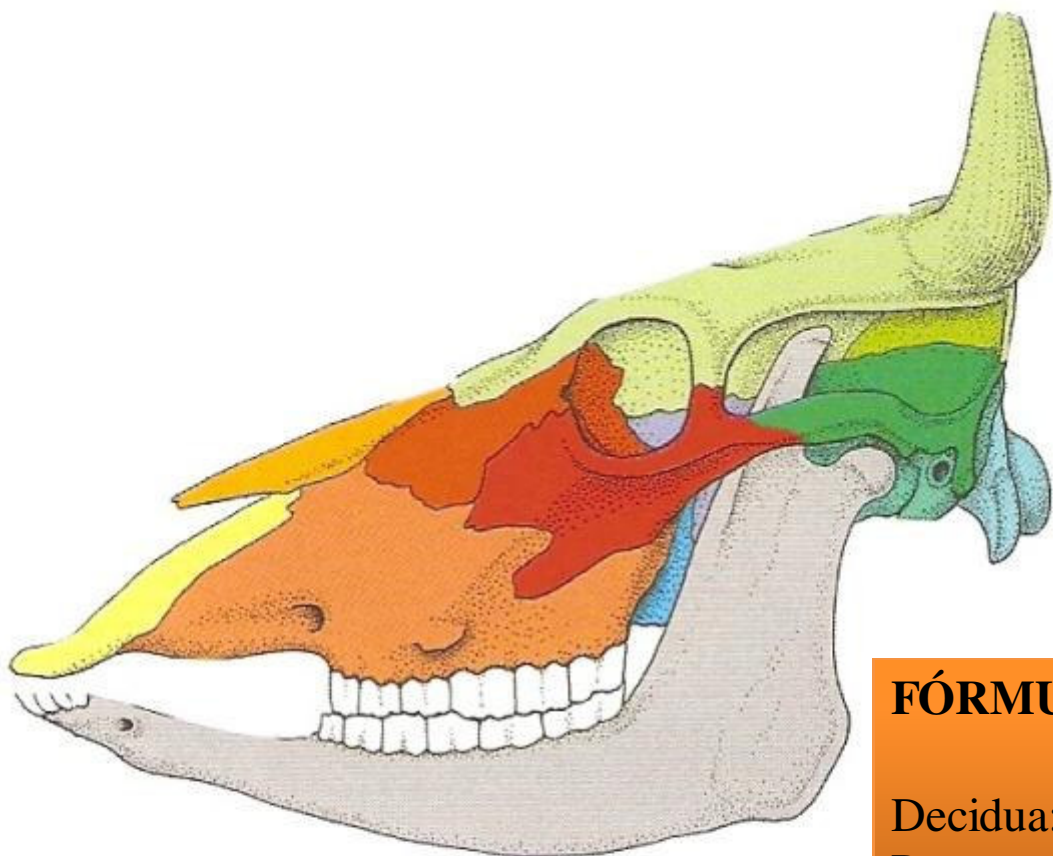
Osteología de cabeza

HUESOS DEL CRÁNEO

- Occipital
- Parietal
- Temporal
- Frontal
- Pterigoideo
- Etmoides
- Vómer
- Esfenoides
 - Preesfenoides
 - Basiesfenoides

HUESOS DE LA CARA

- Maxilar
- Mandíbula
- Nasal
- Concha nasal ventral
- Lagrimal
- Incisivo
- Palatino
- Cigomático



A

- Hueso incisivo
- Hueso nasal
- Maxilar
- Hueso lagrimal

- Hueso cigomático
- Hueso frontal
- Hueso parietal
- Hueso interparietal

FÓRMULA DENTAL BOVINO

Decidua: 2 (I 0/4; C 0/0; PM 3/3)= 20

Permanente: 2 (I 0/4; C 0/0; PM 3/3; M 3/3)= 32

Permanente: 2 (I 0/4; C 0/0; PM 3/3; M 3/3)= 32

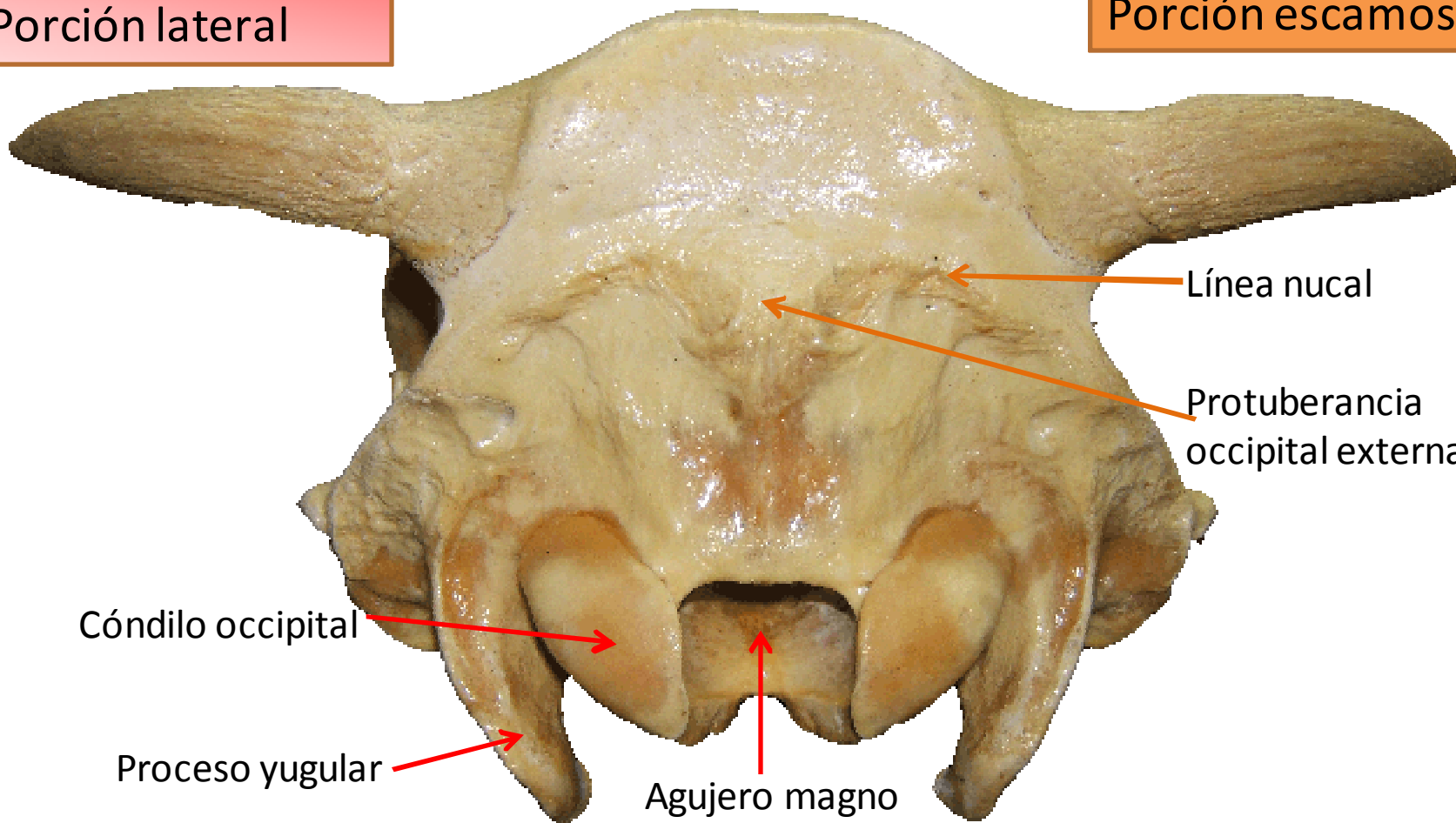
Decidua: 2 (I 0/4; C 0/0; PM 3/3)= 20

Huesos del cráneo

Occipital

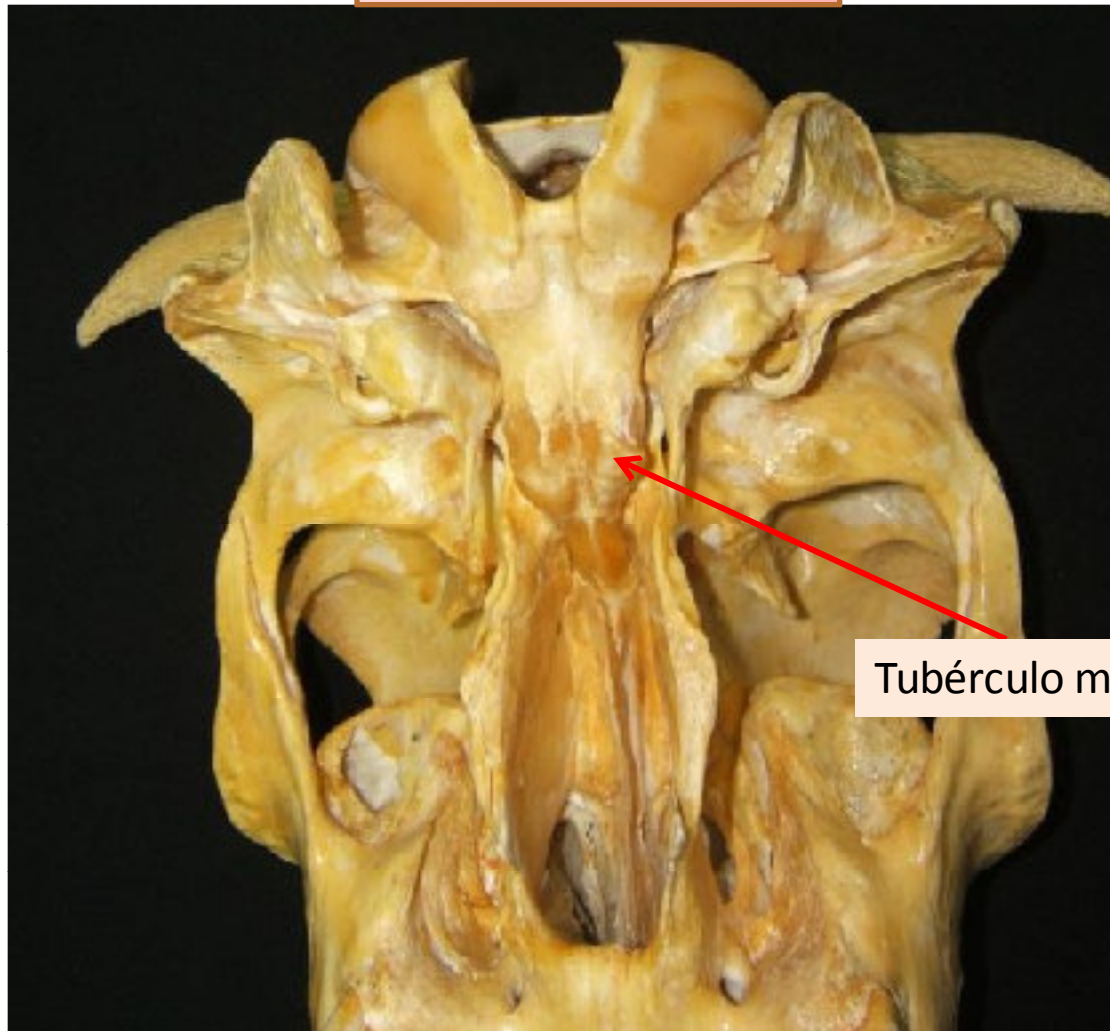
Porción lateral

Porción escamosa



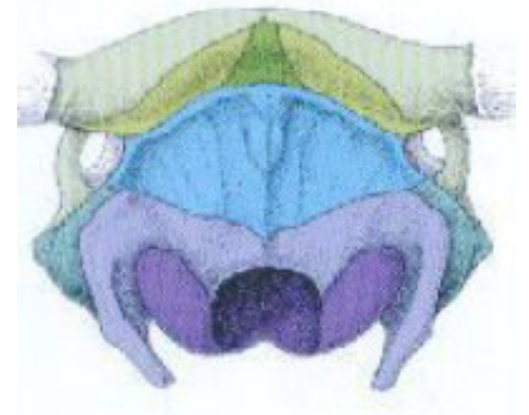
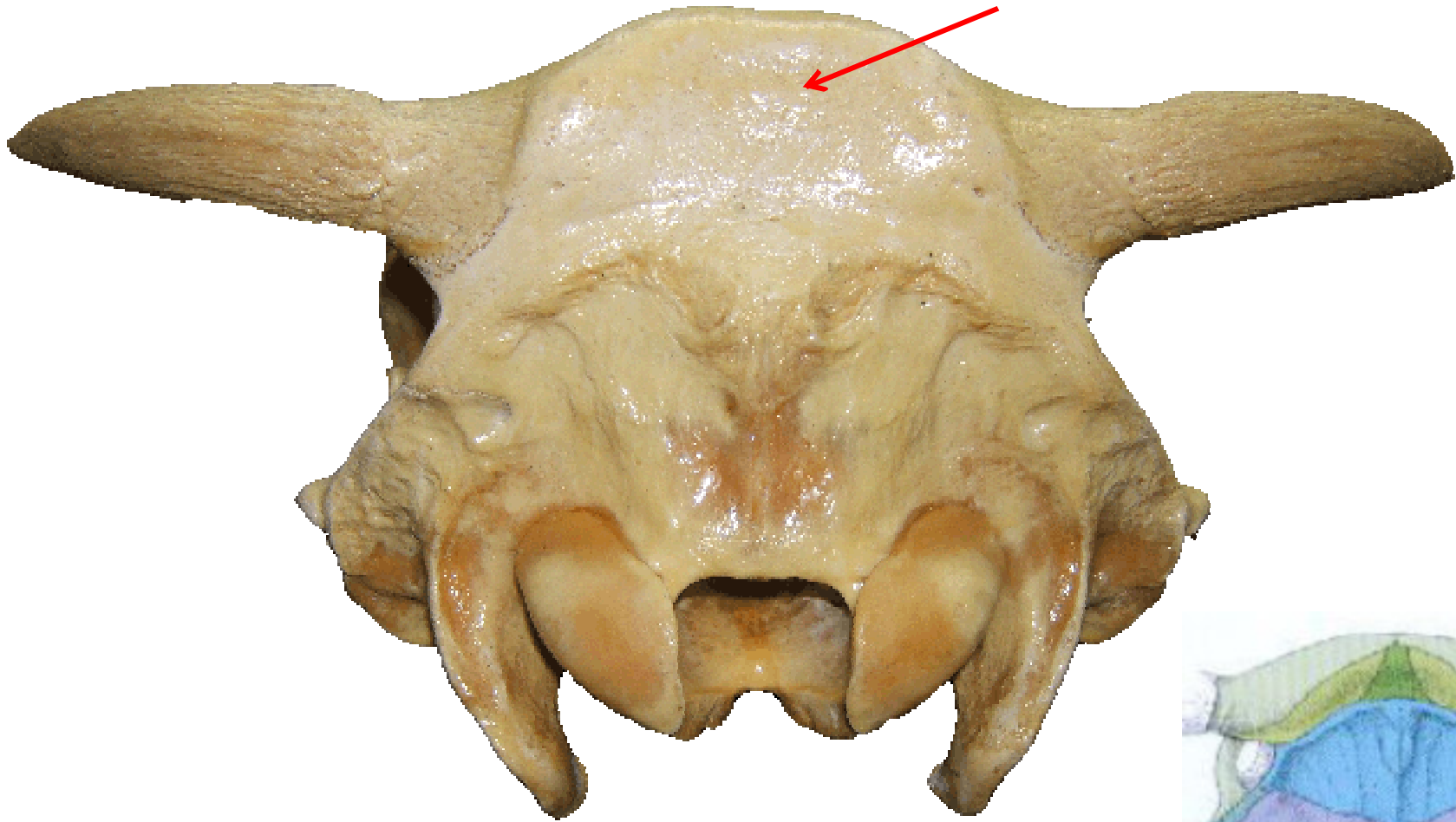
Occipital

Porción basilar



Tubérculo muscular

Parietal

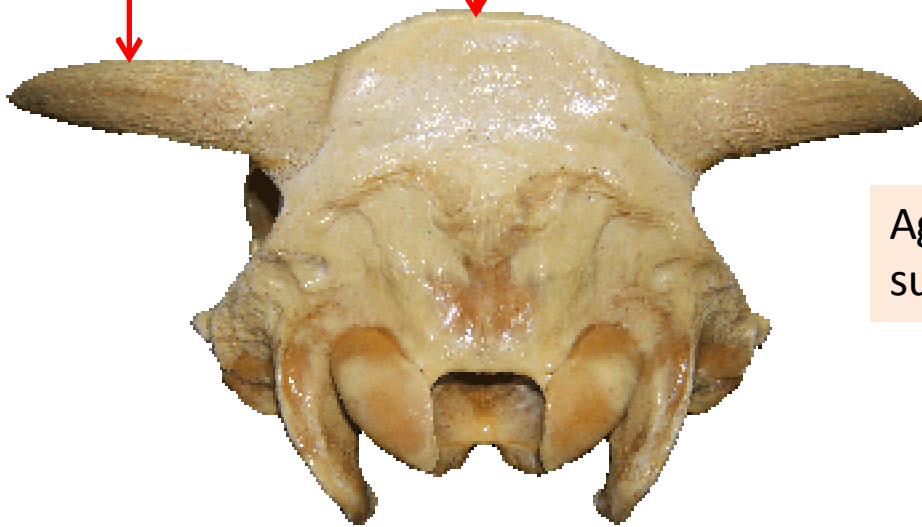


Frontal

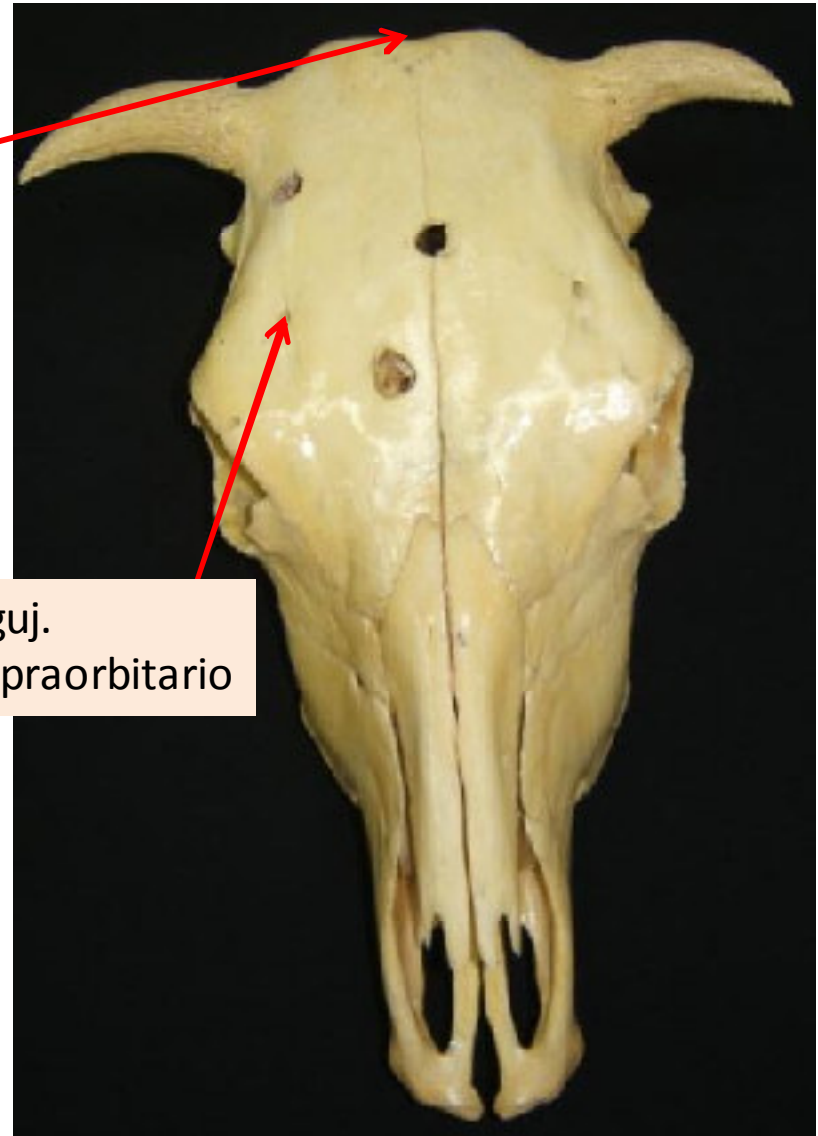
SENO FRONTAL

Proceso
cornual

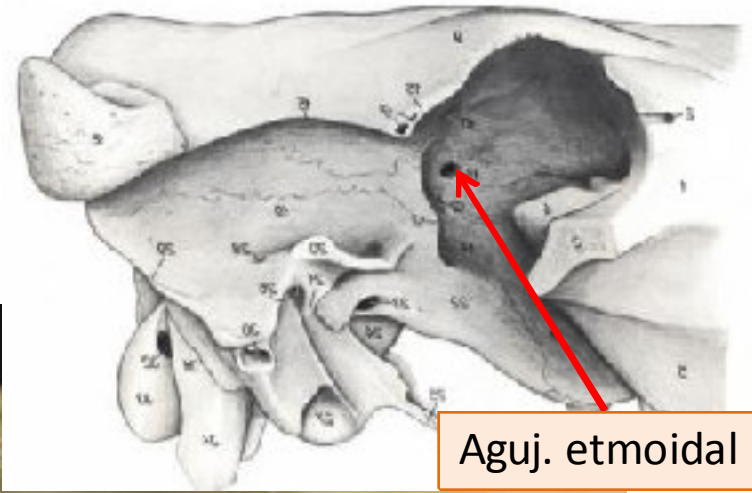
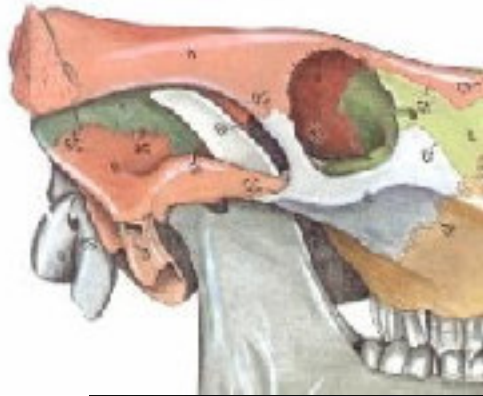Protuberancia
intercornual



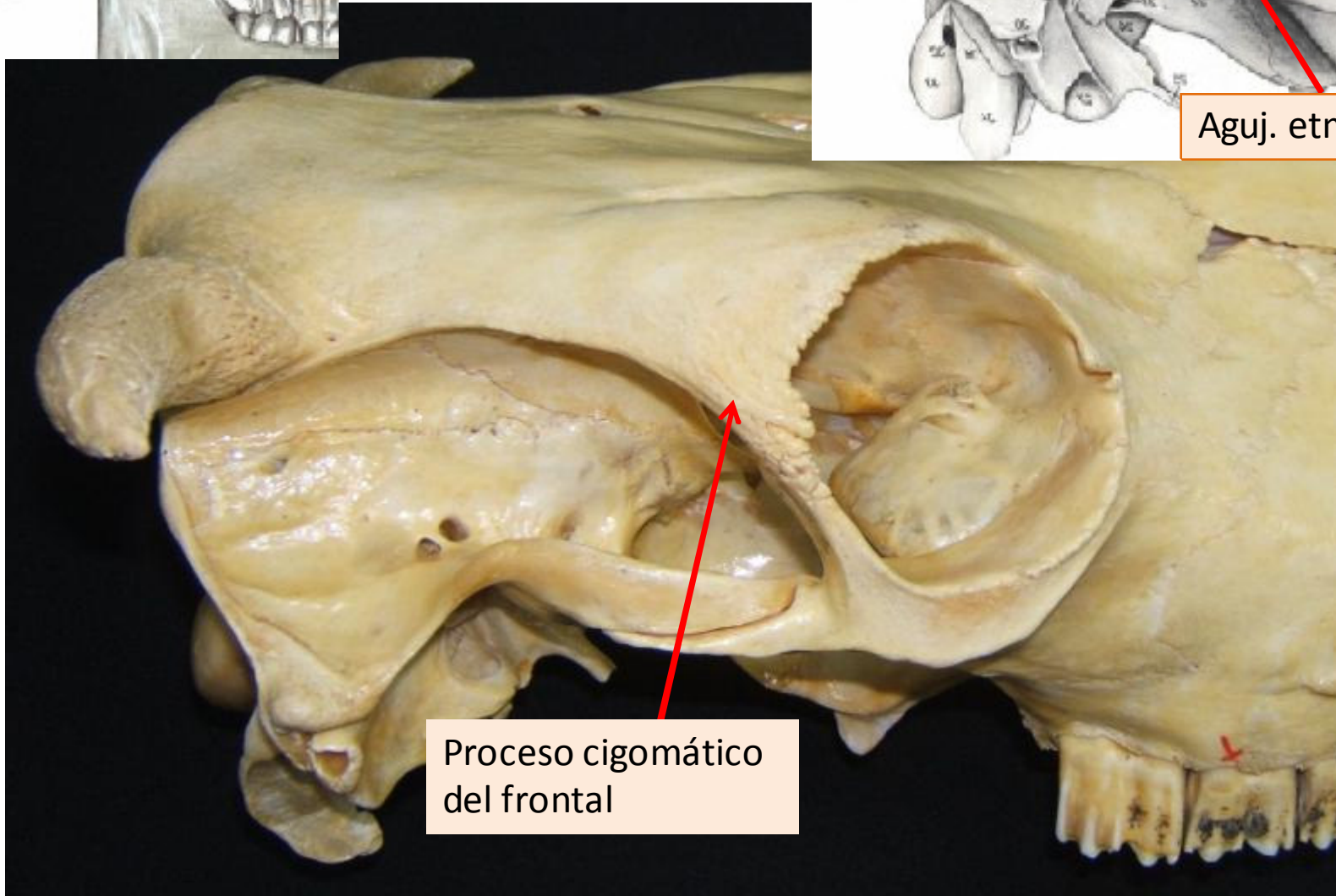
Aguj.
supraorbitario



Frontal



Aguj. etmoidal



Proceso cigomático del frontal

Temporal

Porción escamosa

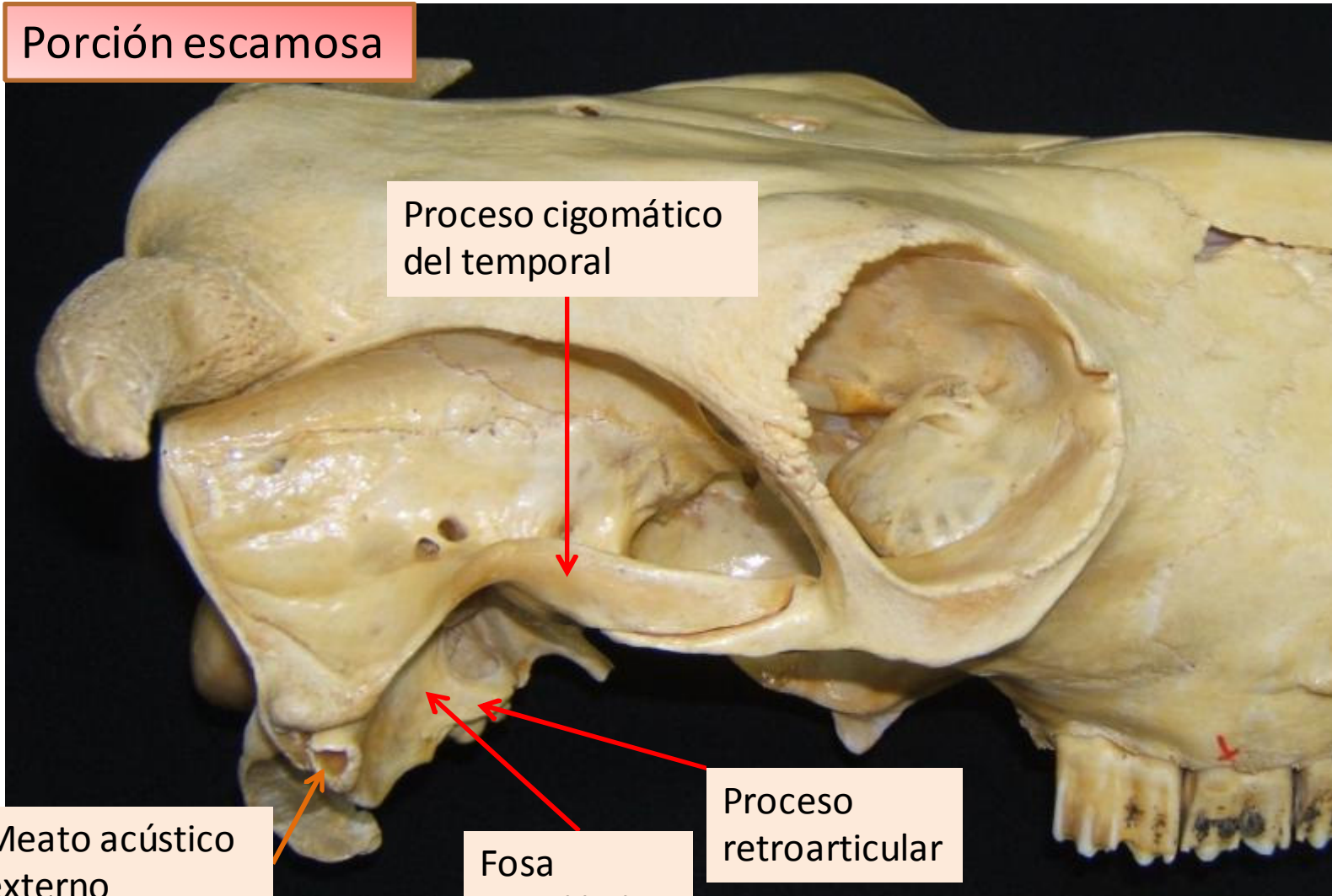
Proceso cigomático
del temporal

Meato acústico
externo

Porción timpánica

Fosa
mandibular
(ATM)

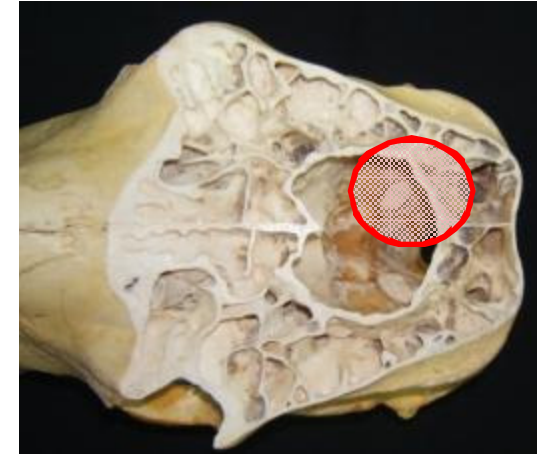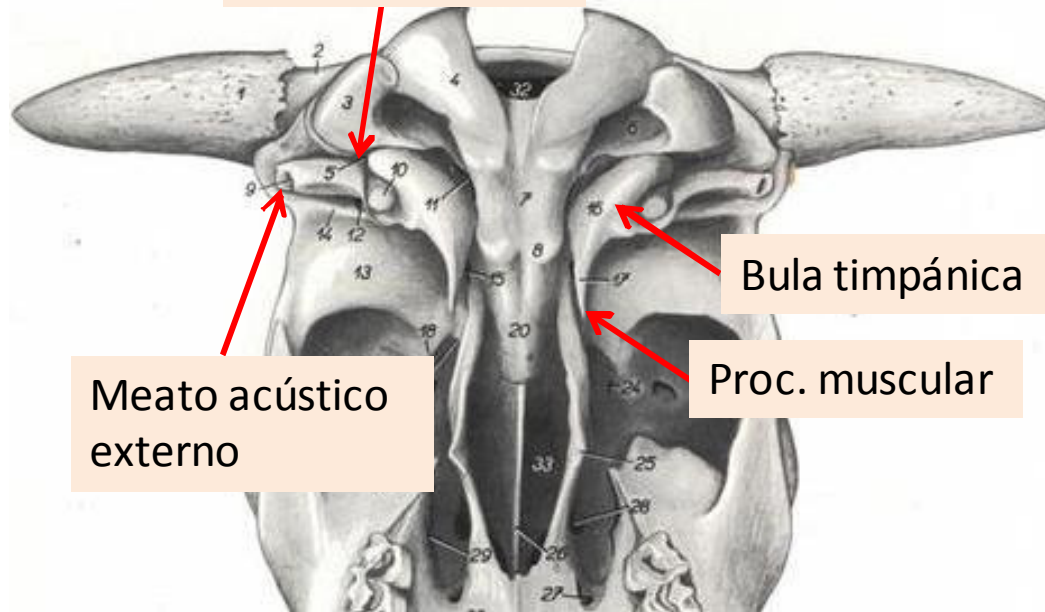
Proceso
retroarticular



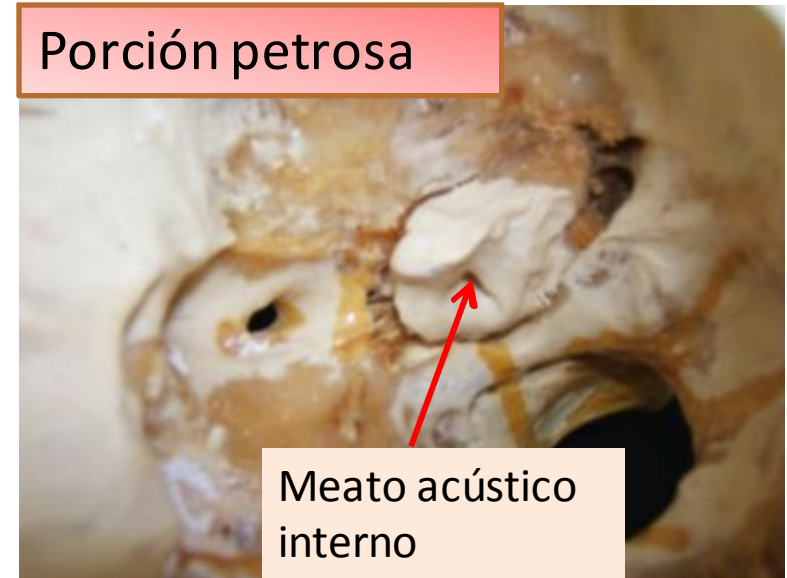
Temporal

Porción timpánica

Aguj.
estilomastoídeo



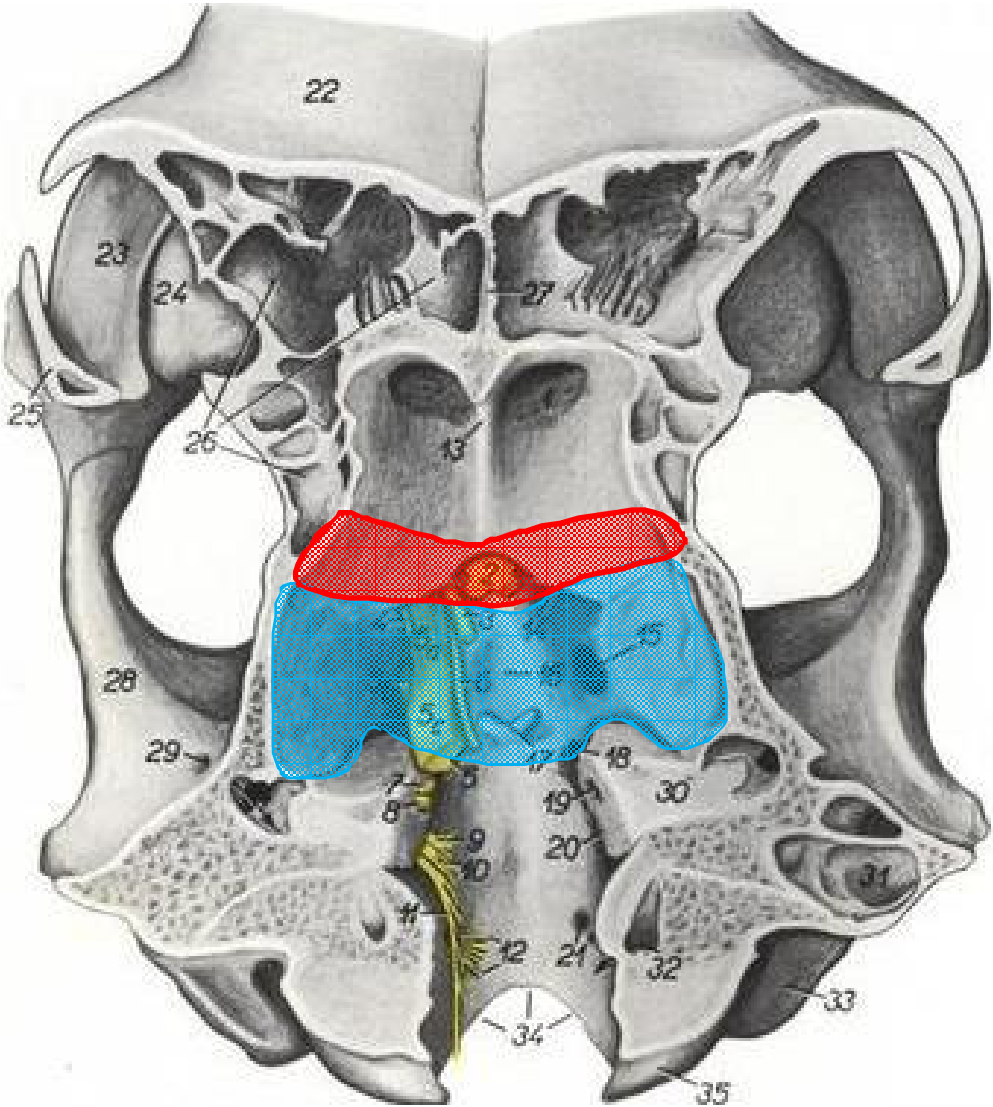
Porción petrosa



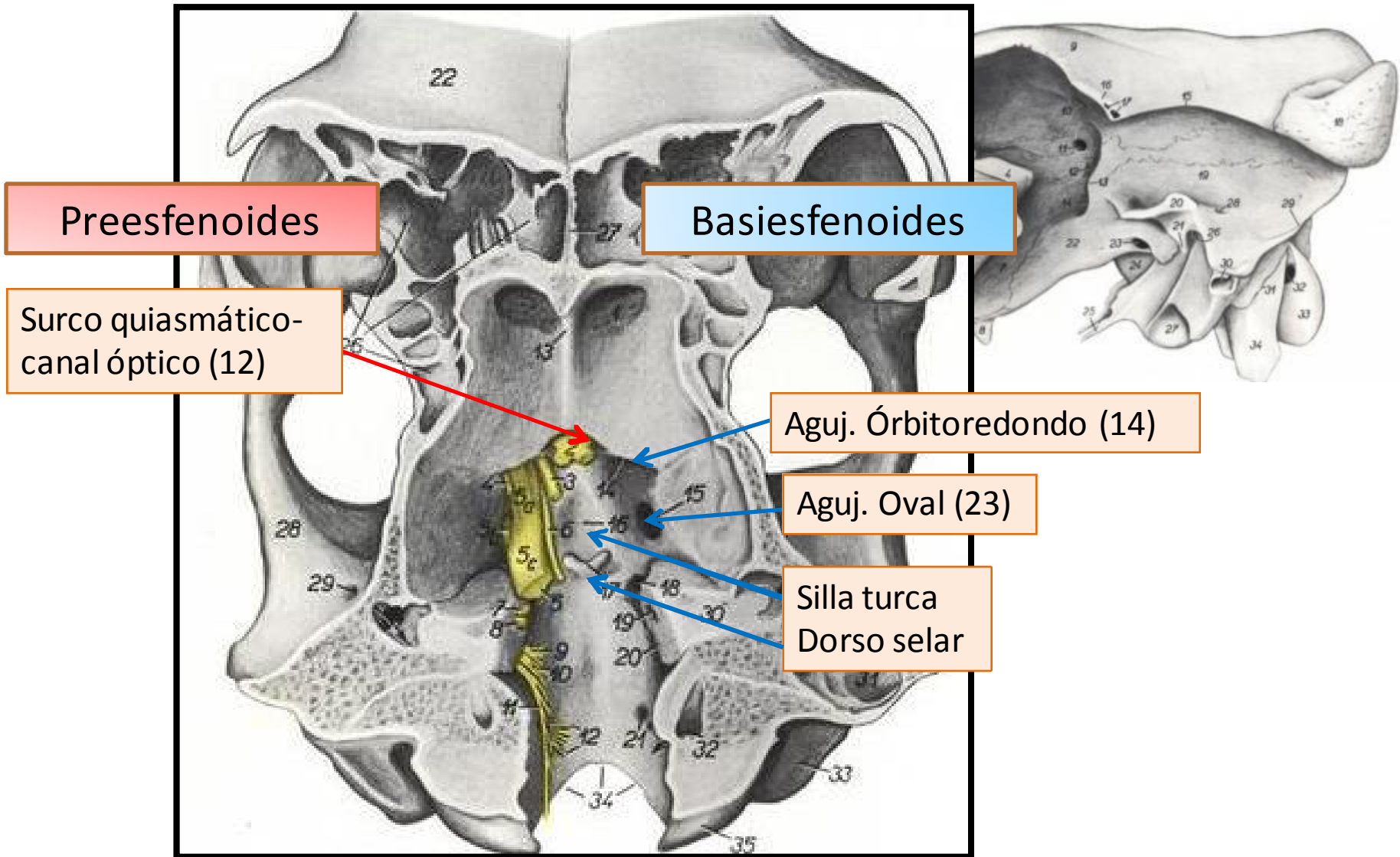
Esfenoides

Preesfenoides:
Cuerpo
Alas

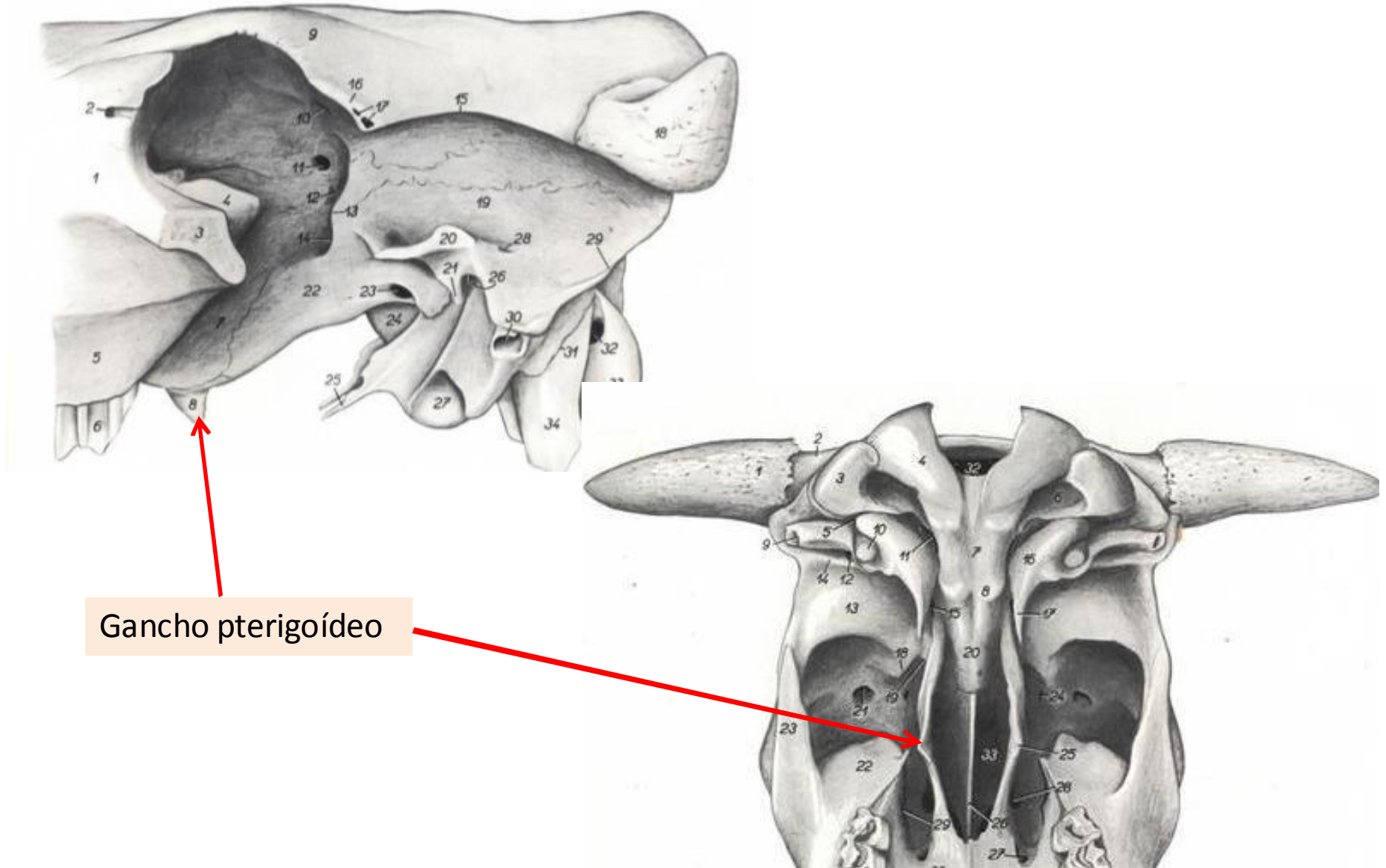
Basiesfenoides:
Cuerpo
Alas



Esfenoides

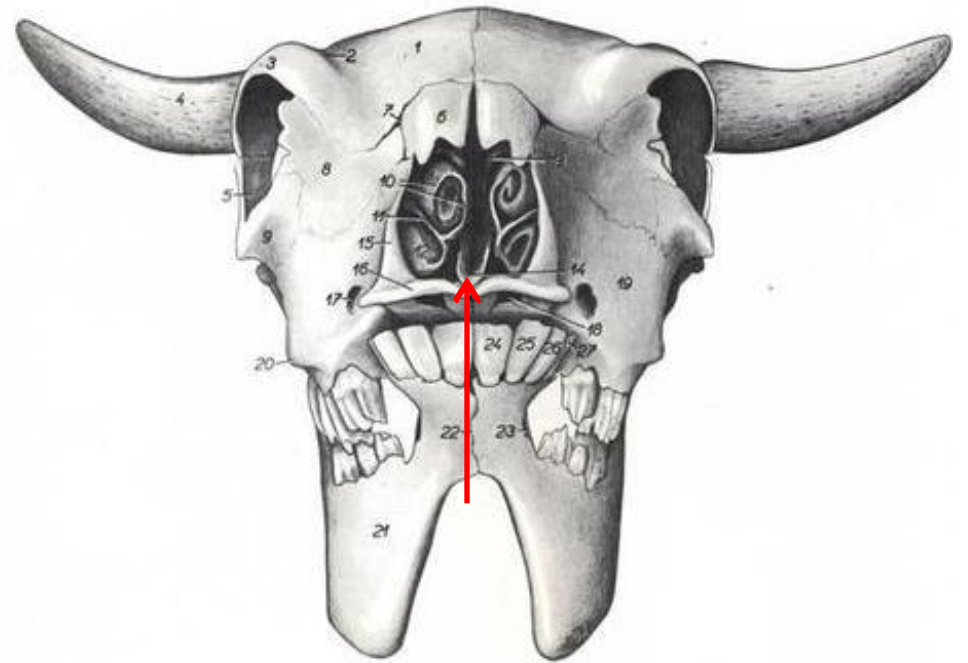
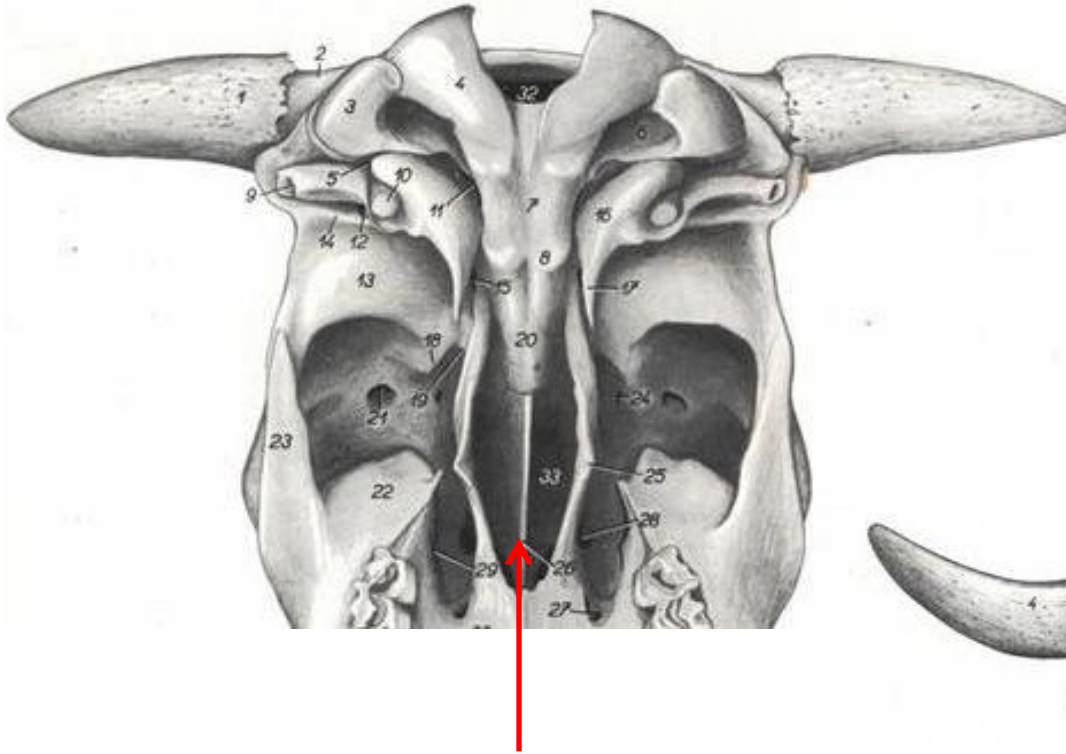


Pterigoides

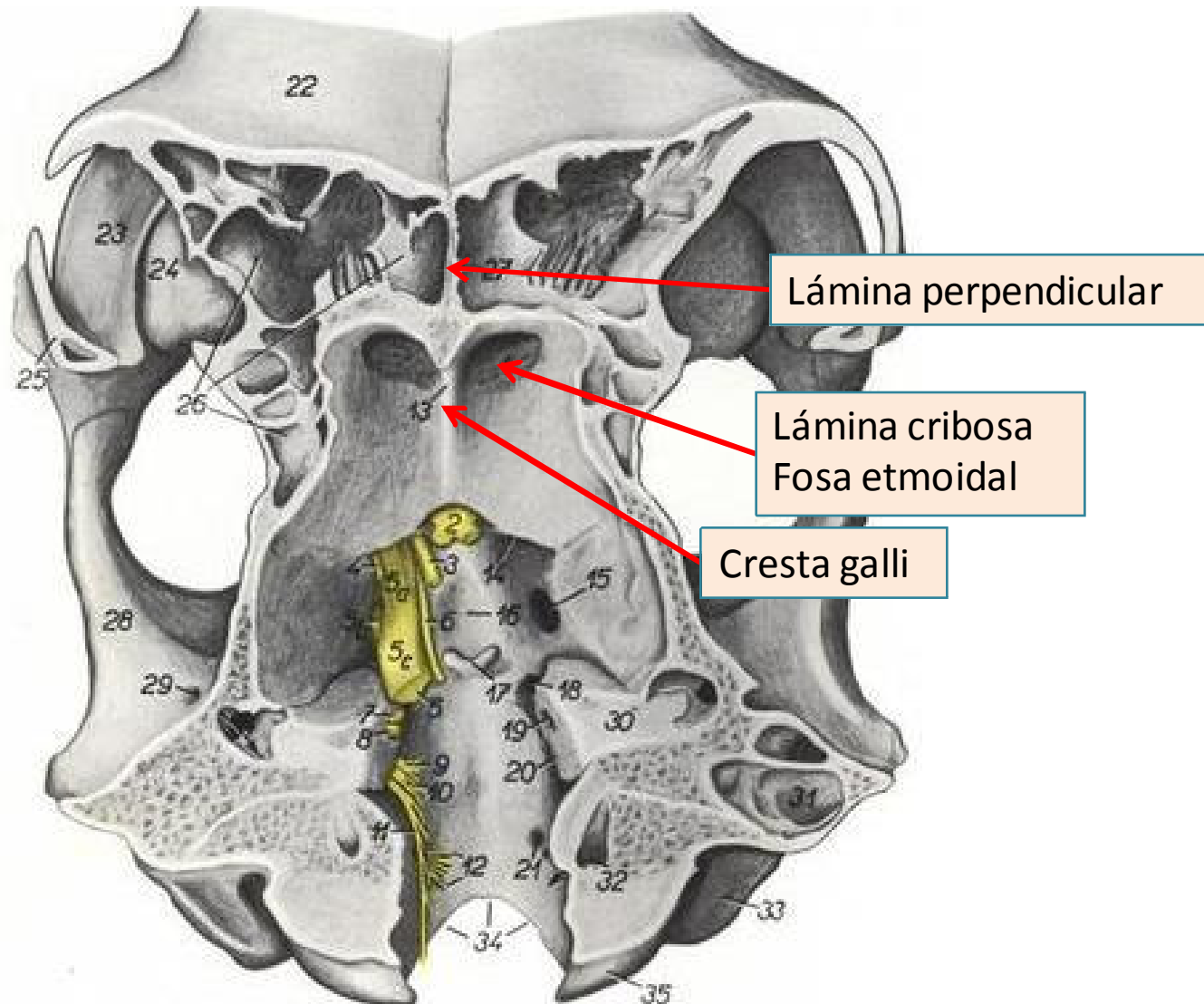


Gancho pterigoideo

Vómer



Etmoides

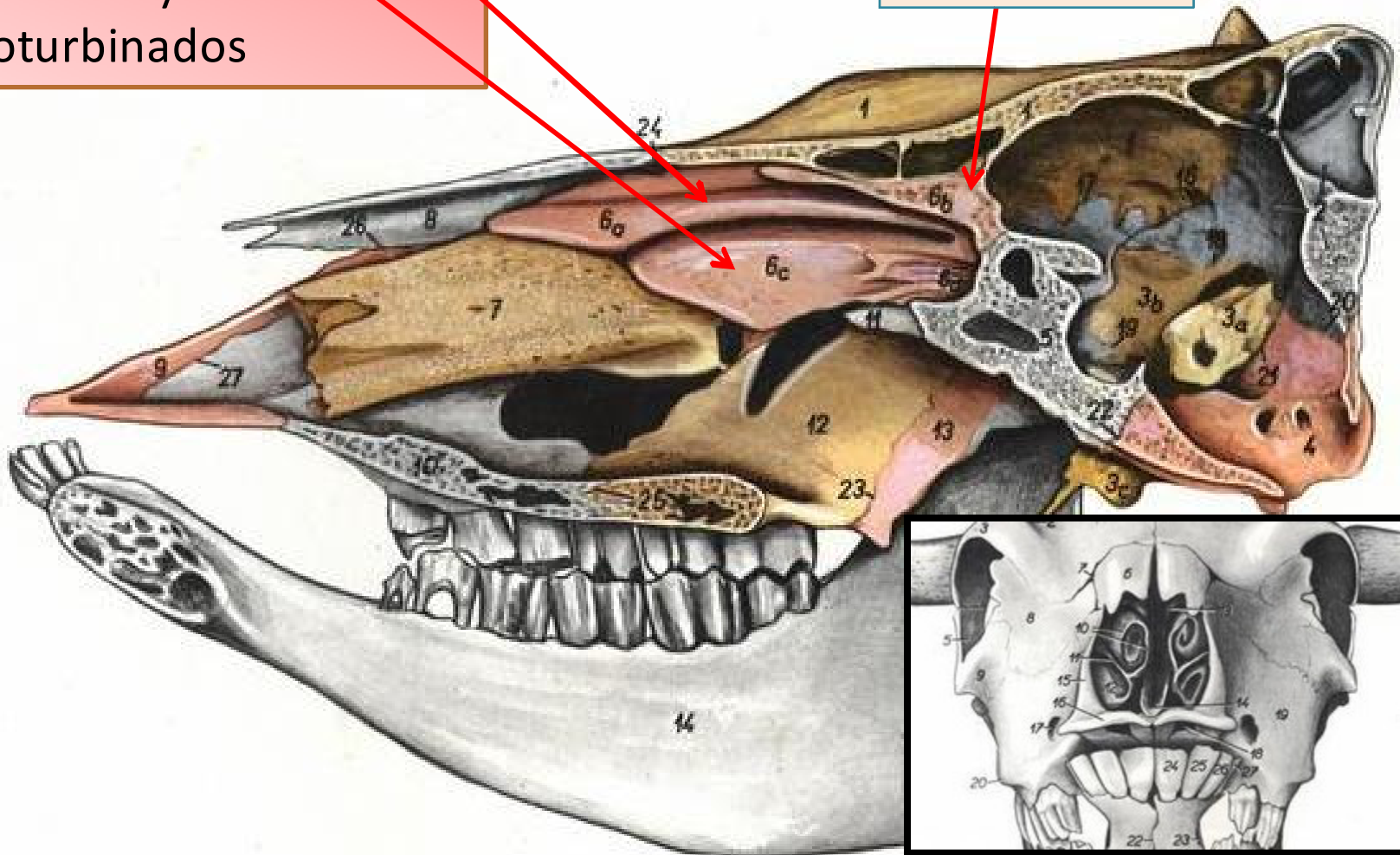


Etmoides

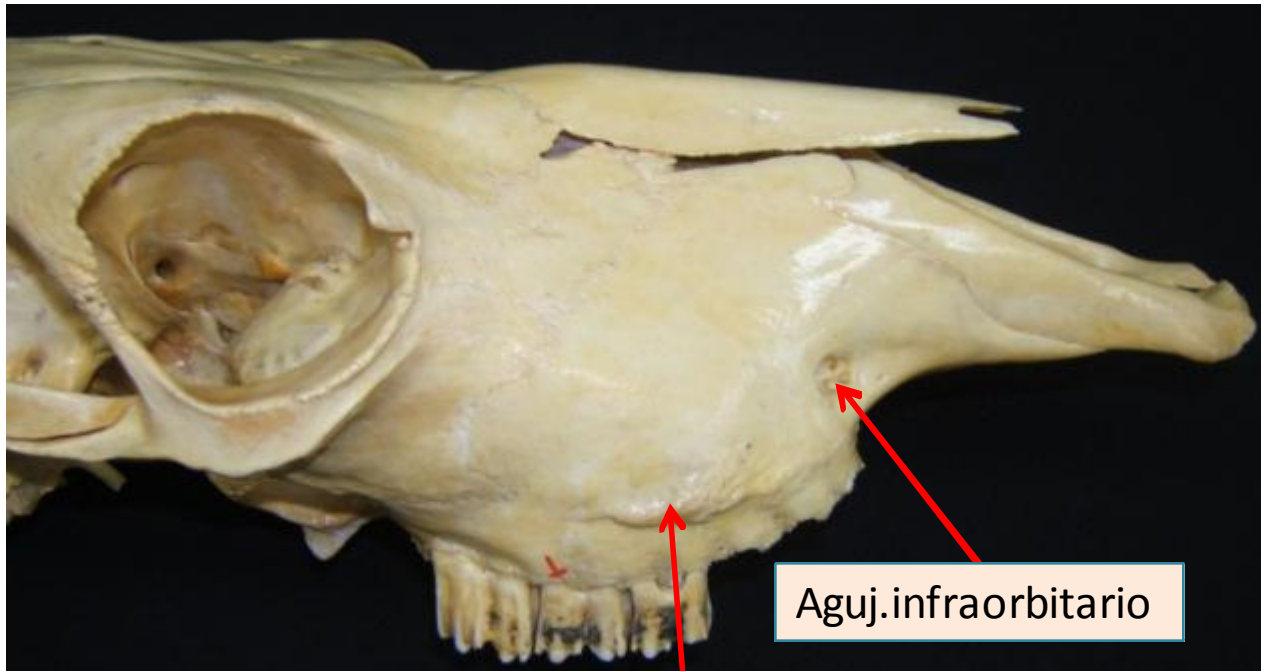
Laberinto etmoidal:

- Endoturbinados: I concha nasal dorsal y II media
- Ectoturbinados

Lámina perpendicular

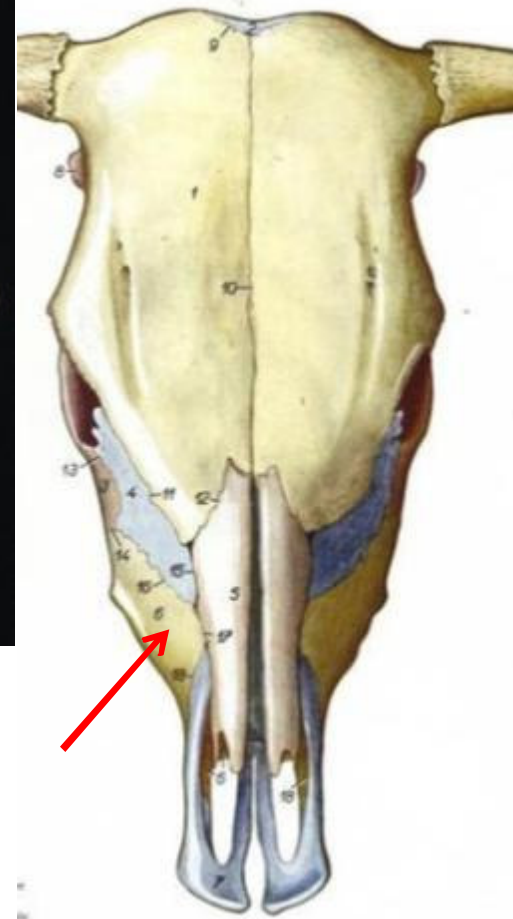


Huesos del la cara Maxilar



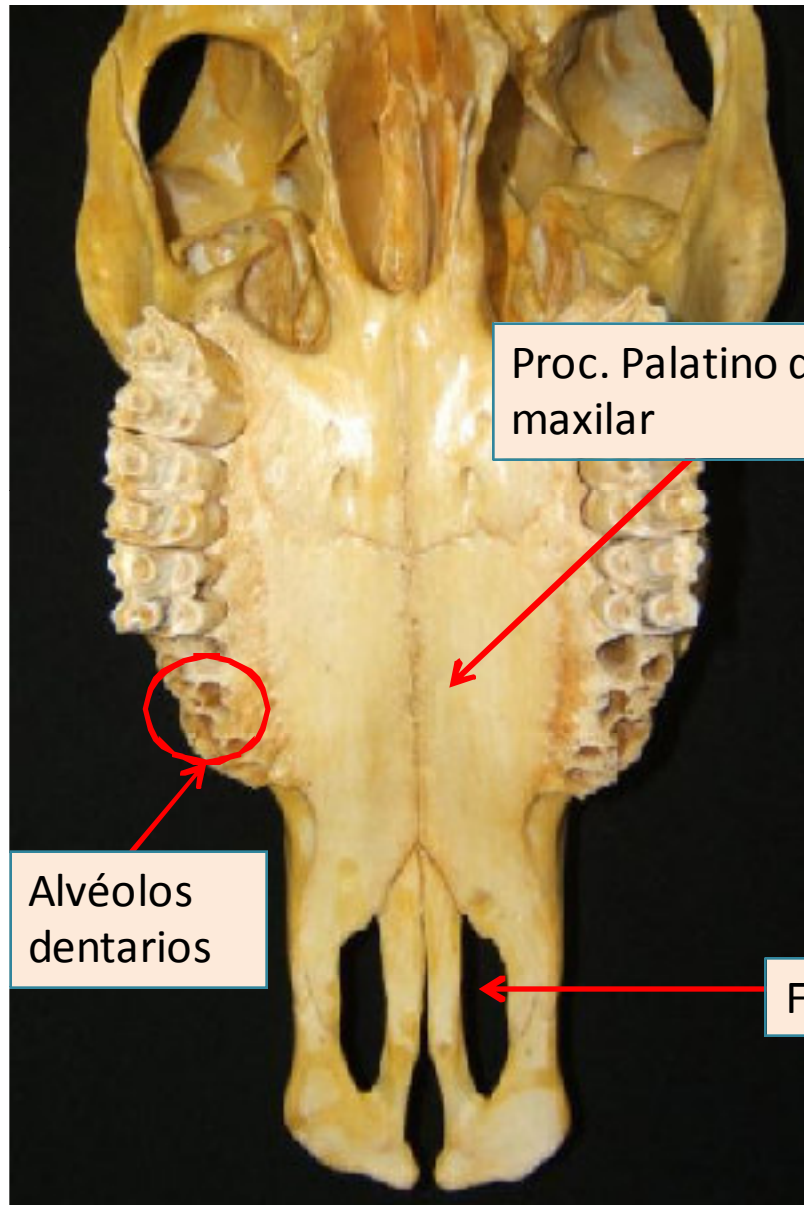
Aguj.infraorbitario

Cresta y tubérculo facial



Aguj. Maxilar - Canal infraorbitario – aguj. infraorbitario

Maxilar

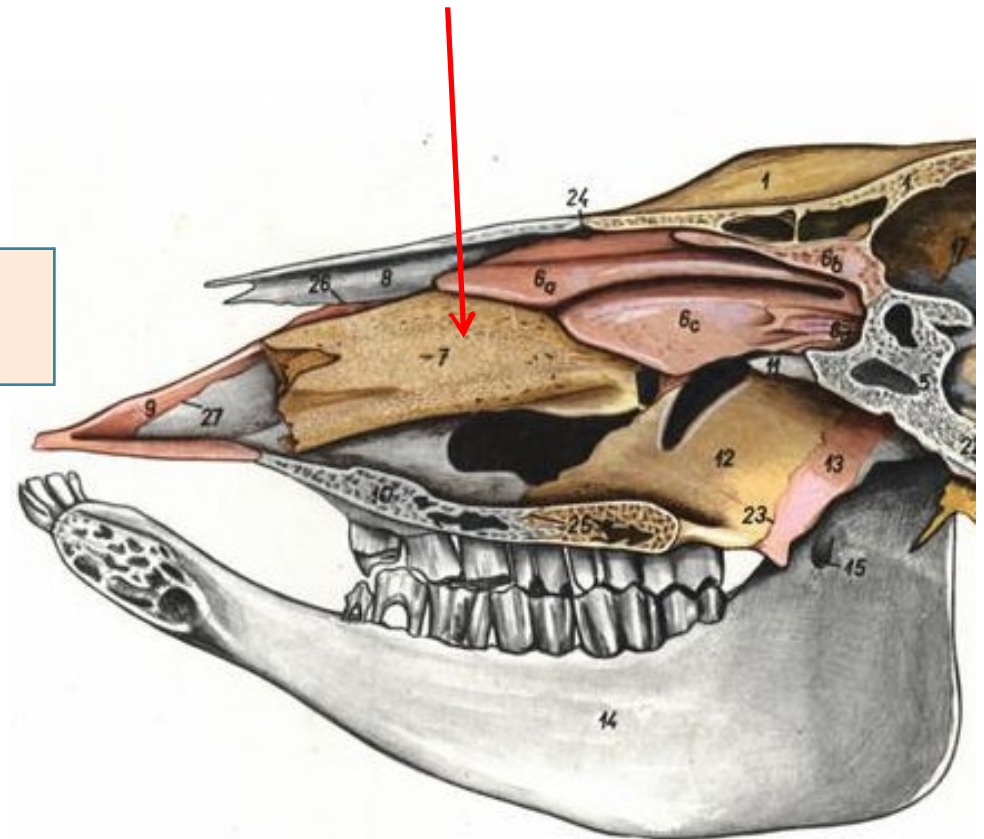


Proc. Palatino del maxilar

Alvéolos dentarios

Fisura palatina

Concha nasal ventral



Palatino

Fosa pterigopalatina

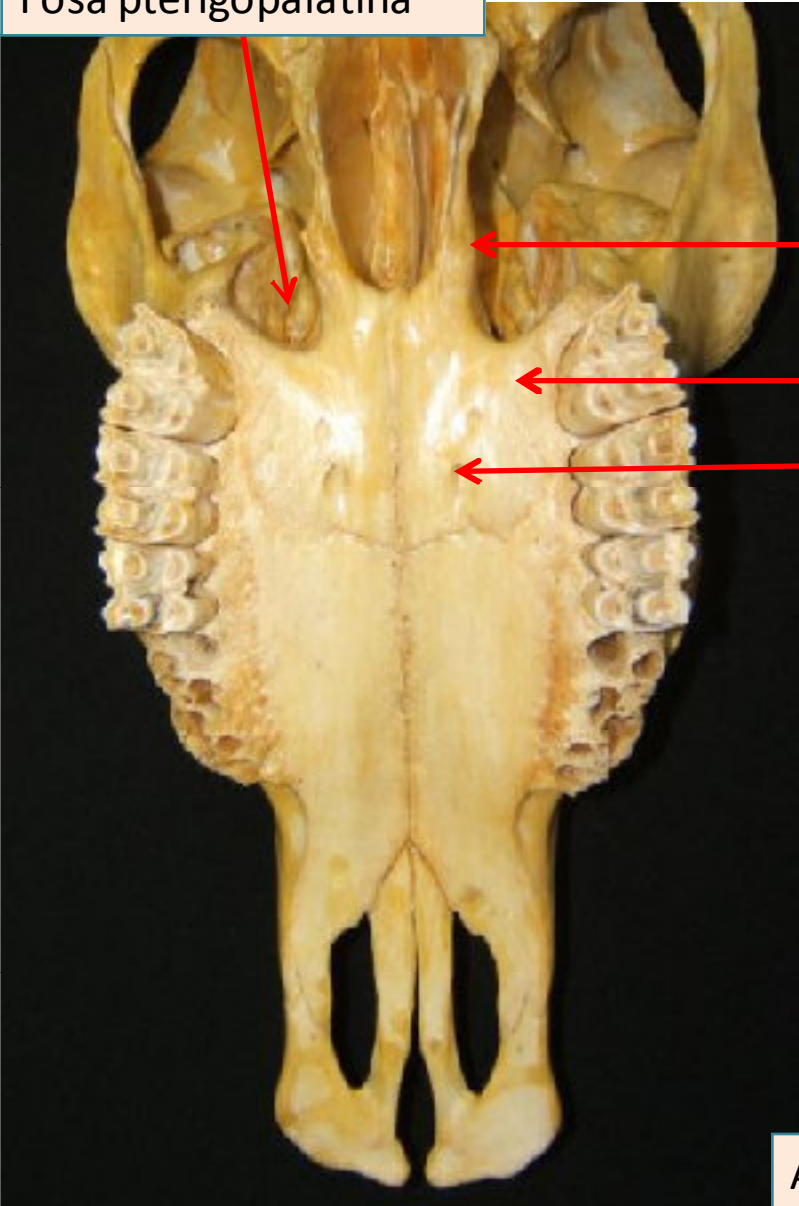


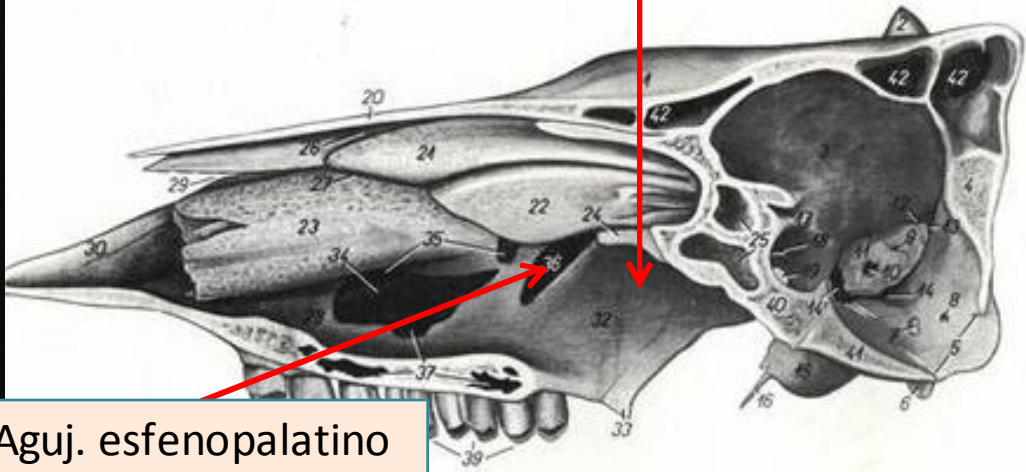
Lámina perpendicular

Lámina horizontal

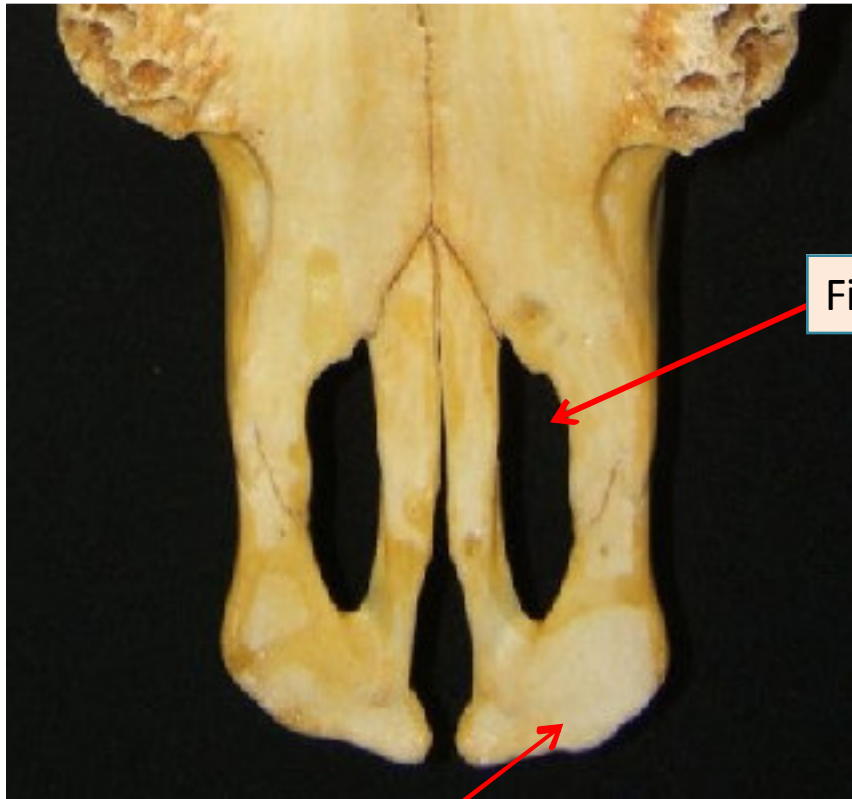
Aguj. Palatino mayor

Lámina perpendicular

Aguj. esfenopalatino

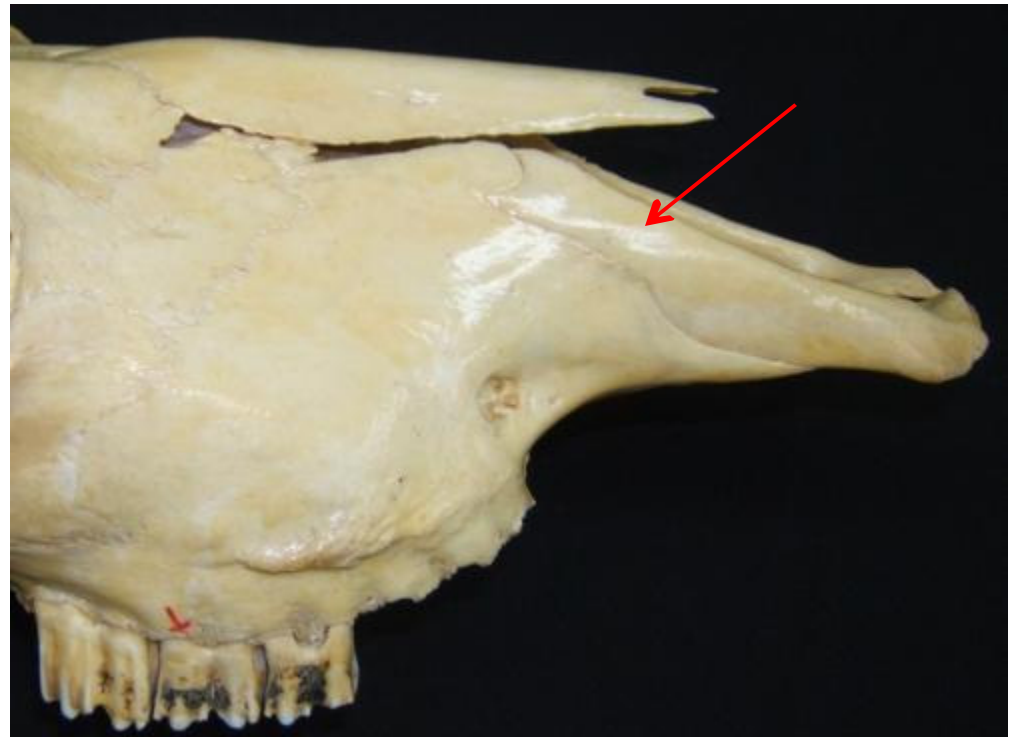


Incisivo

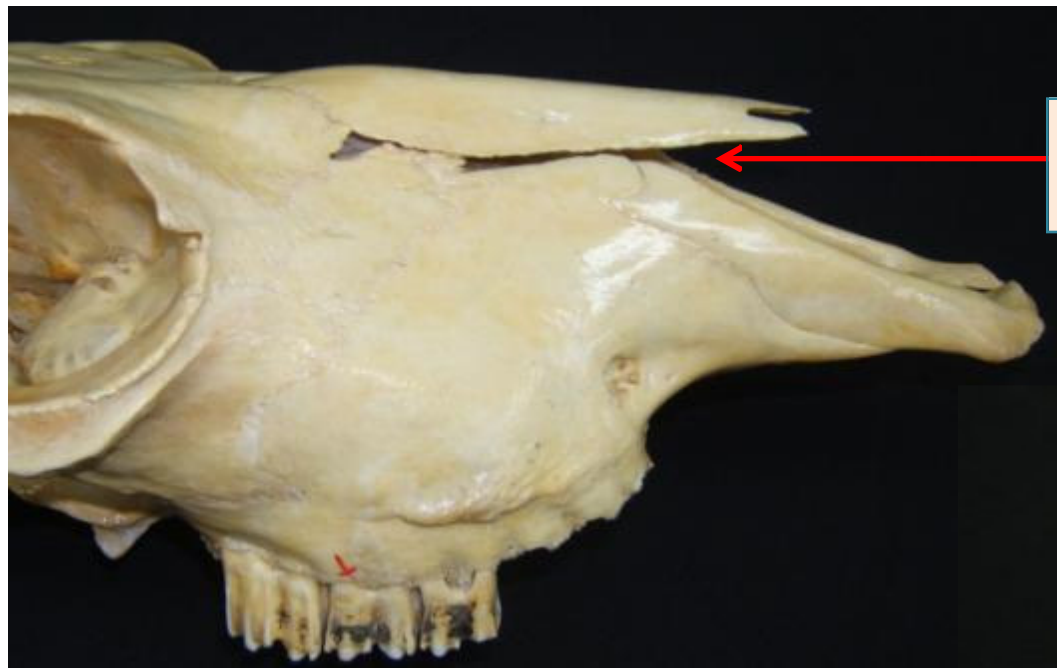


Fisura palatina

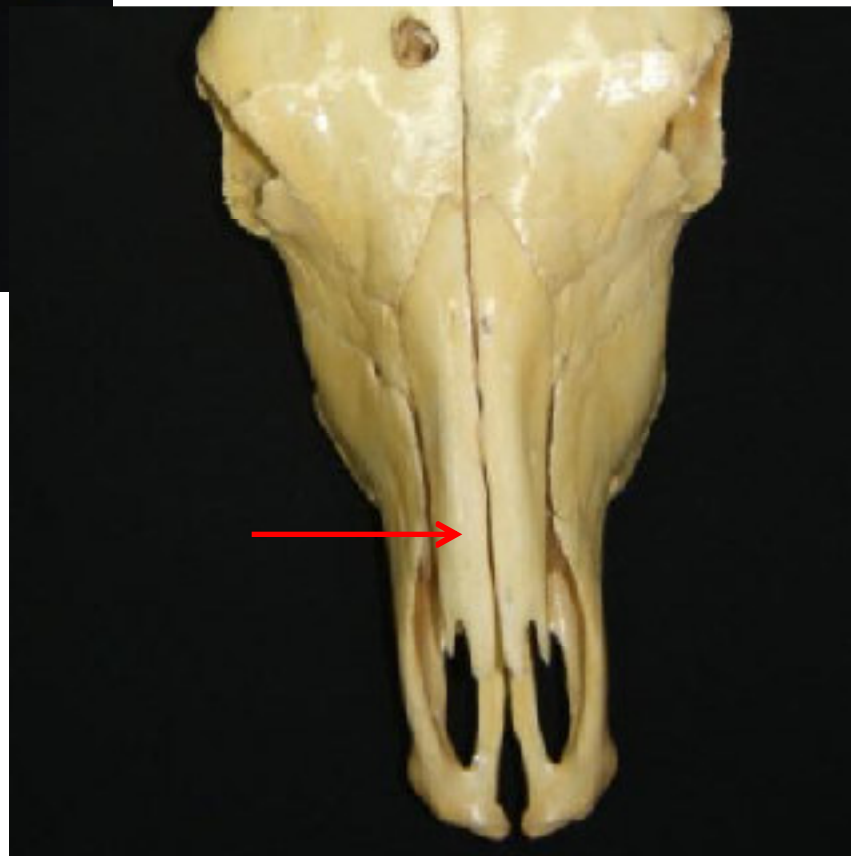Cuerpo (No alvéolos)



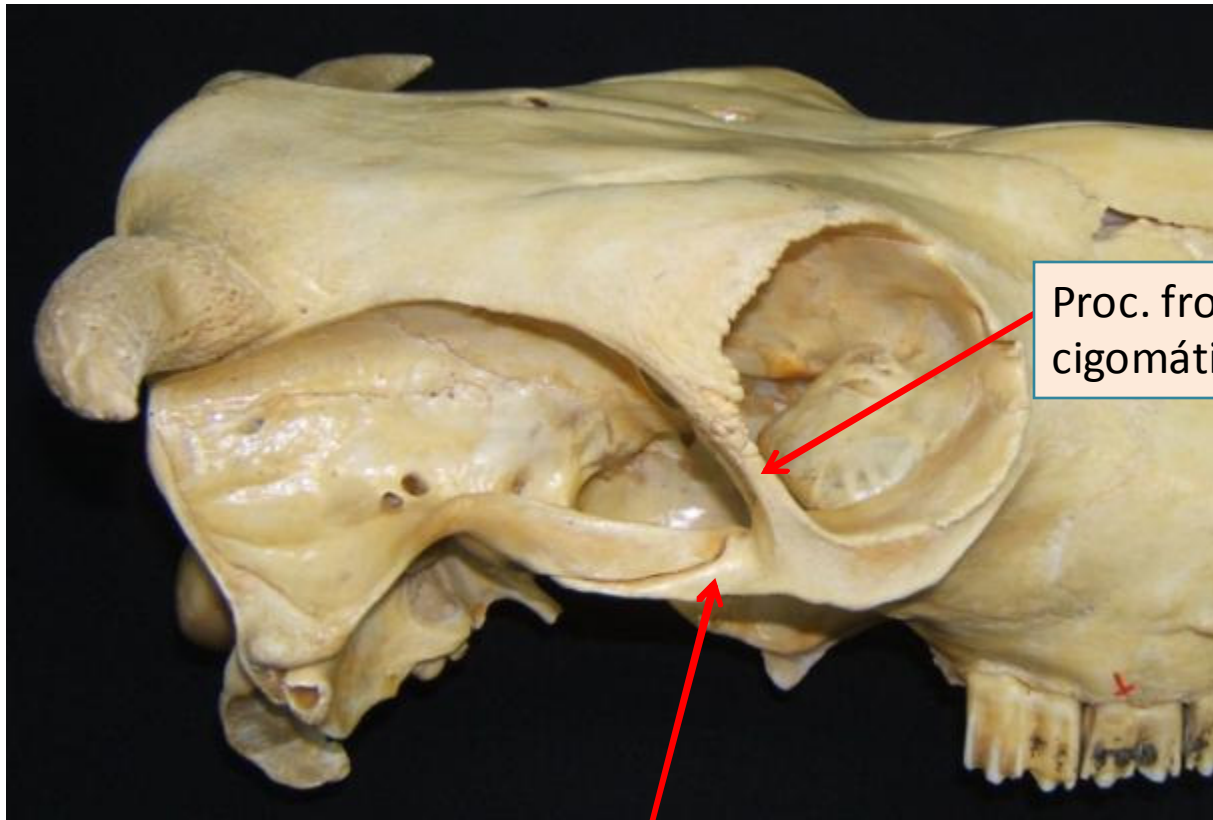
Nasales



Incisura
nasoincisiva

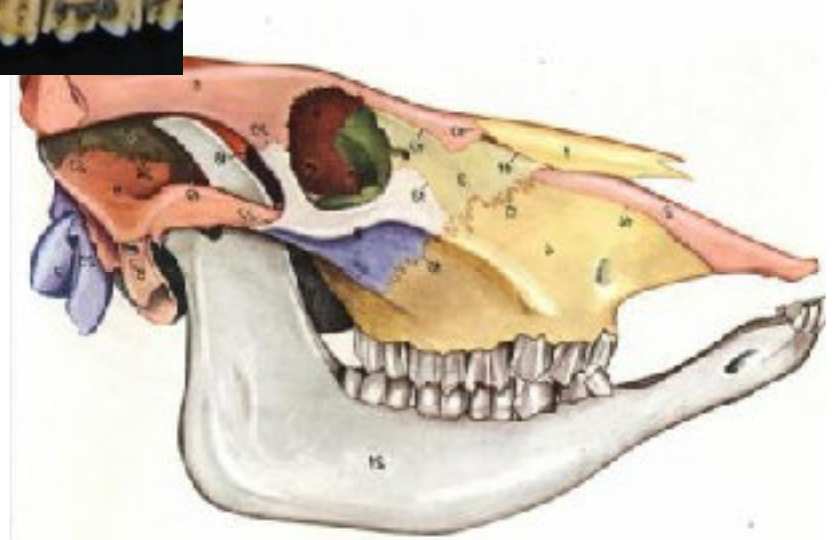


Cigomático



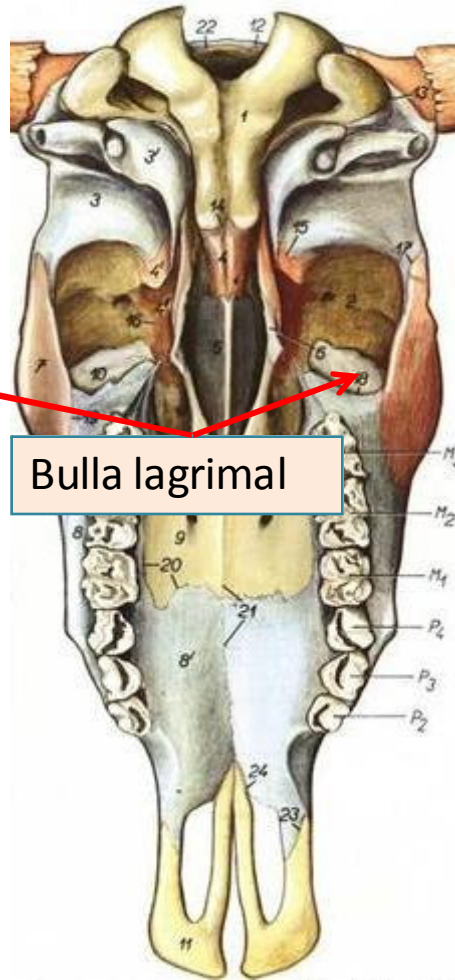
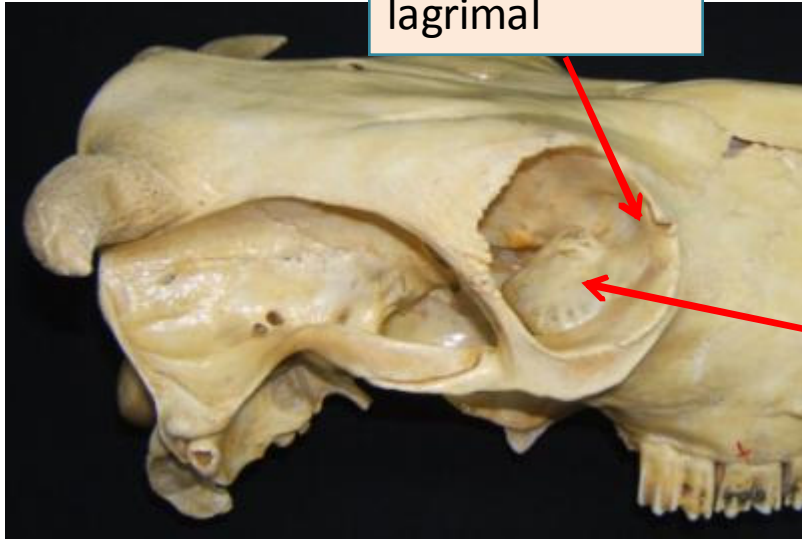
Proc. frontal del cigomático

Proc. Temporal del cigomático

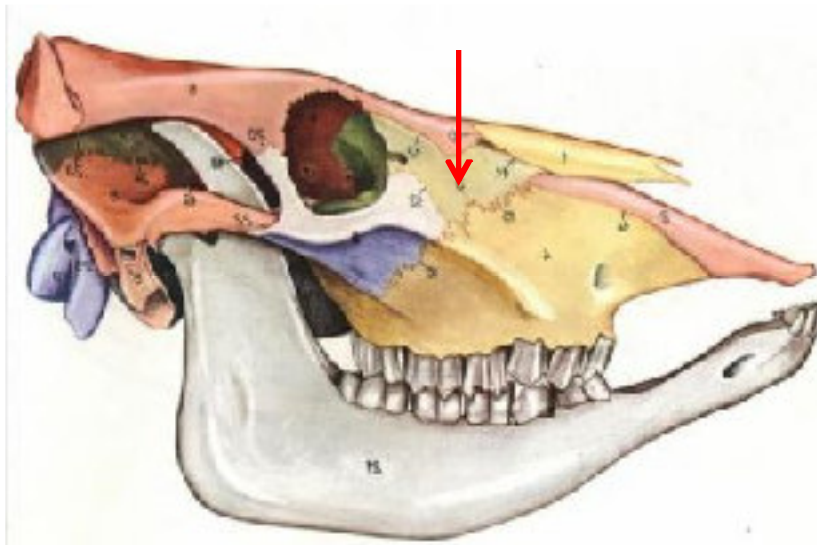
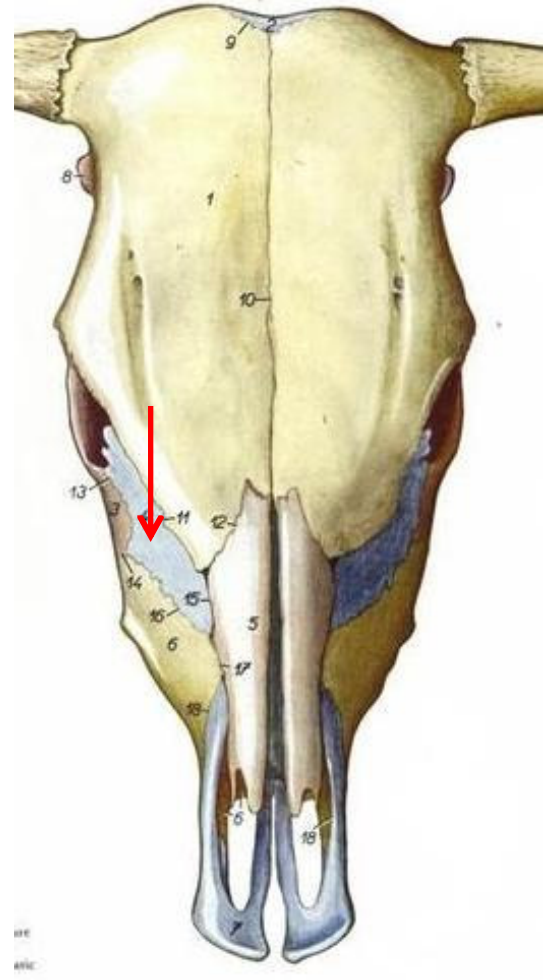


Lagrimal

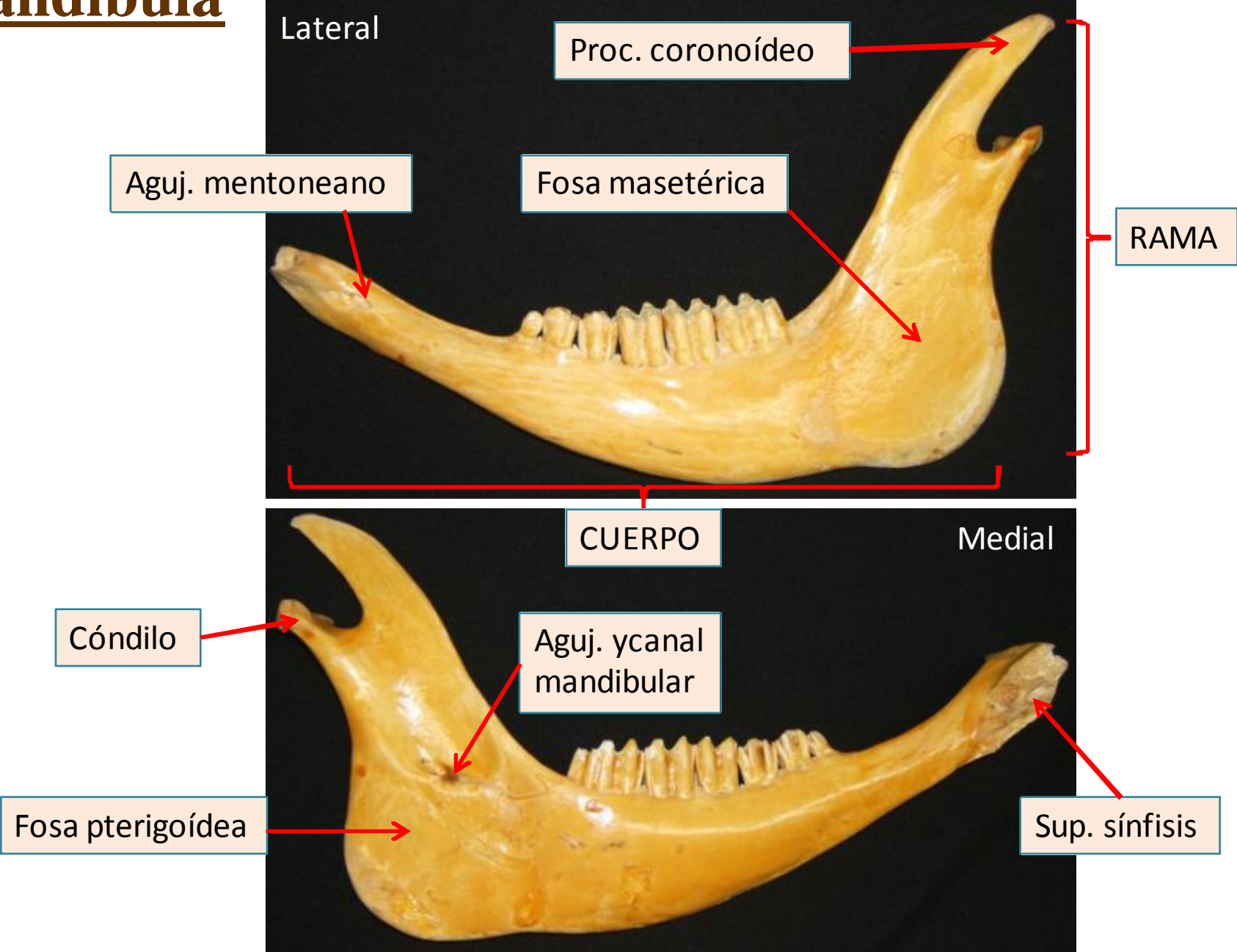
Fosa para sacco
lagrimal



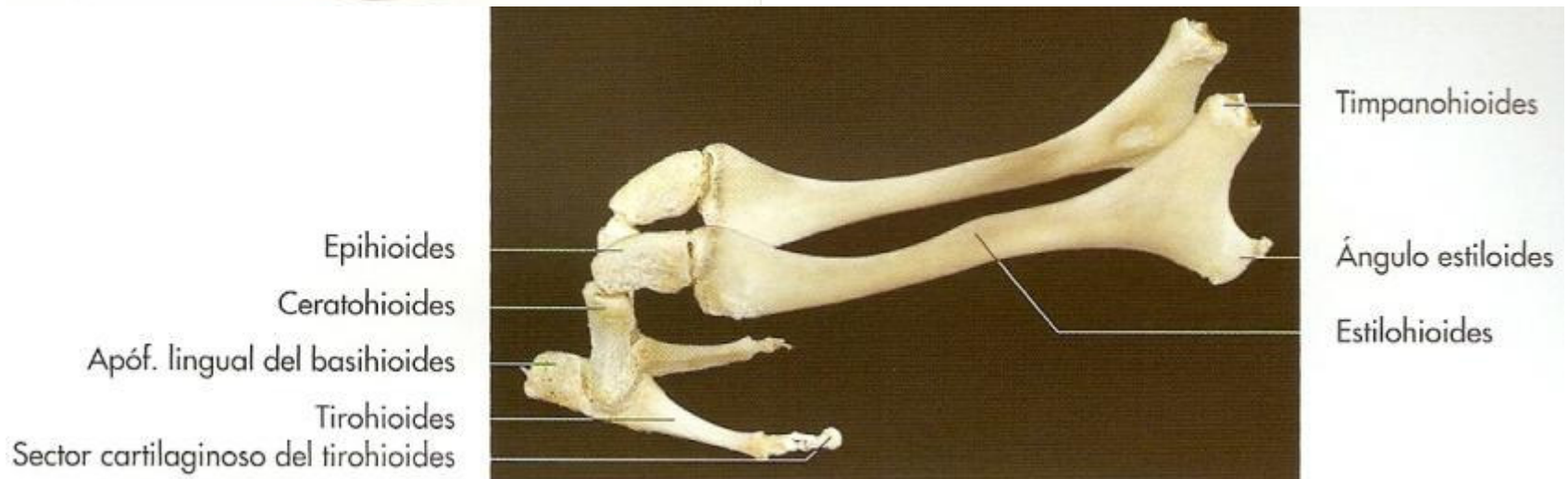
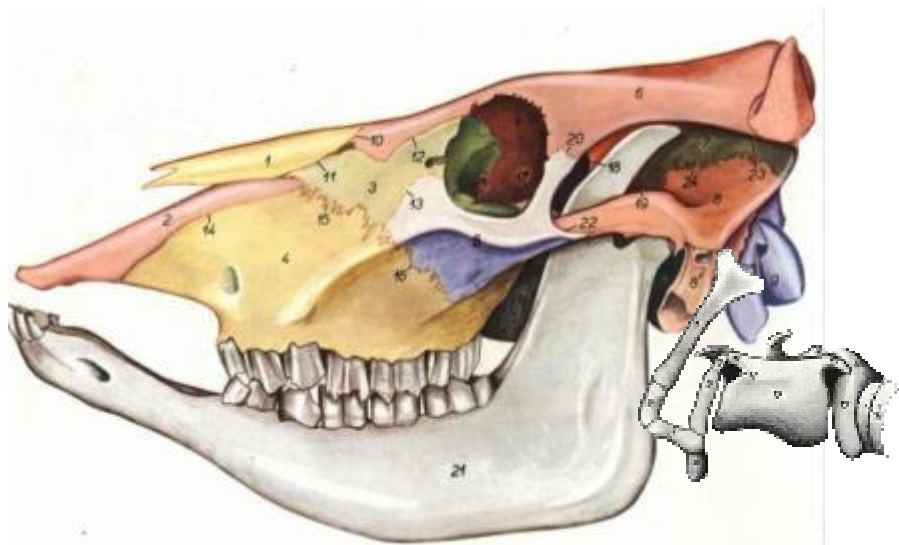Bulla lagrimal



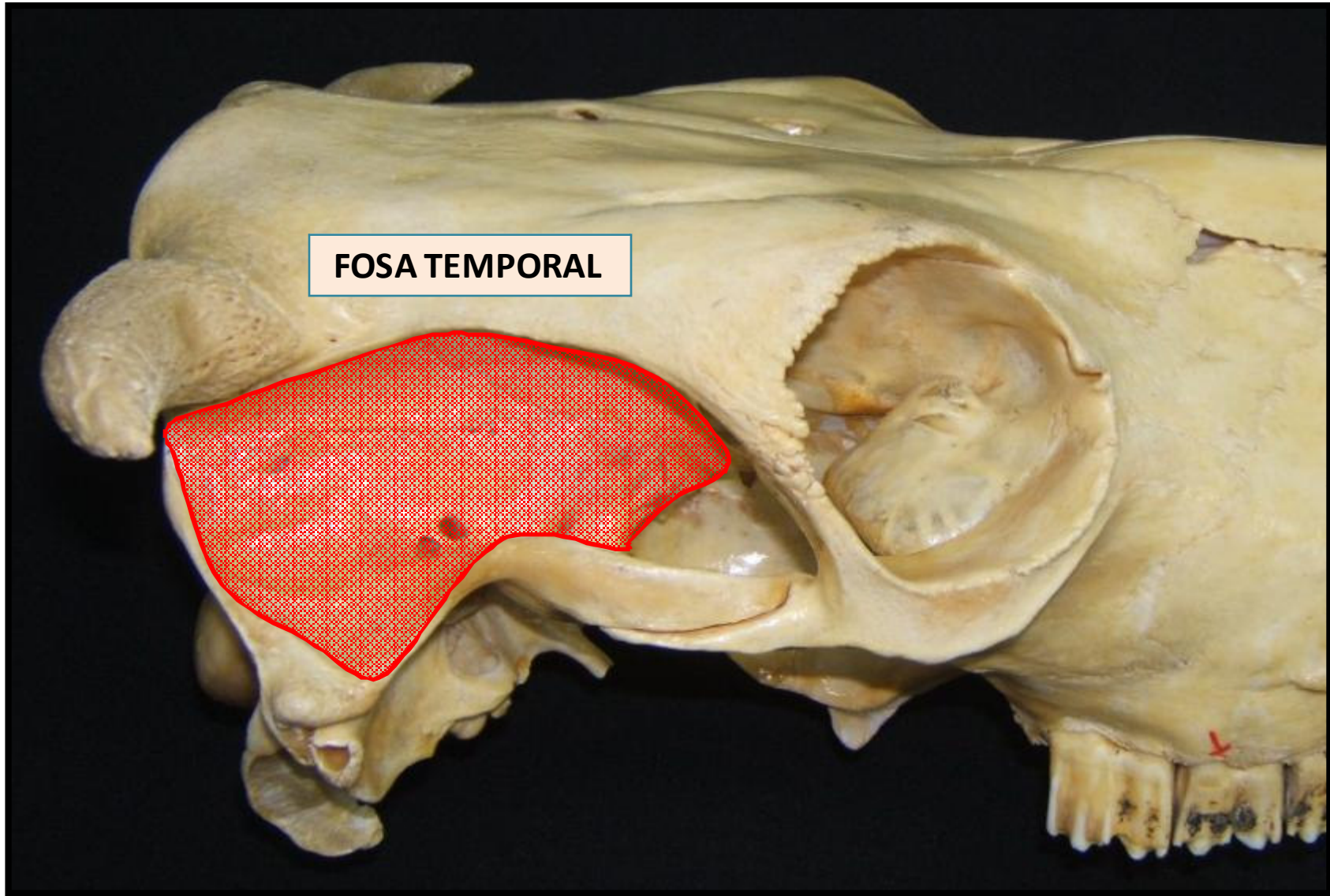
Mandíbula



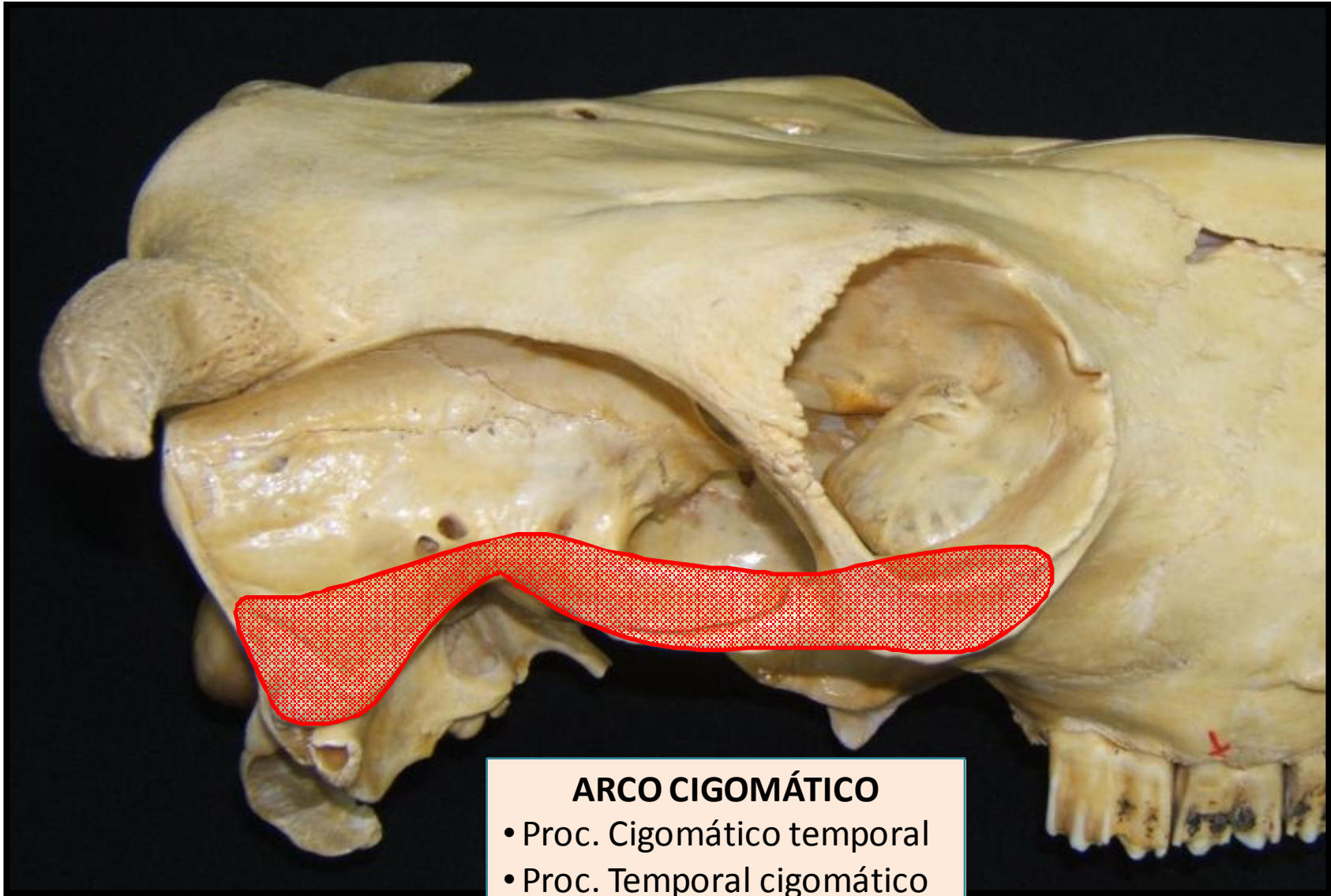
Hioides



Cráneo en conjunto



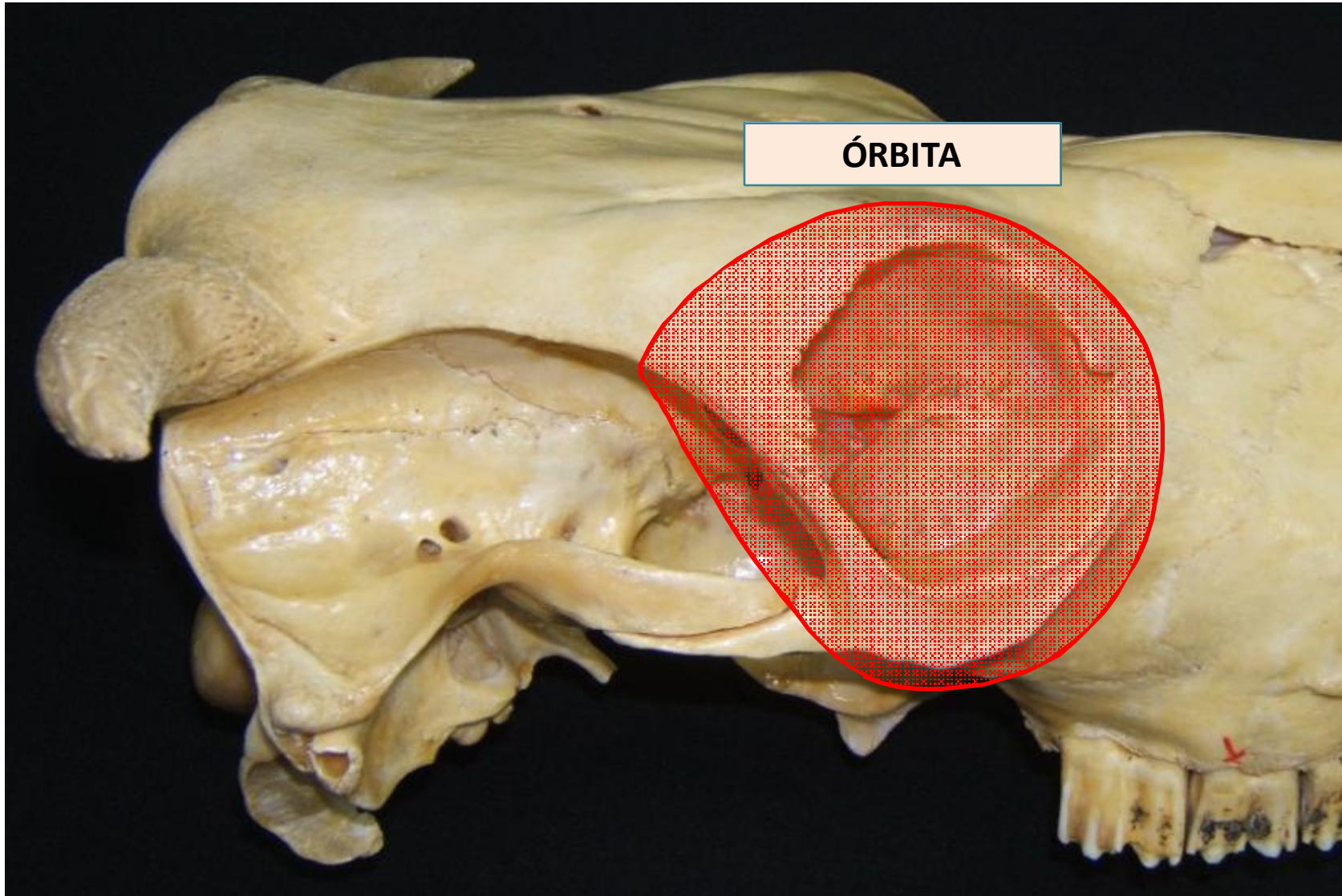
Cráneo en conjunto



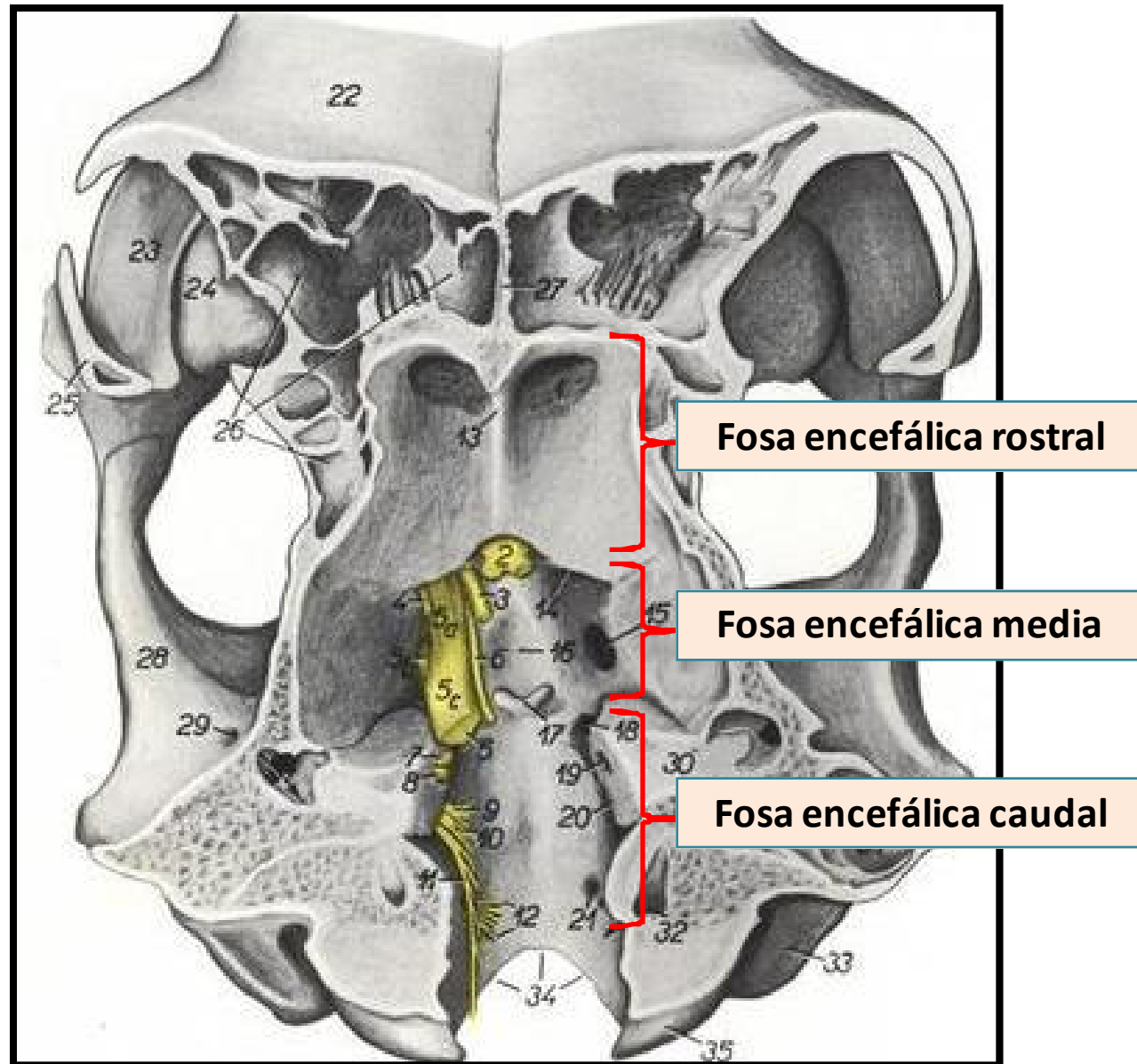
ARCO CIGOMÁTICO

- Proc. Cigomático temporal
- Proc. Temporal cigomático

Cráneo en conjunto



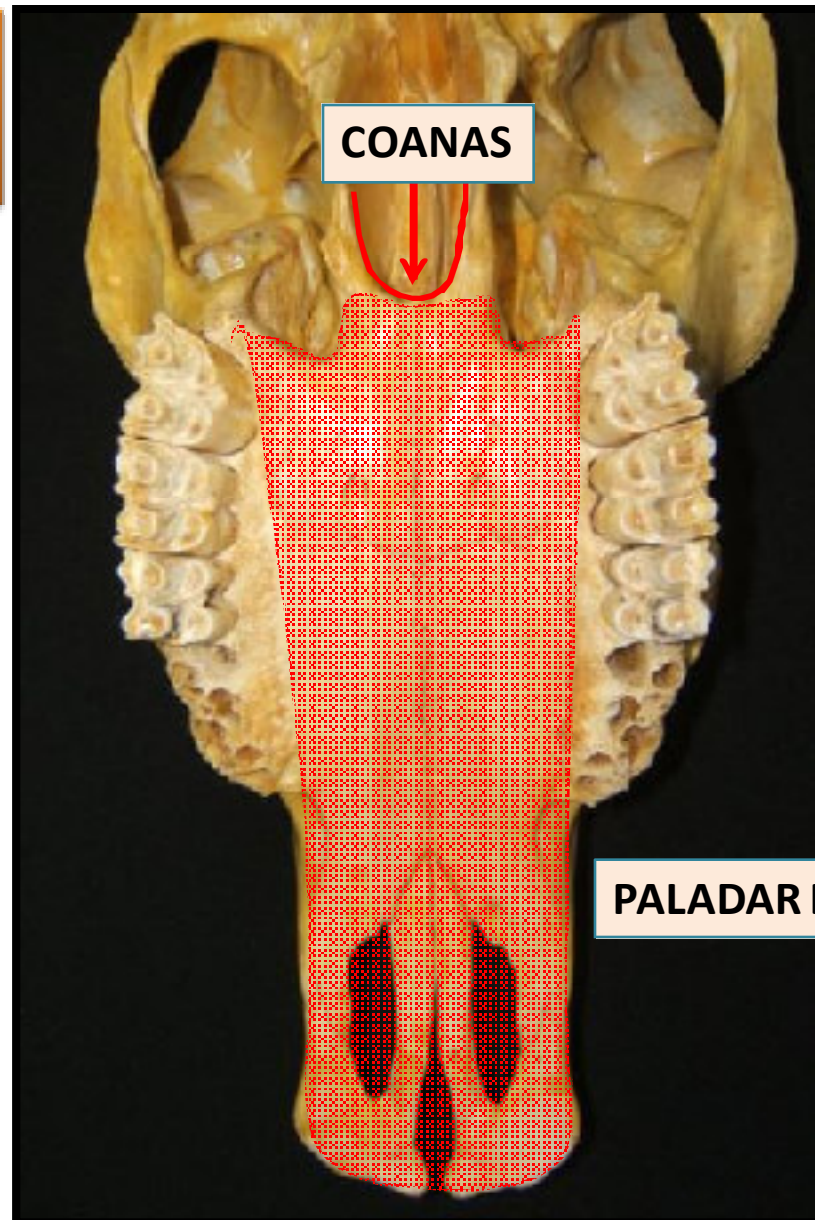
Cráneo en conjunto



Cráneo en conjunto

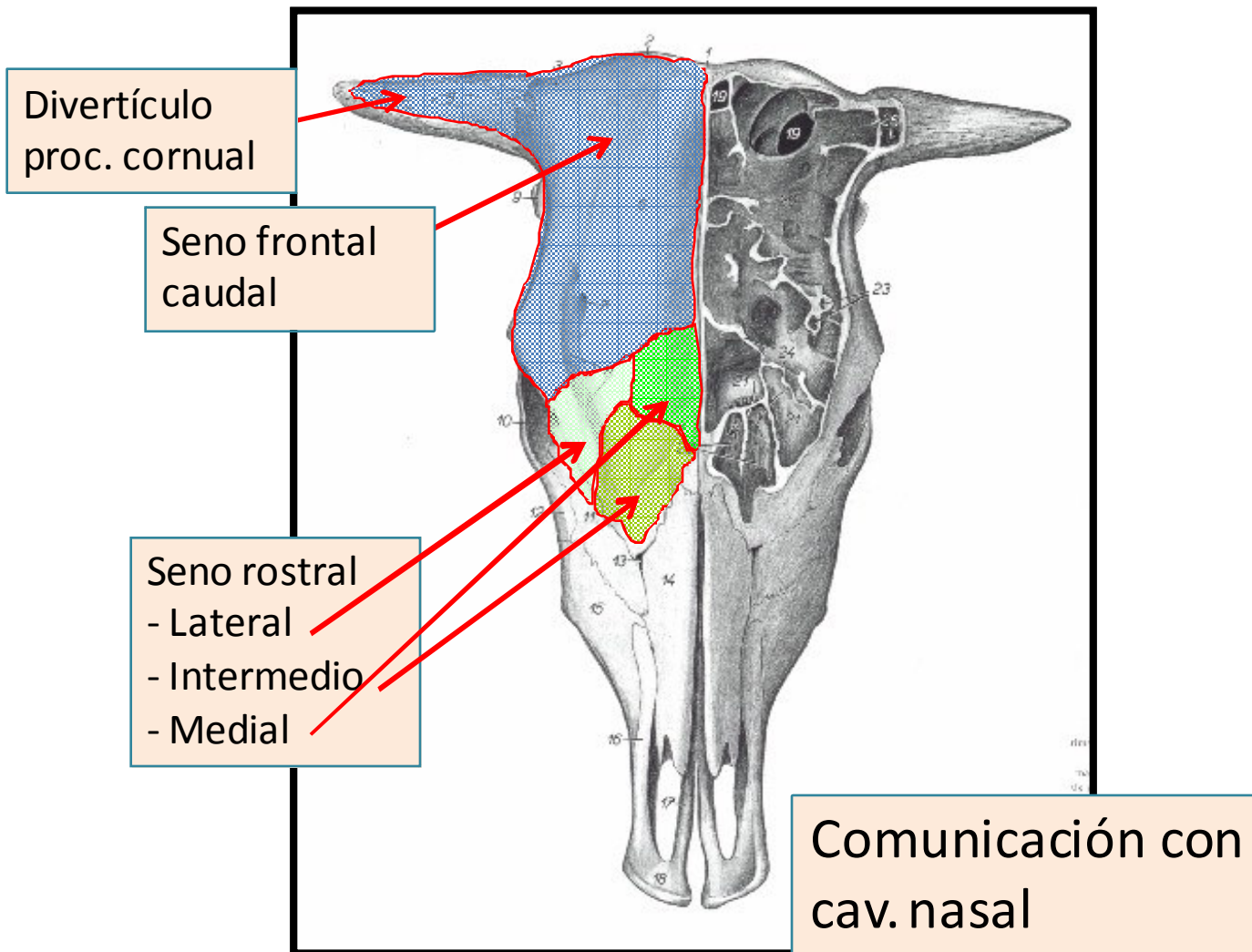
COANAS:

Comunican cavidad nasal con nasofaringe.

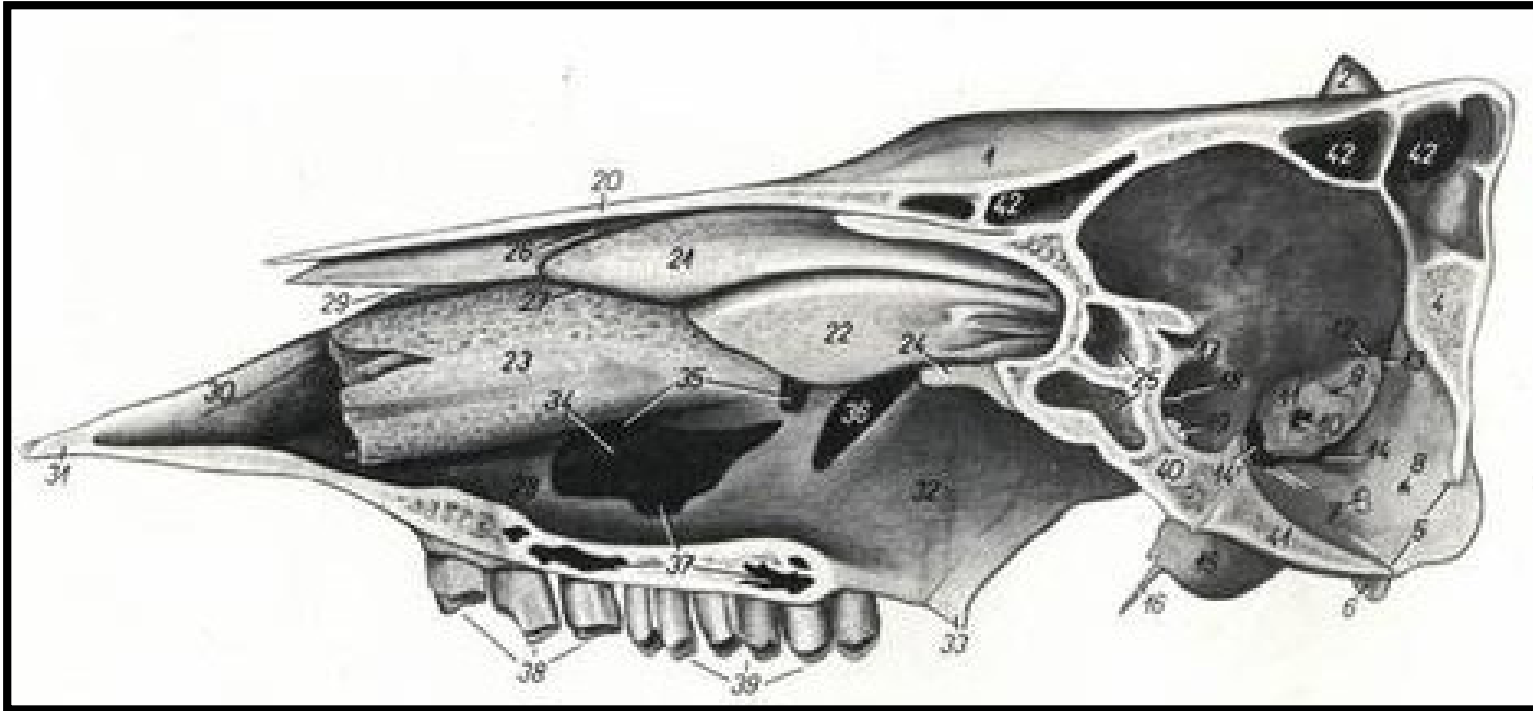


Senos paranasales

Seno Frontal

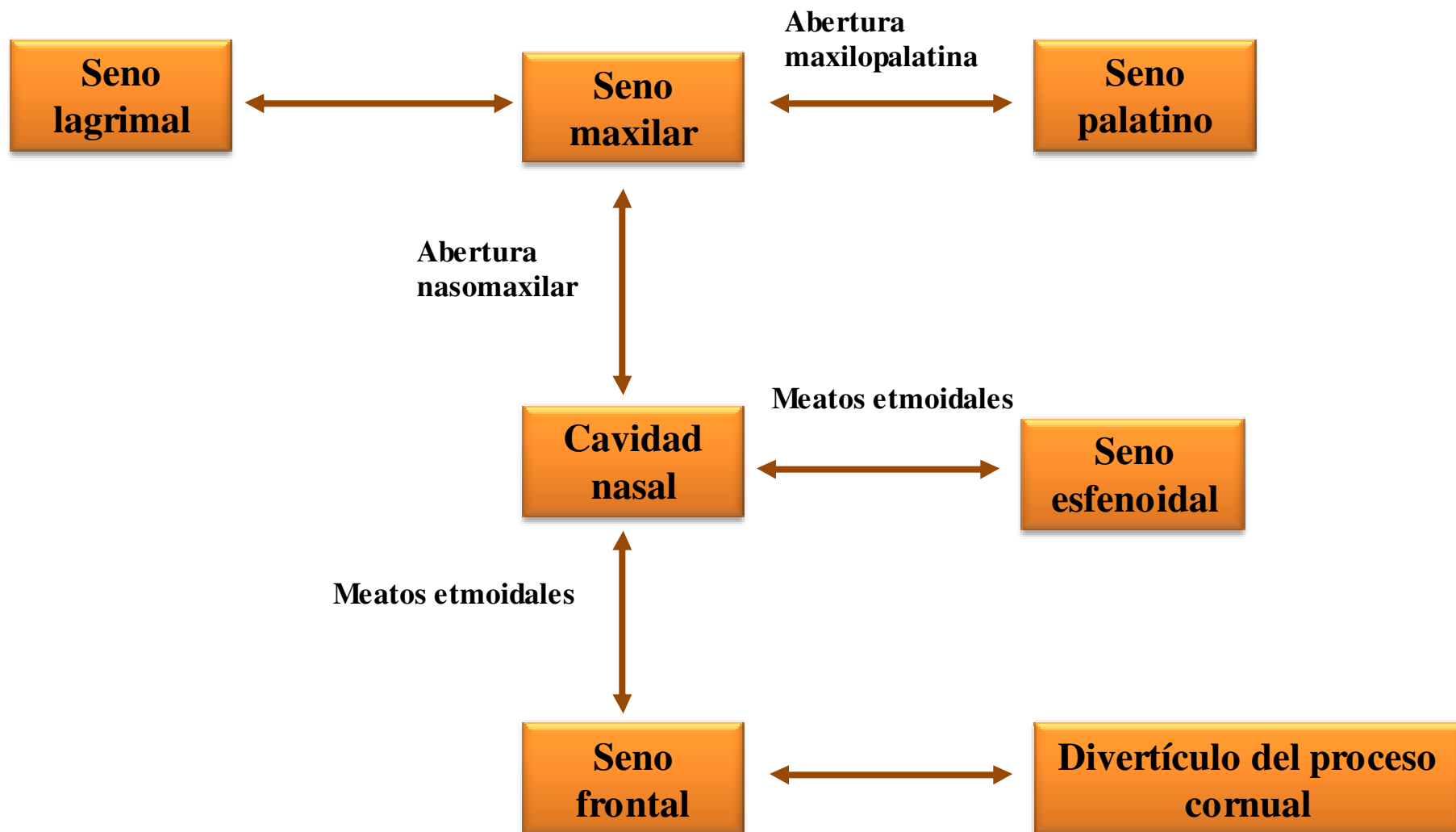


Seno Maxilar, Palatino y Esfenoidal

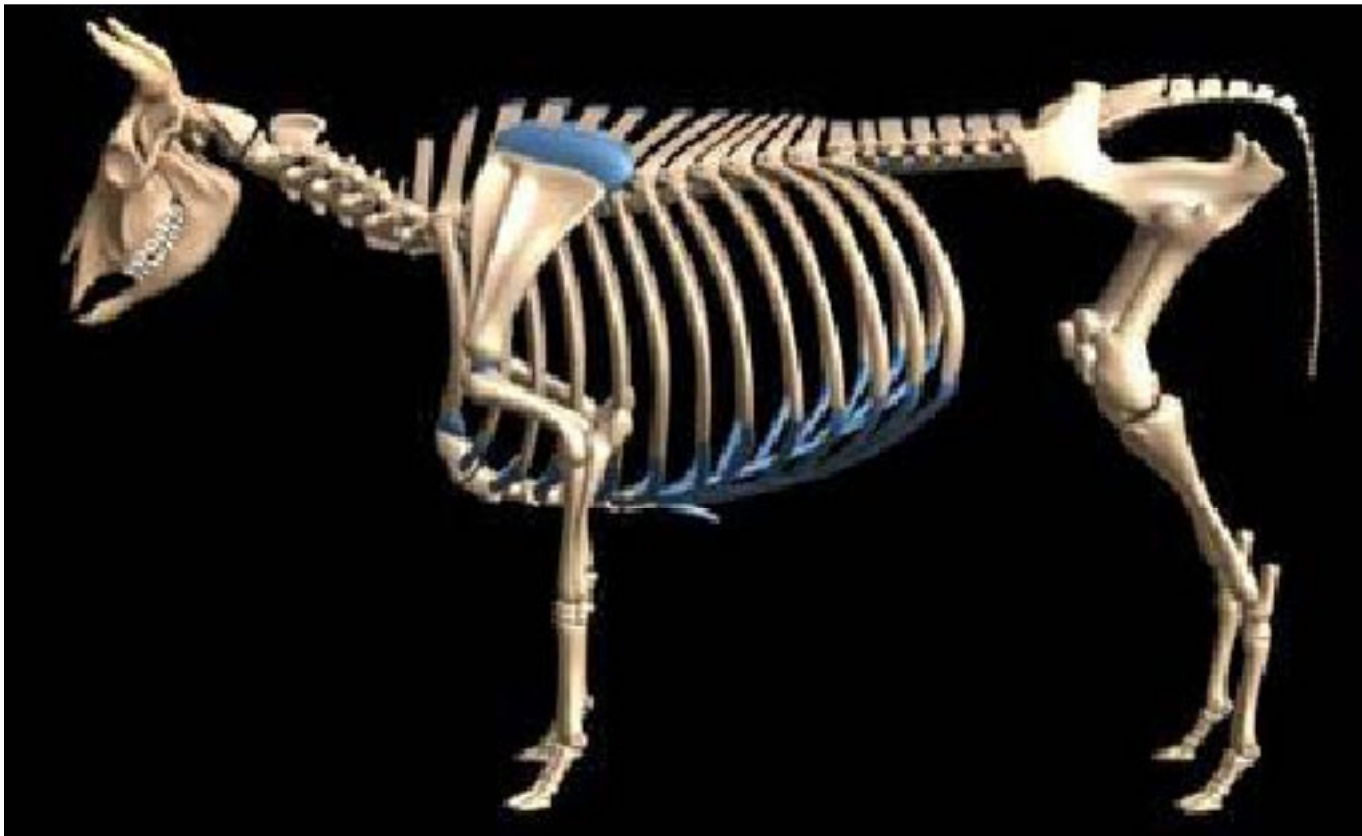


- **S. Maxilar (35):** En H. maxilar, lagrimal y cigomático. Comunica con cav. Nasal, s. palatino.
- **S. Palatino (37):** En paladar duro.
- **S. Esfenoidal (25):** En alas de preesfenoides. Comunica con cav. nasal.

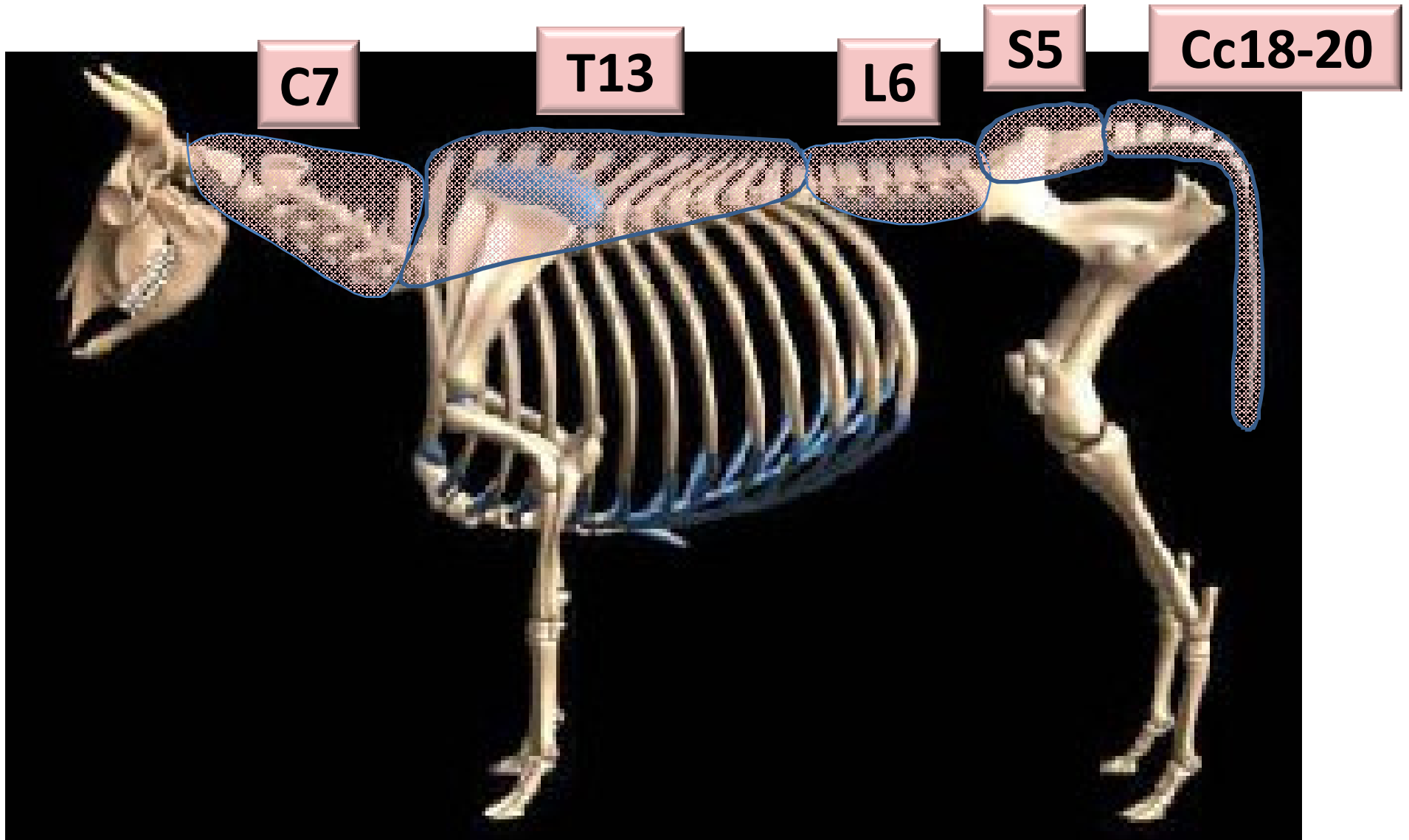
Senos paranasales



“OSTEOLOGÍA COLUMNA VERTEBRAL”

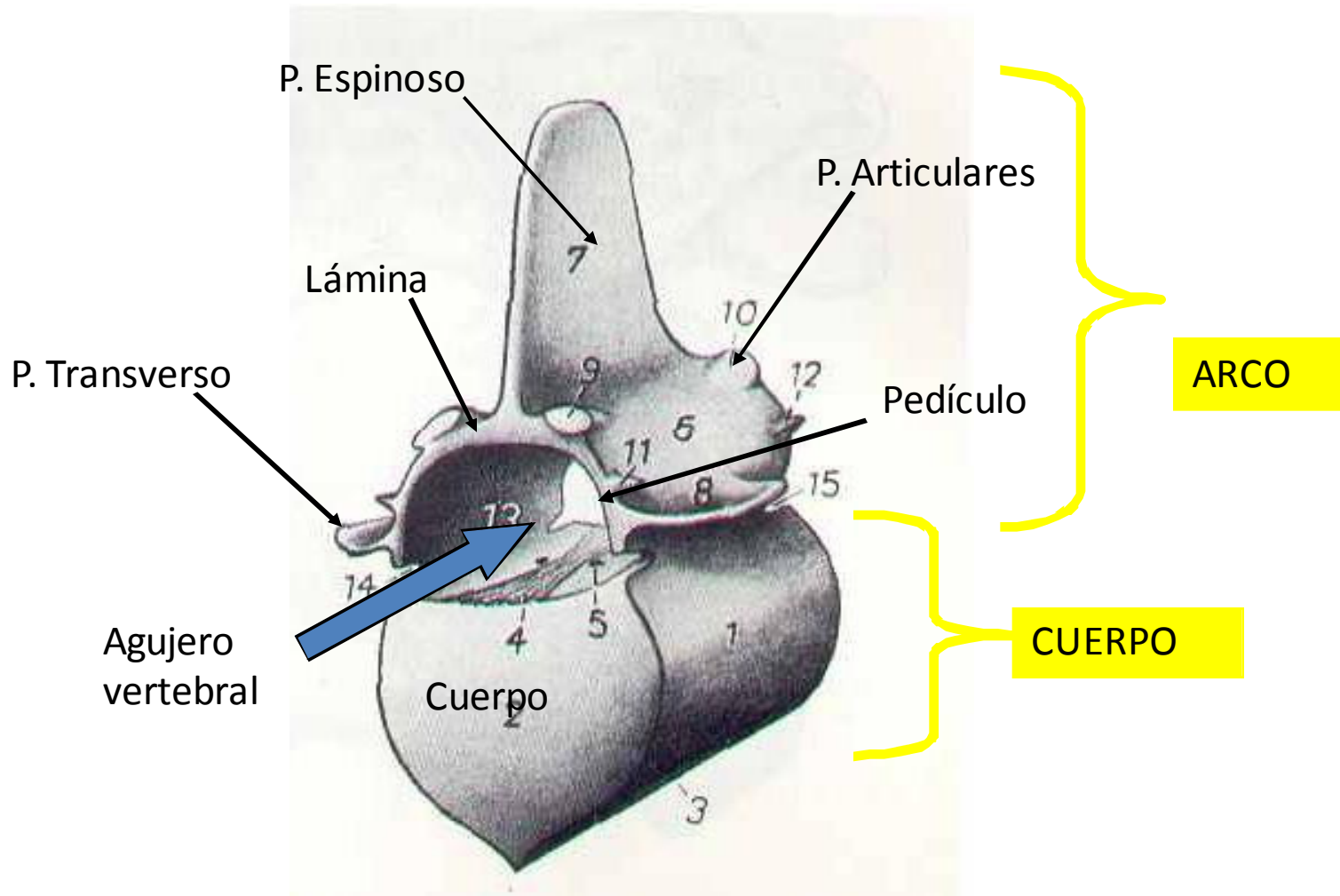


Fórmula vertebral



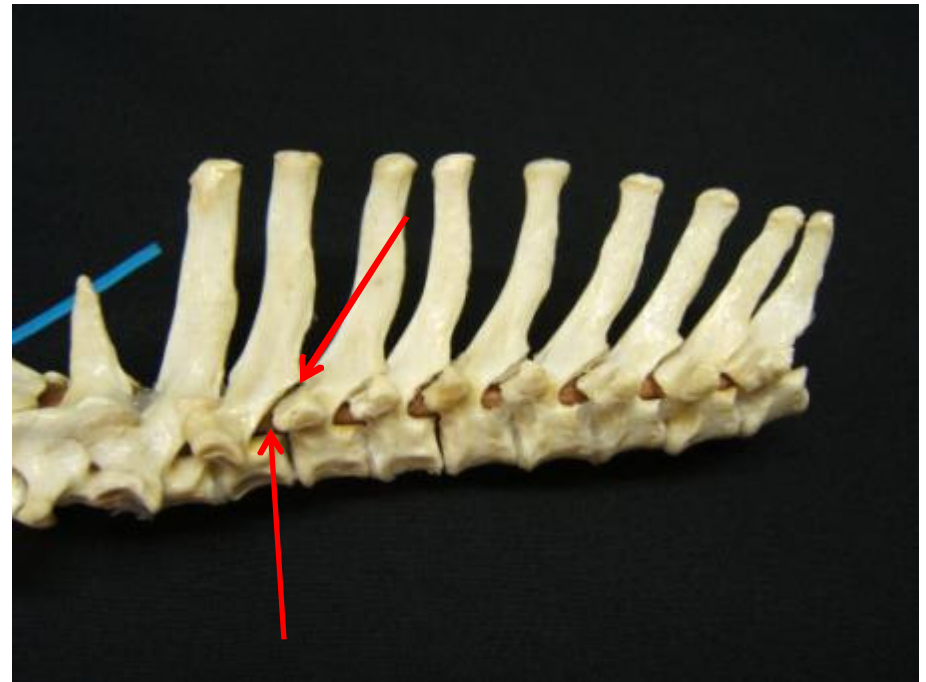
Osteología columna vertebral

Vértebra tipo

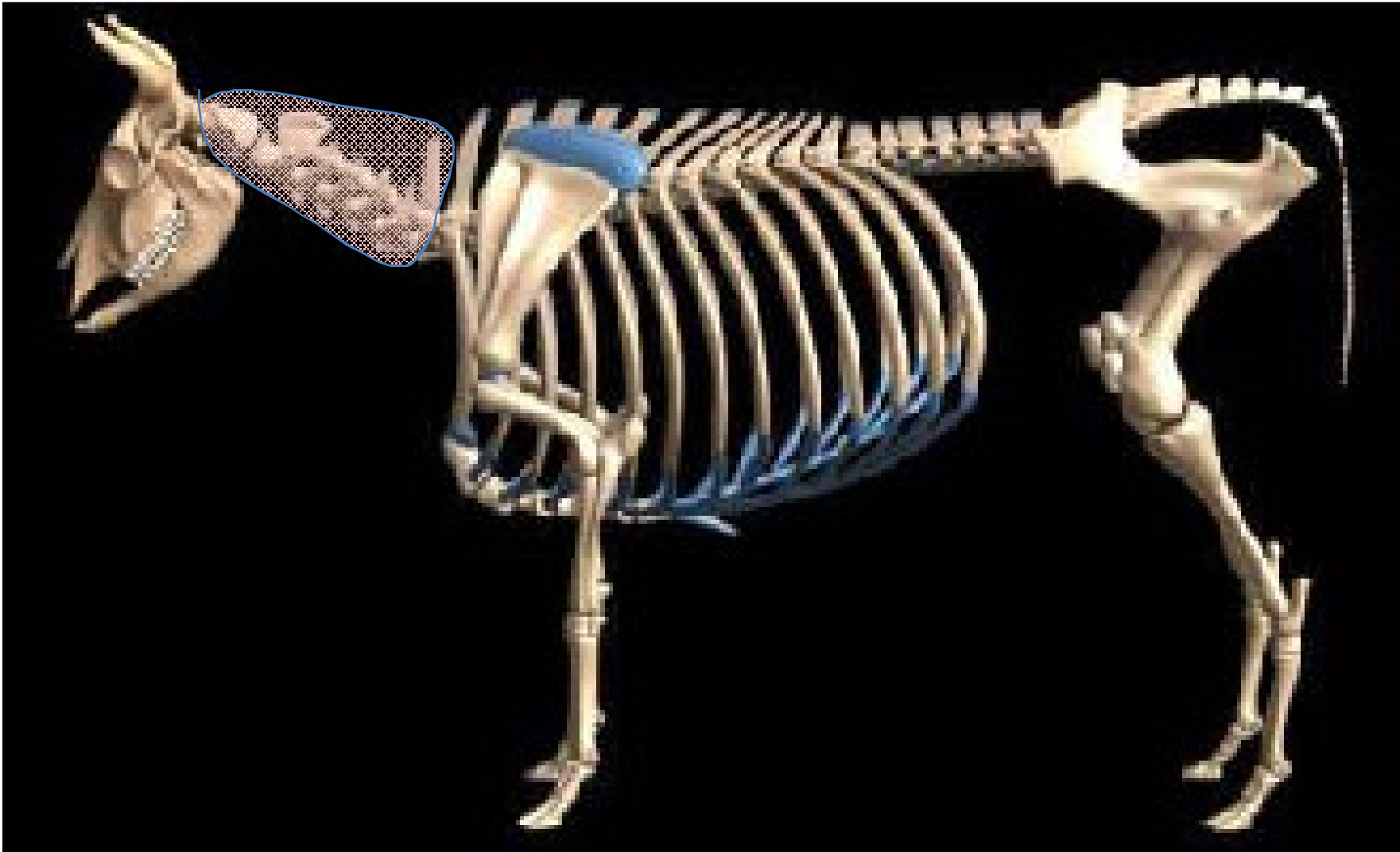

Osteología columna vertebral

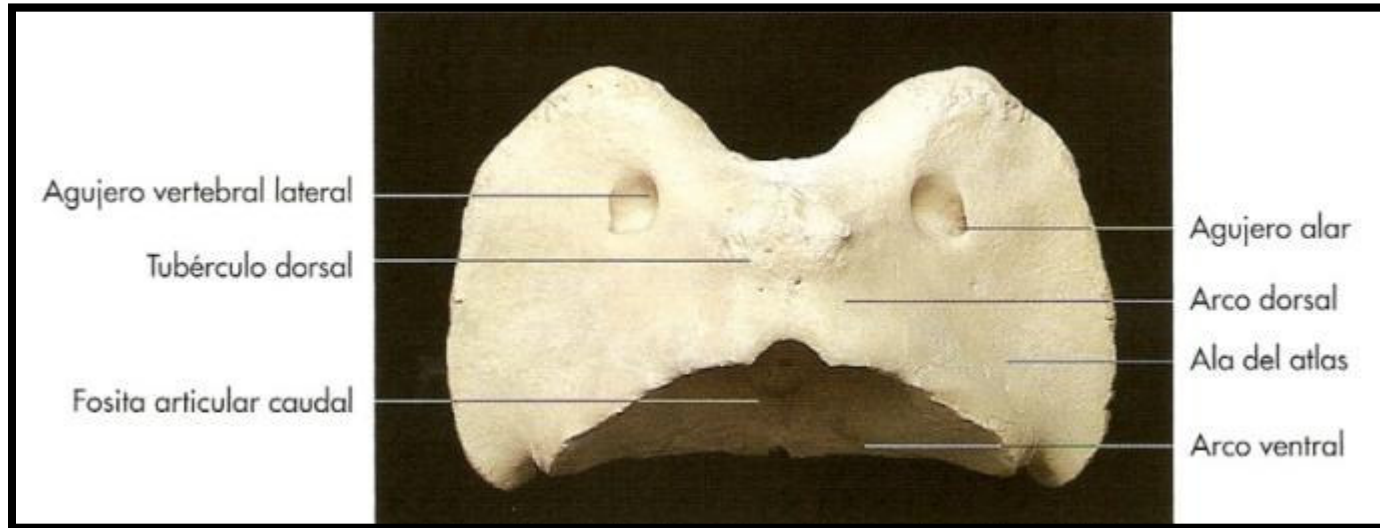
- **Agujero (foramen) intervertebral**
- **Agujero (foramen) interarcual**
- **Canal vertebral**



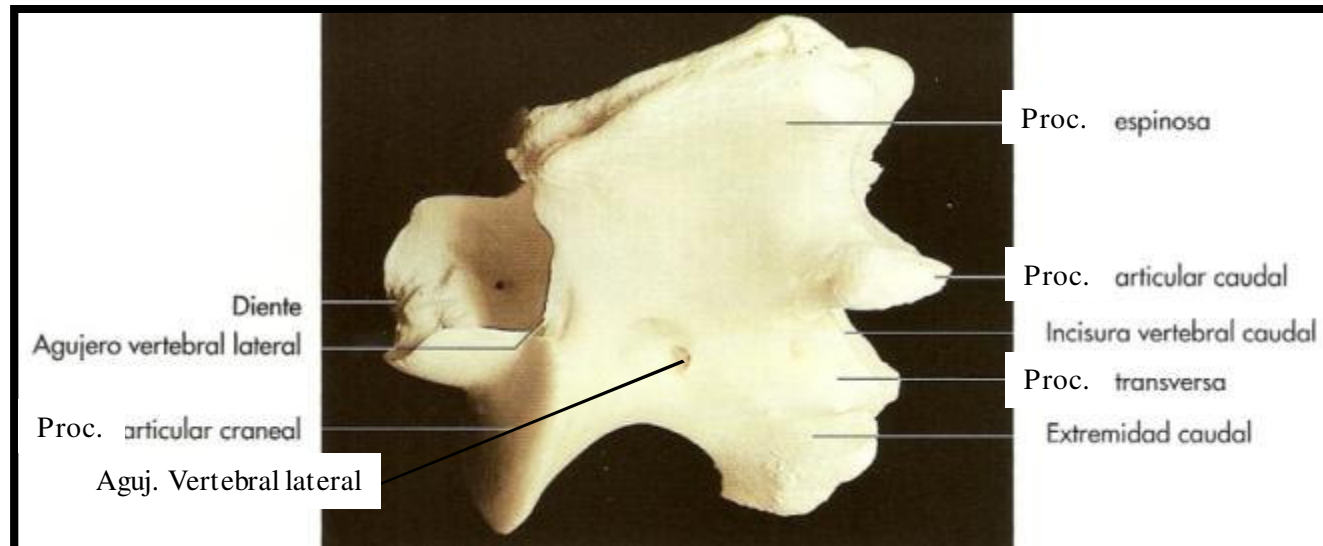
Segmento cervical



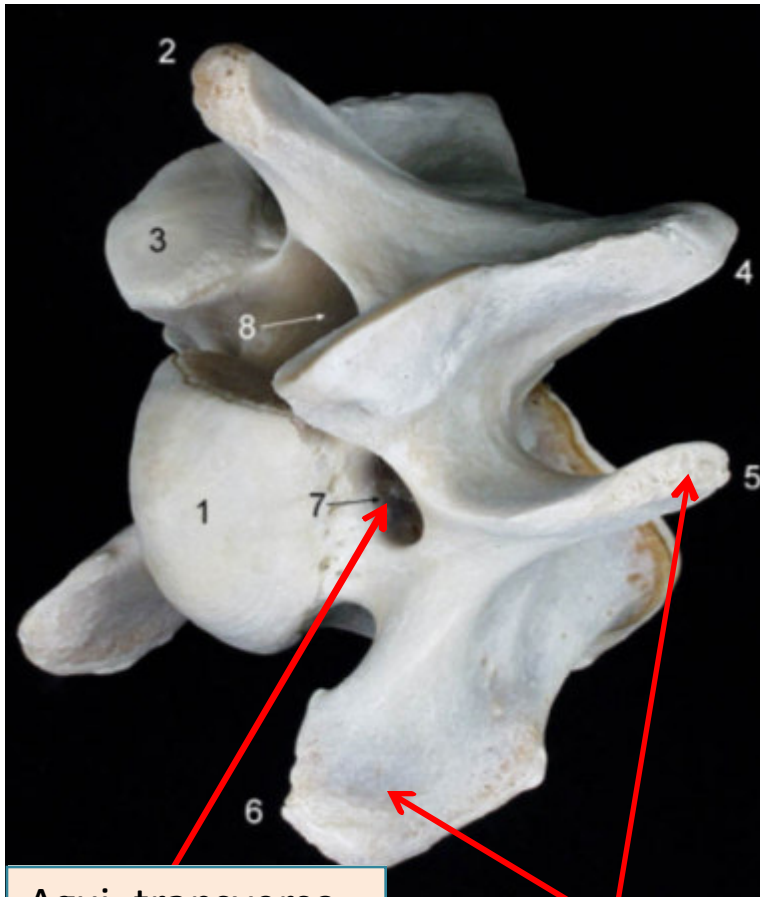
Atlas (C1)



Axis (C2)

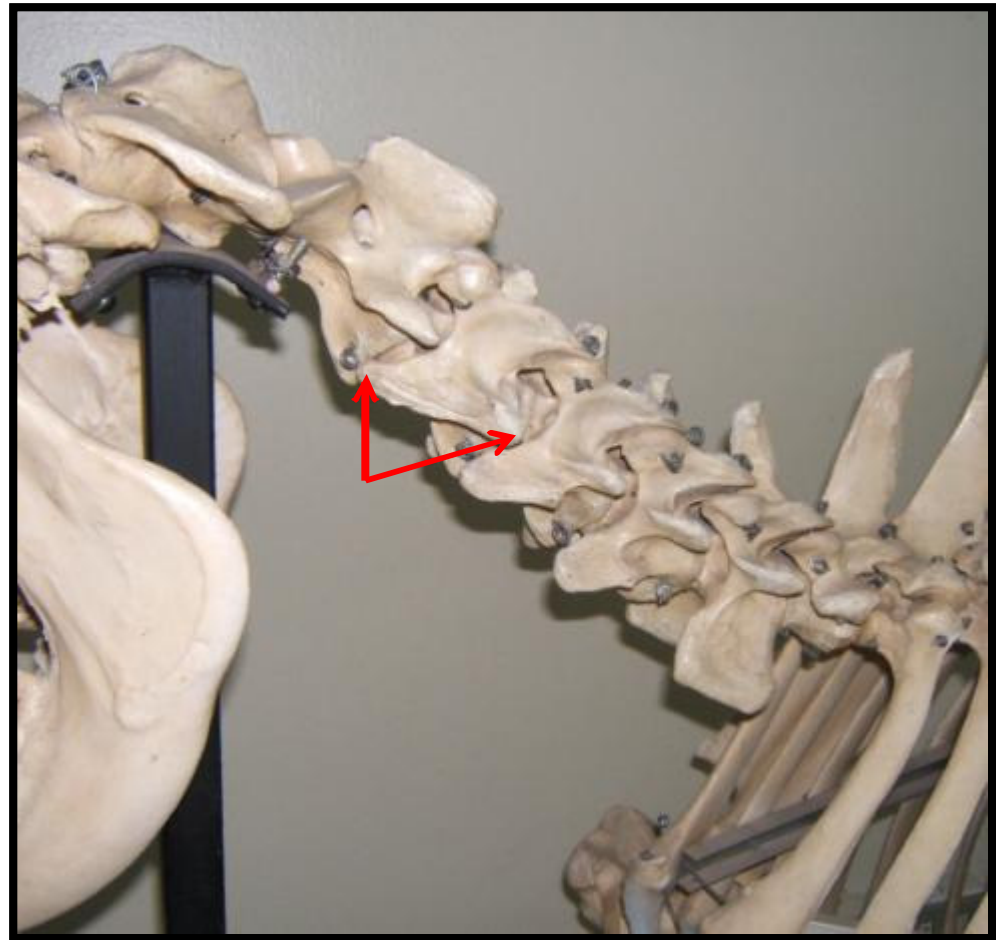


C3-4-5

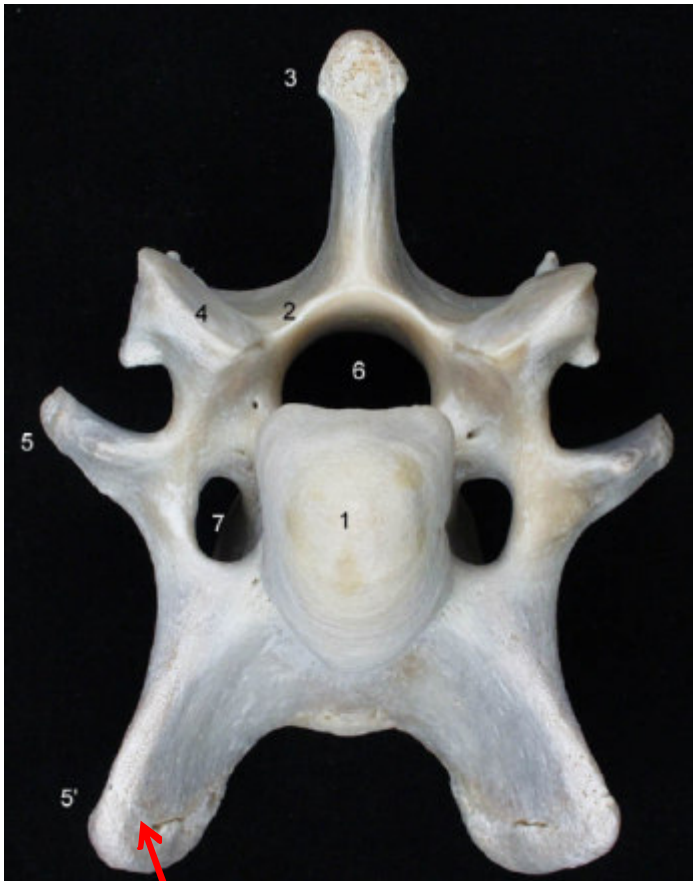

Aguj. transverso

Proc. transverso



C6



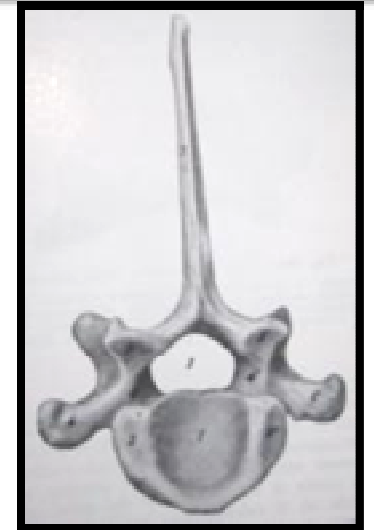Lamina ventral

C7

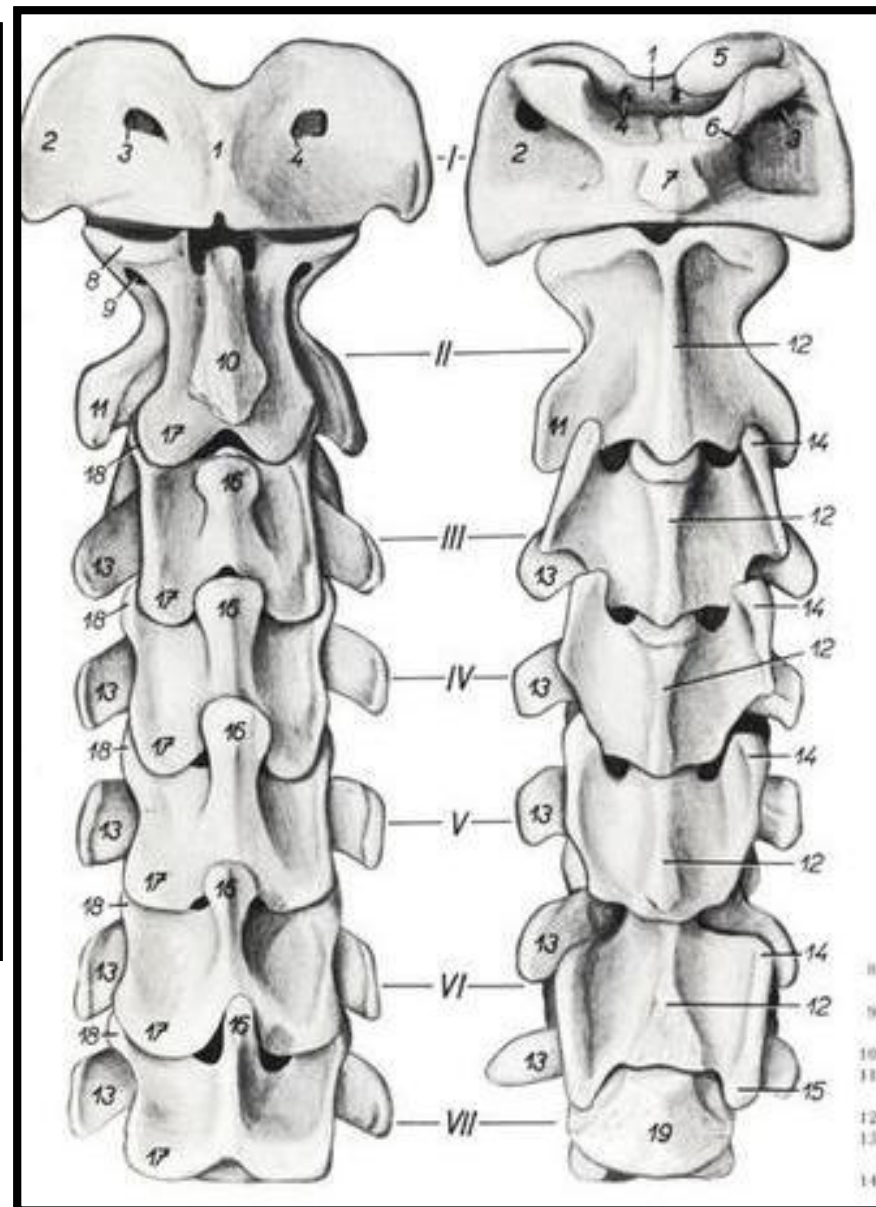
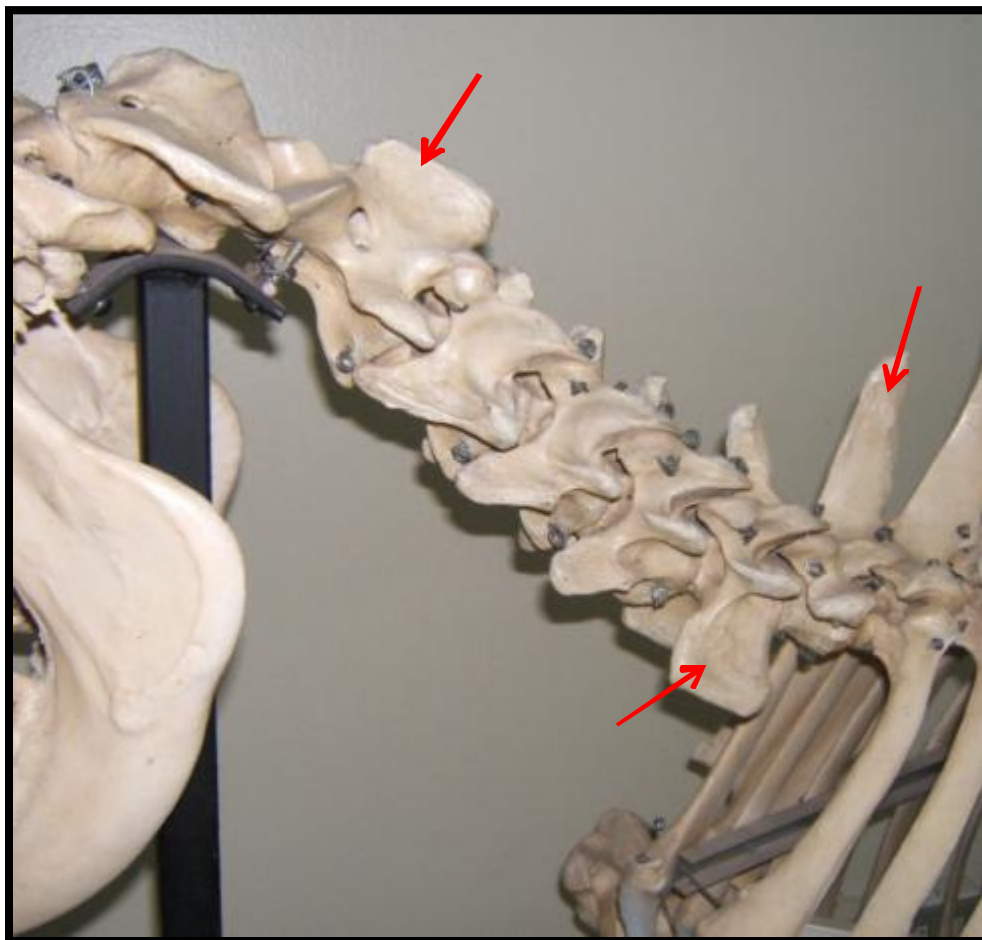


Fosita costal caudal

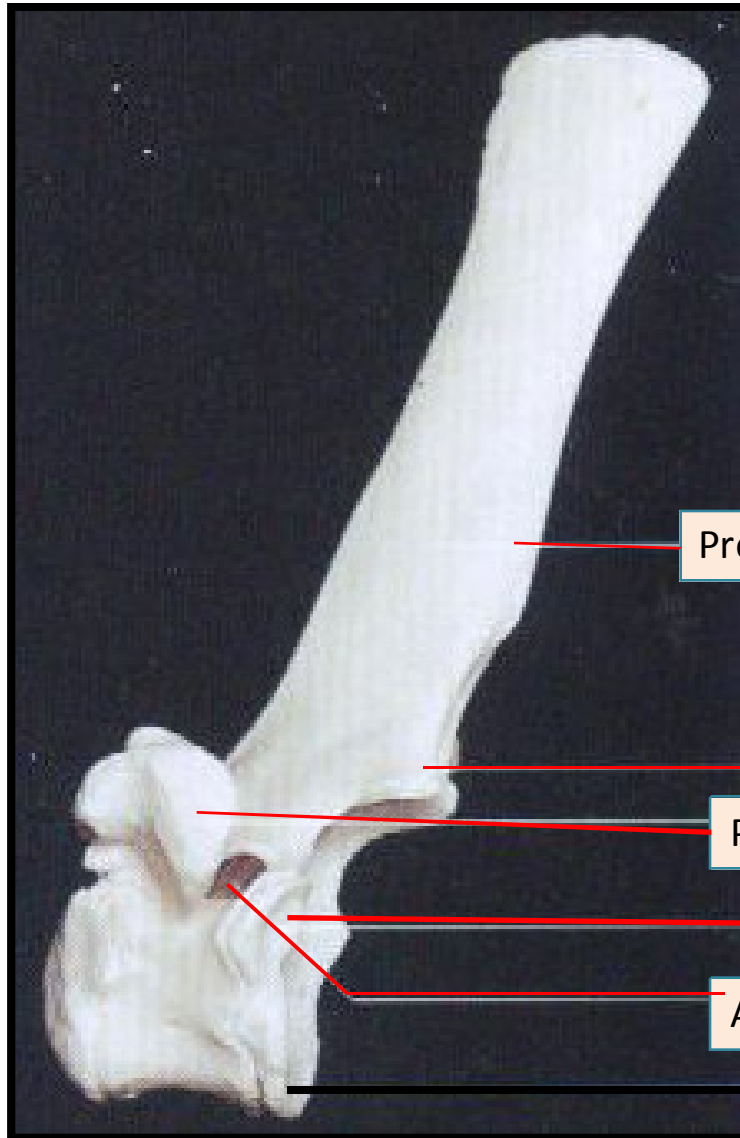
Proc. Transverso simple.
Ausencia aguj. Transverso.
Proc. Espinoso muy desarrollado.
Fosita costal caudal.



Segmento cervical



Segmento torácico



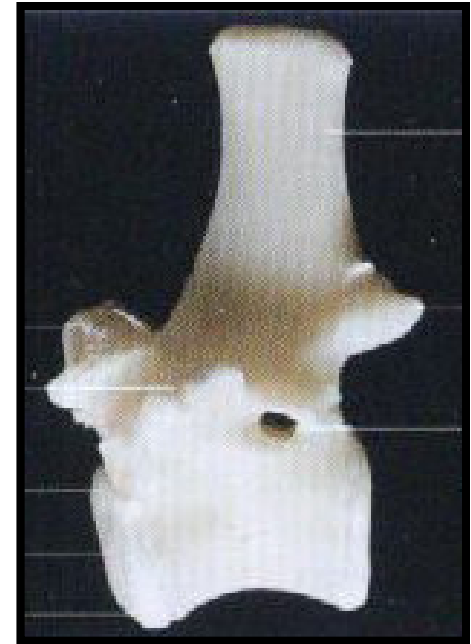
Proc. espinoso

Proc. Articular caudal

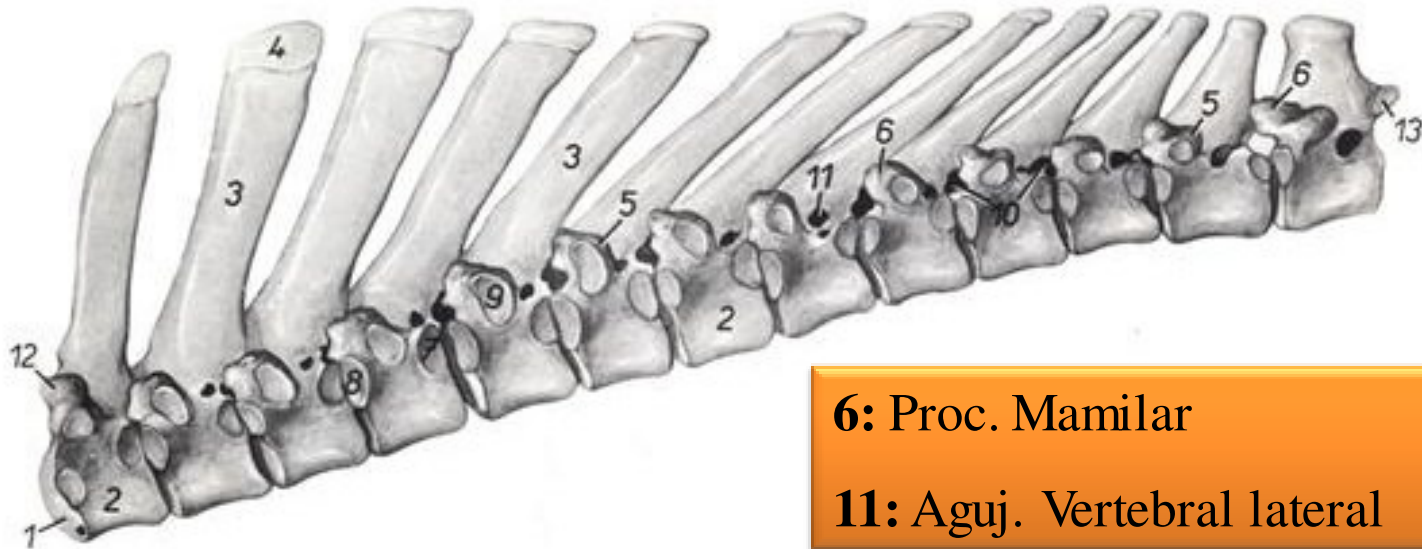
Proc. transverso

Fosita costal caudal

Aguj. Vertebral lateral

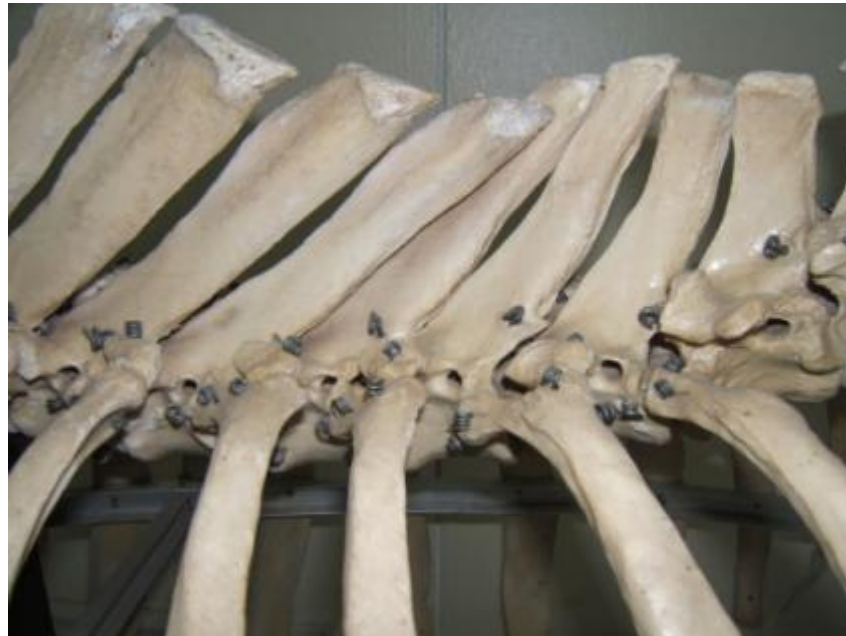

Segmento torácico

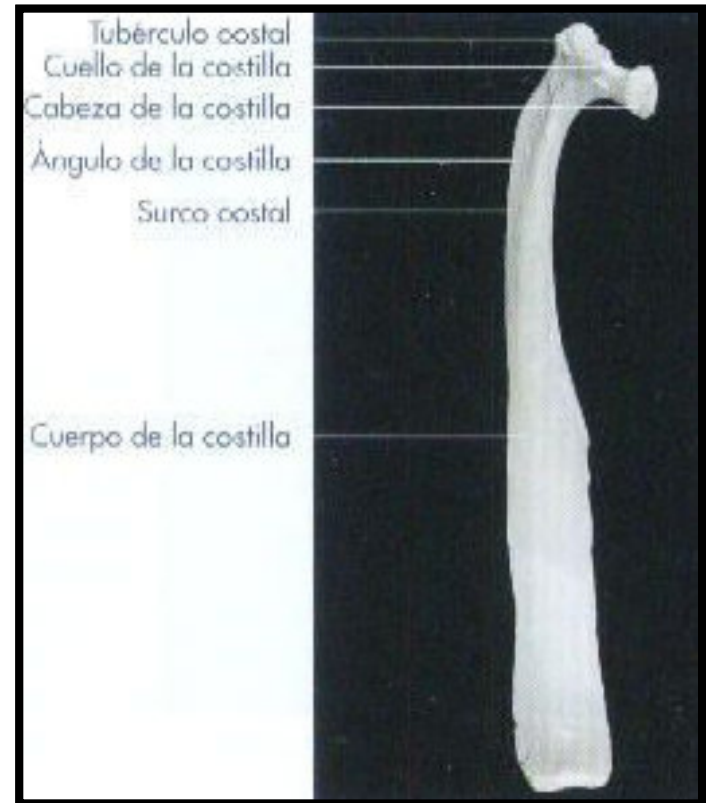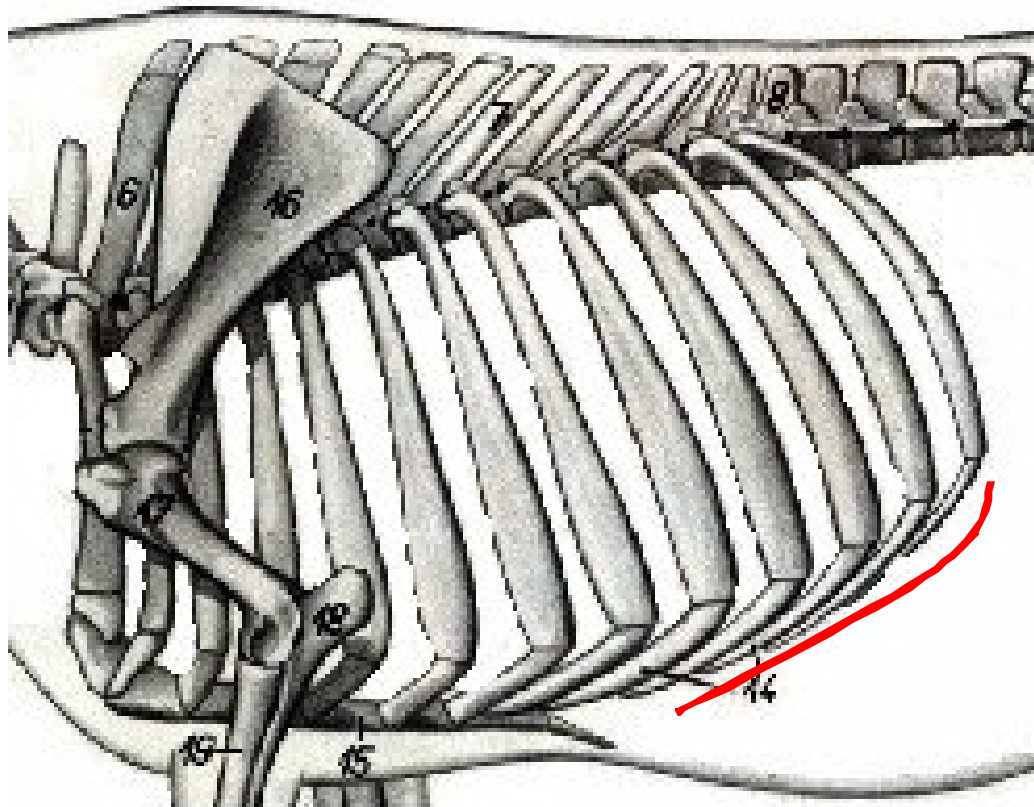


6: Proc. Mamilar

11: Aguj. Vertebral lateral



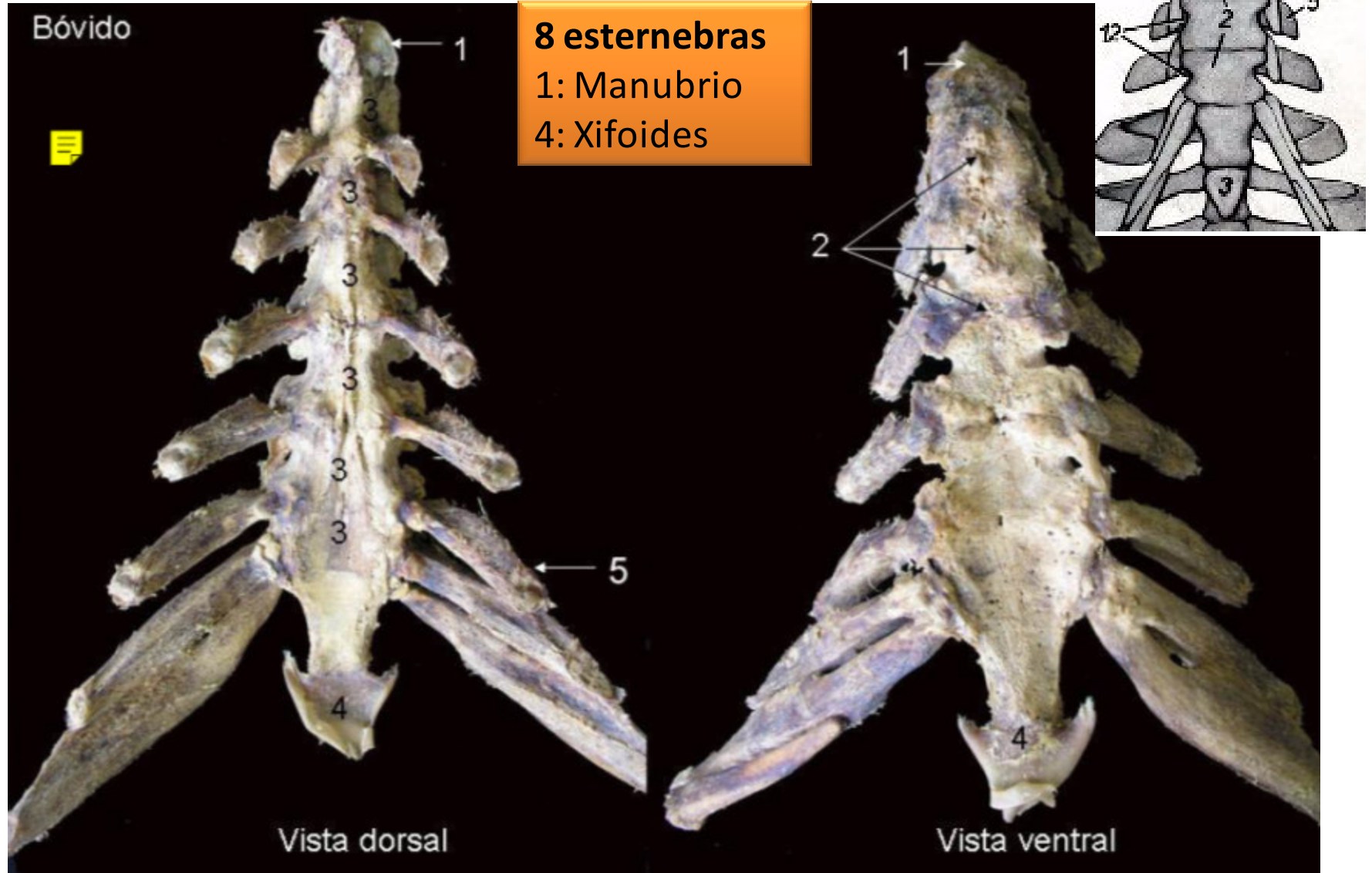
Tórax



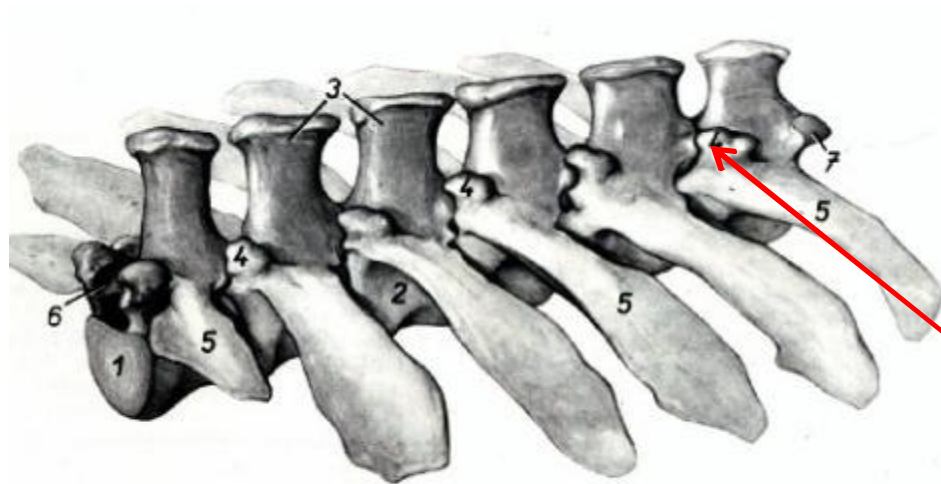
8 pares de costillas esternales.

5 pares de costillas asternales (falsas). Arco costal.

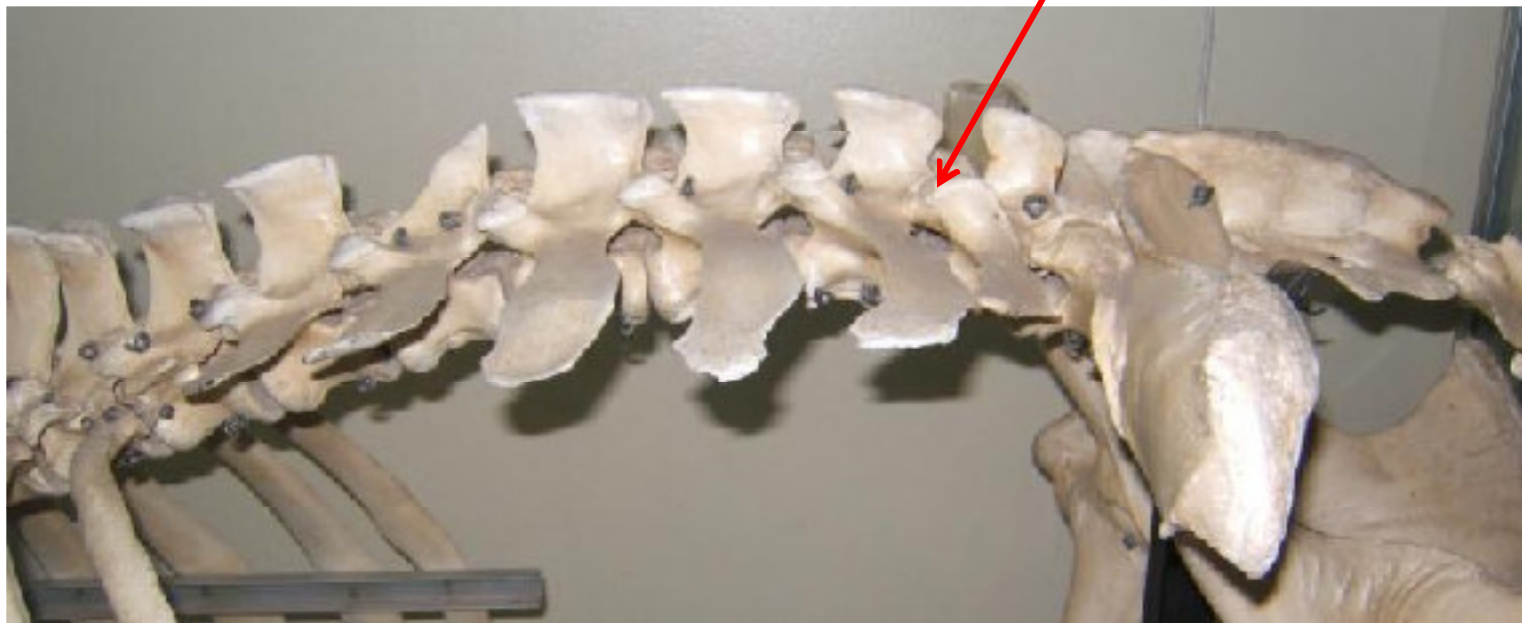
Tórax: Esternón



Segmento lumbar



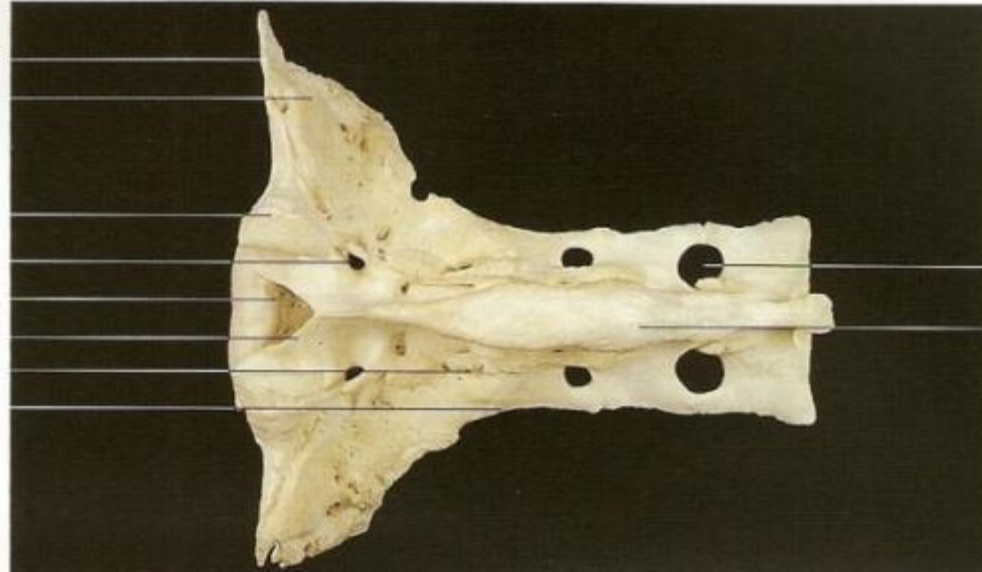
Proc. mamilar



Segmento sacro

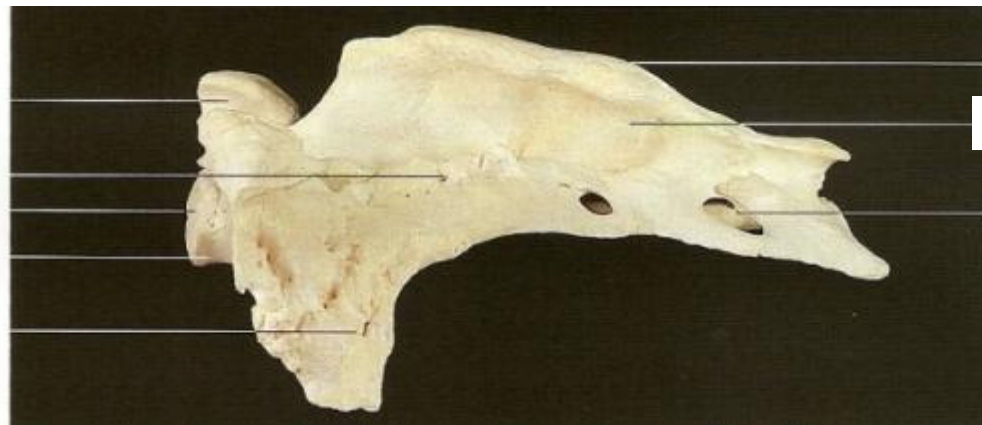Cara articular
Ala del sacro con cara auricular

Proc. articular craneal
Agujero sacro dorsal
Agujero vertebral
Arco vertebral
Cresta sacra intermedia
Cresta sacra lateral



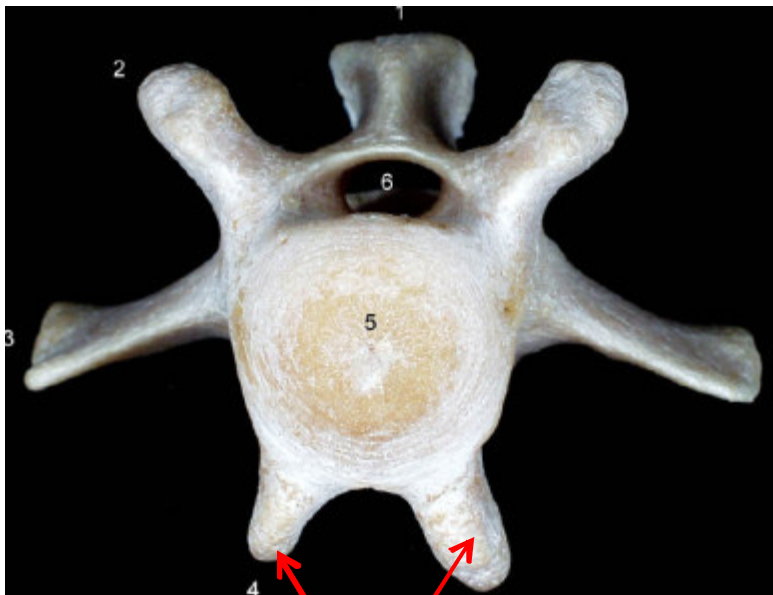
Agujero sacro dorsal
Cresta sacra mediana

Proc. articular craneal
Cresta sacra intermedia
Extremidad craneal
Promontorio
Ala del sacro con cara auricular

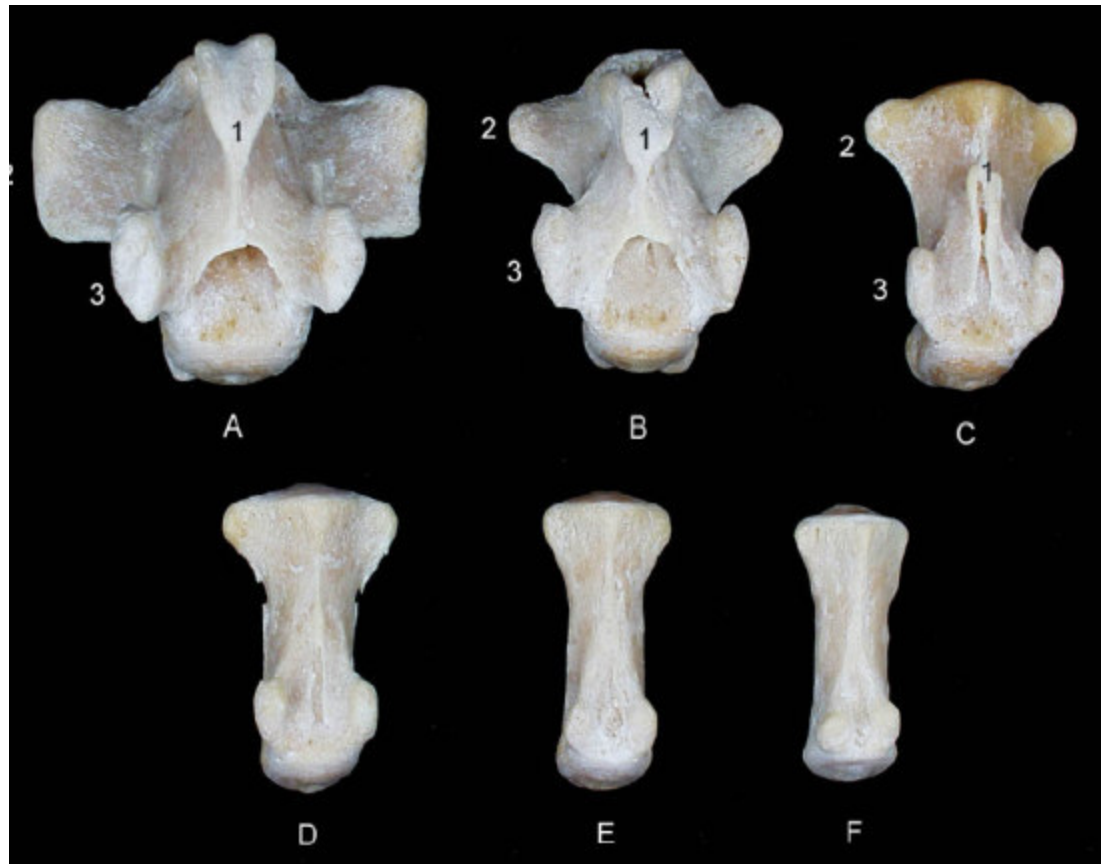


Cresta sacra mediana
Proc. espinosa
Agujero sacro dorsal

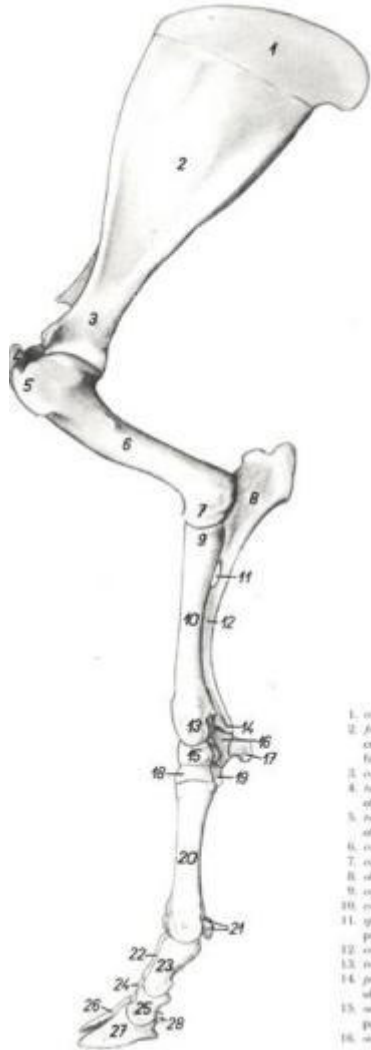
Segmento coccígeo



Proc. hemales



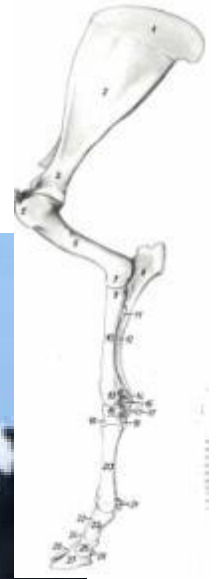
“Osteología mb. Torácico”



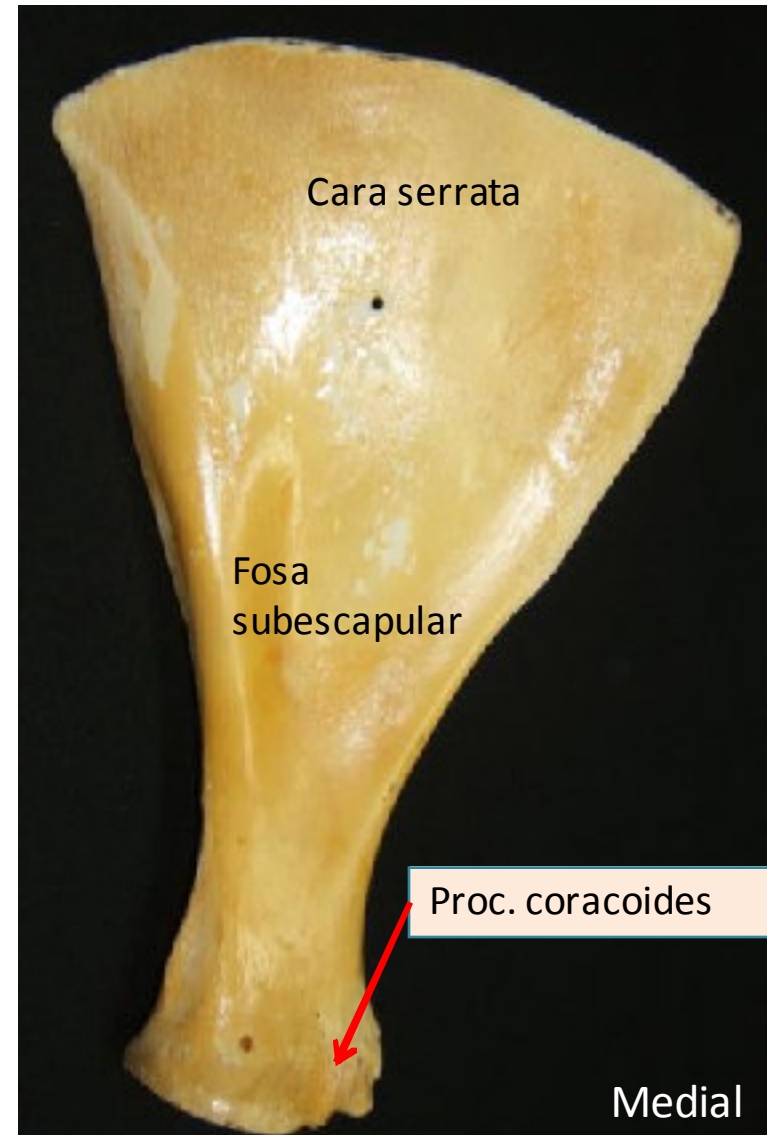
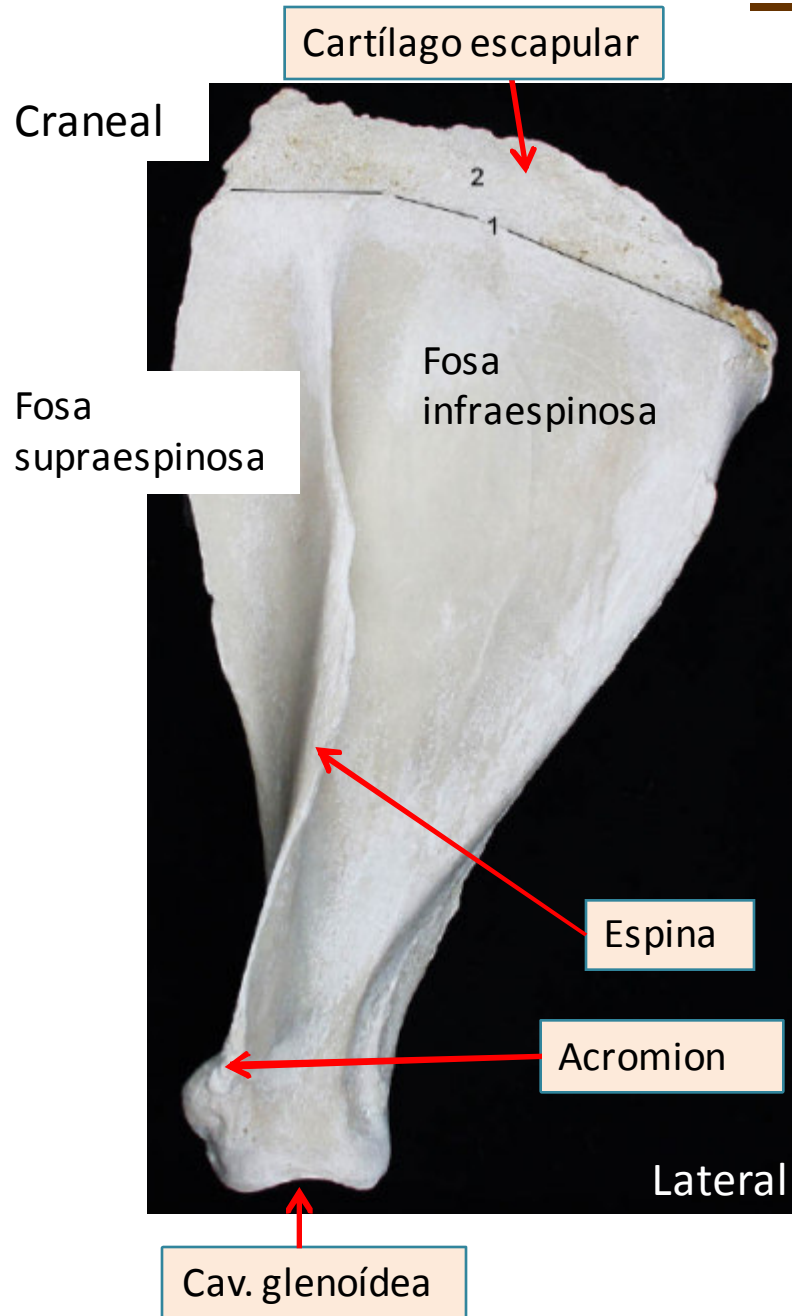
- 1. caput
- 2. brachio
- 3. fossa
- 4. collum
- 5. tuberculum
- 6. corpus
- 7. caput
- 8. olecranon
- 9. corpus
- 10. corpus
- 11. spina
- 12. corpus
- 13. caput
- 14. processus
- 15. caput
- 16. processus
- 17. ...
- 18. ...

Topografía

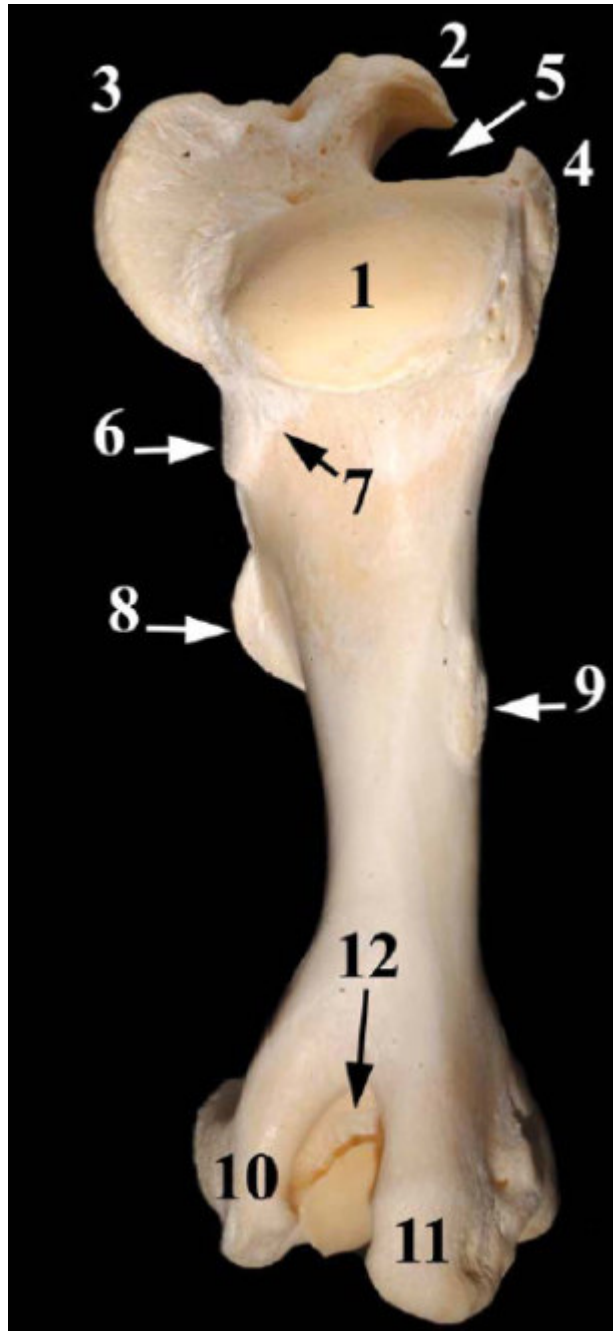
- Escapular
- Hombro
- Braquial
- Codo
- Antebraquial
- Carpo
- Metacarpo
- Art. Mtc-Fg
- Dedos



Escápula



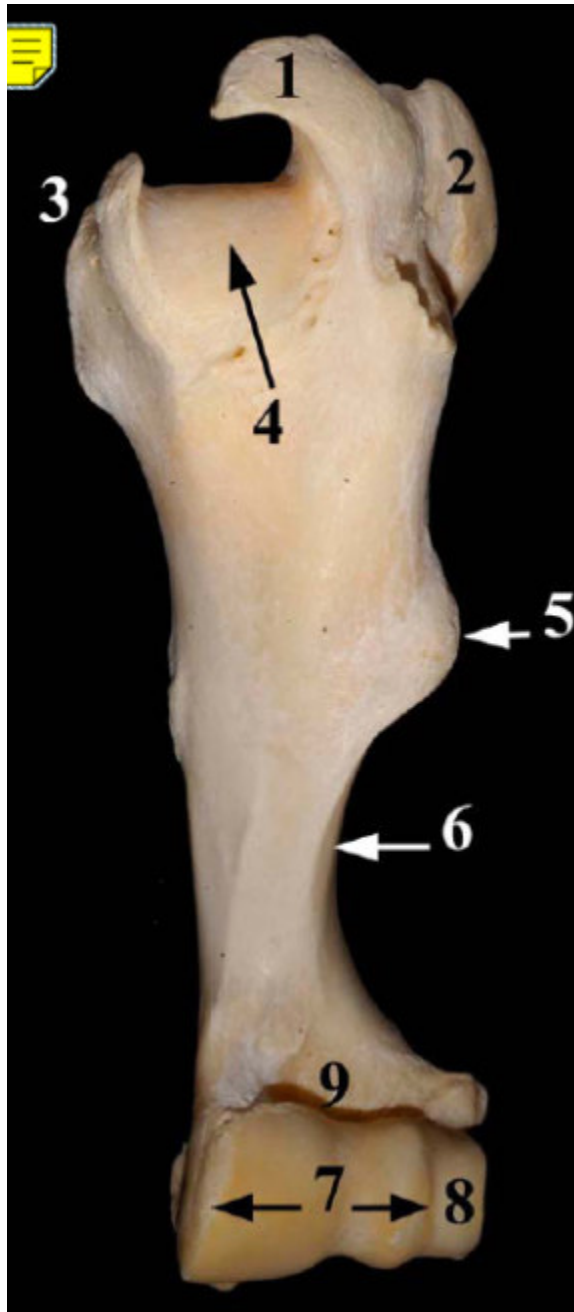
Húmero



Húmero izquierdo de bóvido, visión caudal:

- 1- Cabeza del húmero
- 2- Tubérculo mayor Porción craneal
- 3- Tubérculo mayor Porción caudal
- 4- Tubérculo menor Porción craneal
- 5- Surco intertubercular:
- 6- Tuberosidad para el M. redondo menor
- 7- Línea tricípital
- 8- Tuberosidad deltoidea
- 9- Tuberosidad para el M. redondo mayor
- 10- Epicóndilo lateral
- 11- Epicóndilo medial
- 12- Fosa del olécranon

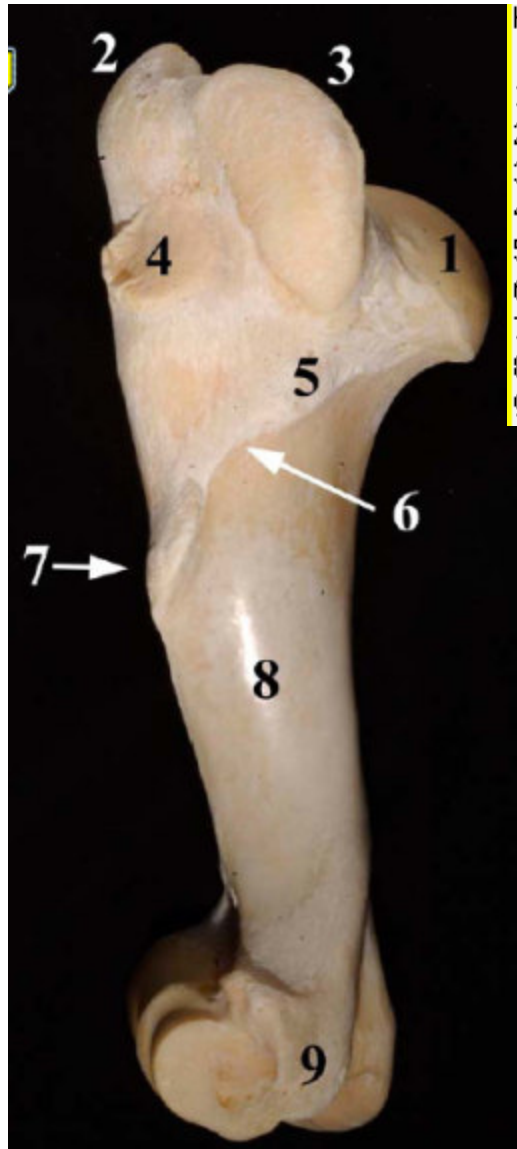Húmero



Húmero izquierdo de bóvido, visión craneal:

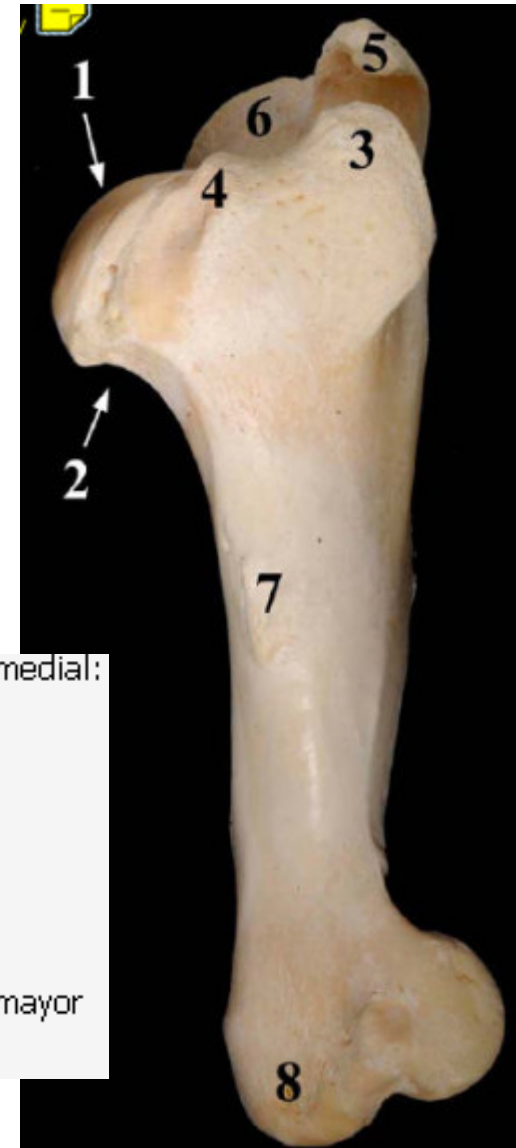- 1- Tubérculo mayor Porción craneal
- 2- Tubérculo mayor Porción caudal
- 3- Tubérculo menor
- 4- Surco intertubercular
- 5- Tuberosidad deltoidea
- 6- Cresta del húmero
- 7- Tróclea del húmero
- 8- Capítulo del húmero
- 9- Fosa radial

Húmero



Húmero de bóvido, visión lateral:

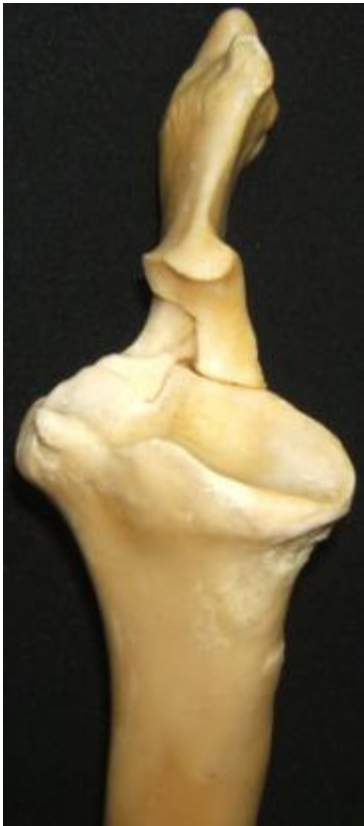- 1- Cabeza del húmero
- 2- Tubérculo mayor Porción craneal
- 3- Tubérculo mayor Porción caudal
- 4- Cara para el M. infraespinoso
- 5- Tuberosidad para el M. redondo menor
- 6- Línea tricpital
- 7- Tuberosidad deltoidea
- 8- Surco del M. braquial
- 9- Epicóndilo lateral



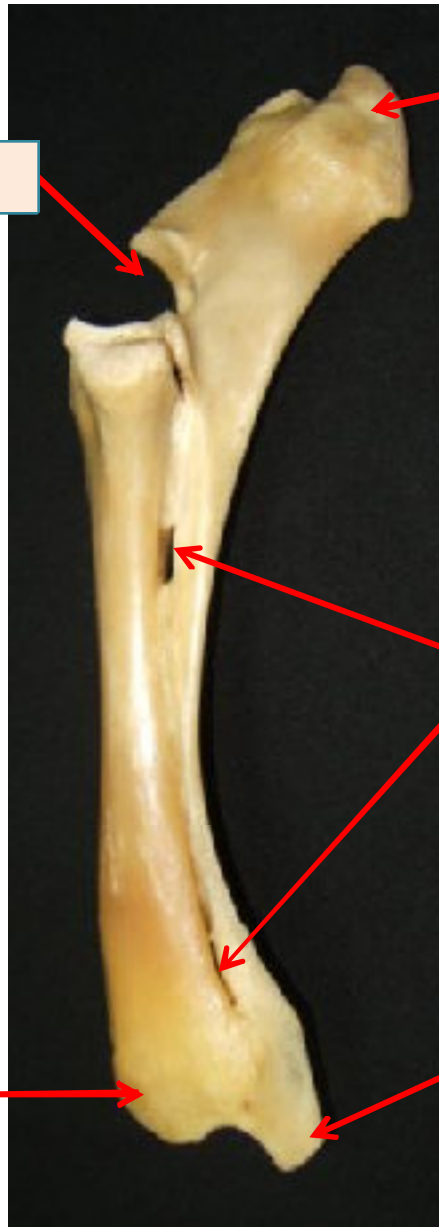Húmero izquierdo de bóvido, visión medial:

- 1- Cabeza del húmero
- 2- Cuello del húmero
- 3- Tubérculo menor Porción craneal
- 4- Tubérculo menor Porción caudal
- 5- Tubérculo mayor Porción craneal
- 6- Tubérculo mayor Porción caudal
- 7- Tuberosidad para el M. redondo mayor
- 8- Epicóndilo medial

Radio - Ulna



Incisura troclear



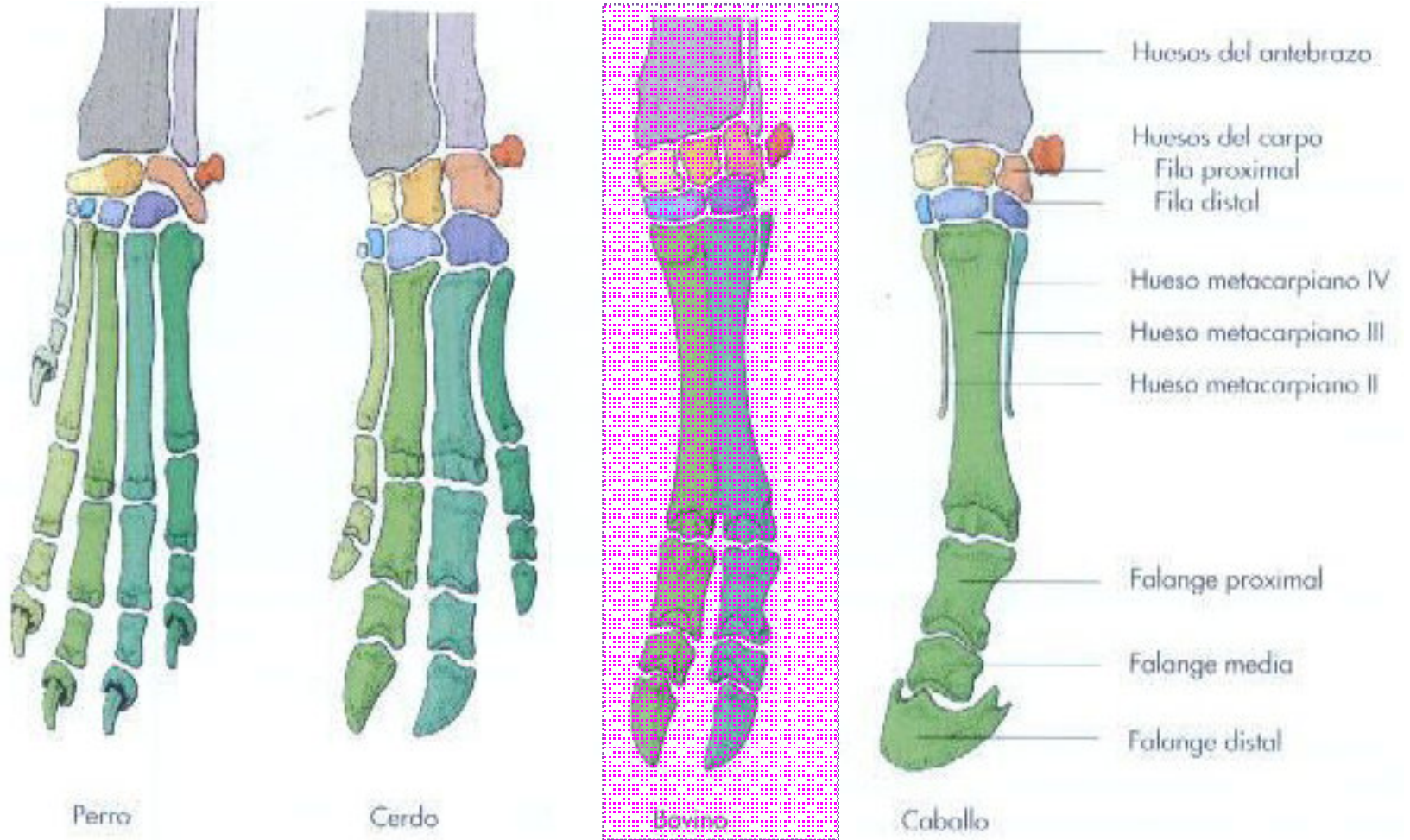
Tuberosidad olecraneana
















Espacio interóseo

Proc. Estiloídeo medial

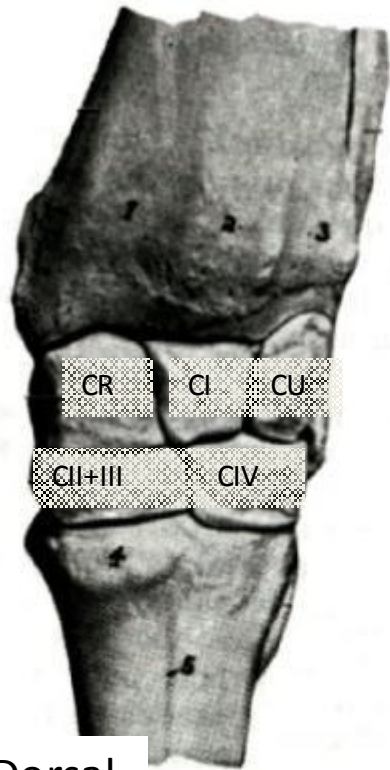Proc. Estiloídeo lateral

R. mano

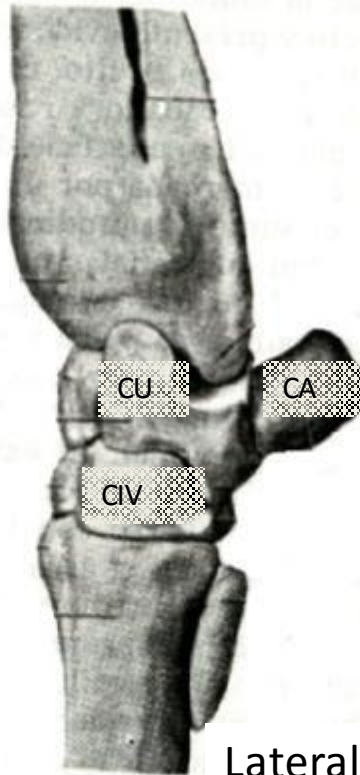


 Radio	 Hueso accesario del carpo (pisiforme)	 Hueso metacarpiano I y huesos del primer dedo
 Cúbito	 Hueso carpal I (trapecio)	 Hueso metacarpiano II y huesos del segundo dedo
 Hueso carporradial (escafoides)	 Hueso carpal II (trapezoide)	 Hueso metacarpiano III y huesos del tercer dedo
 Hueso carpal intermedio (semilunar)	 Hueso carpal III (grande)	 Hueso metacarpiano IV y huesos del cuarto dedo
 Hueso carpocubital (piramidal)	 Hueso carpal IV (ganchoso)	 Hueso metacarpiano V y huesos del quinto dedo

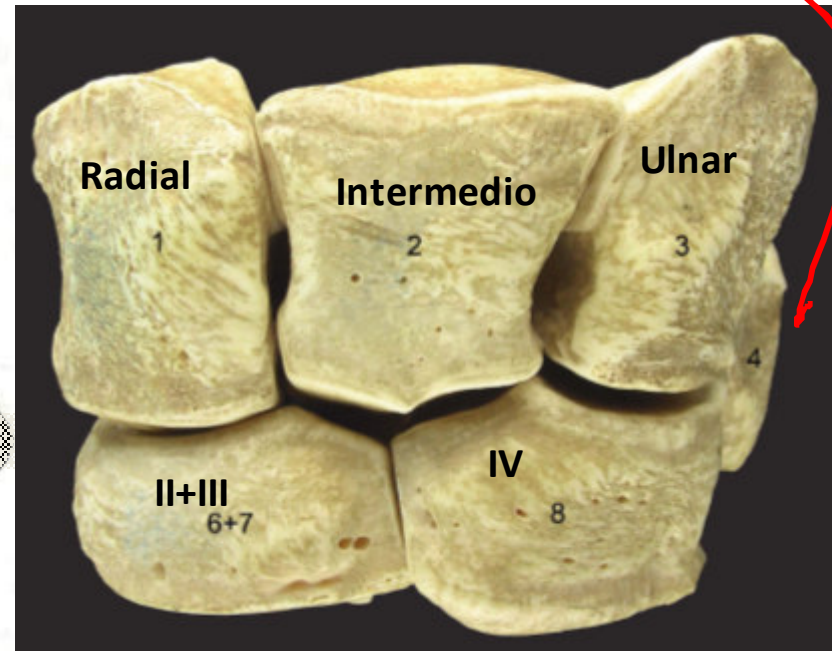
Mano: Carpo



Dorsal

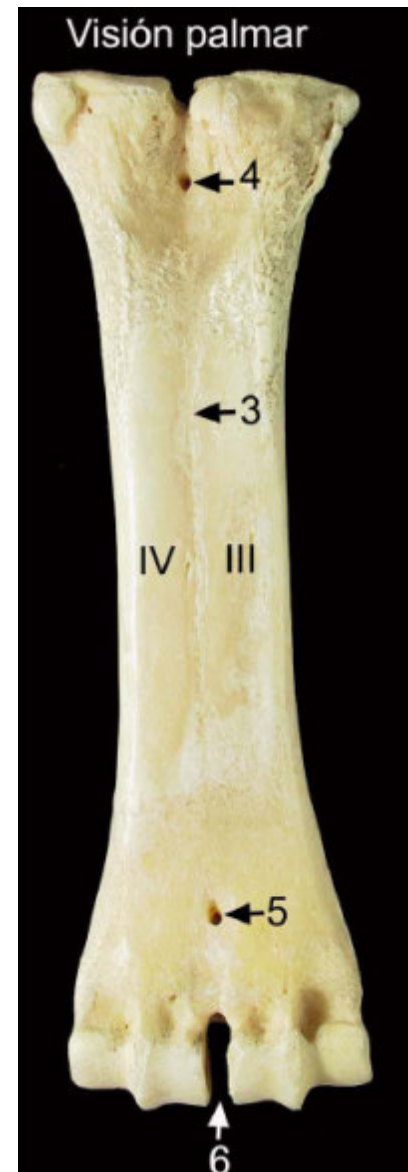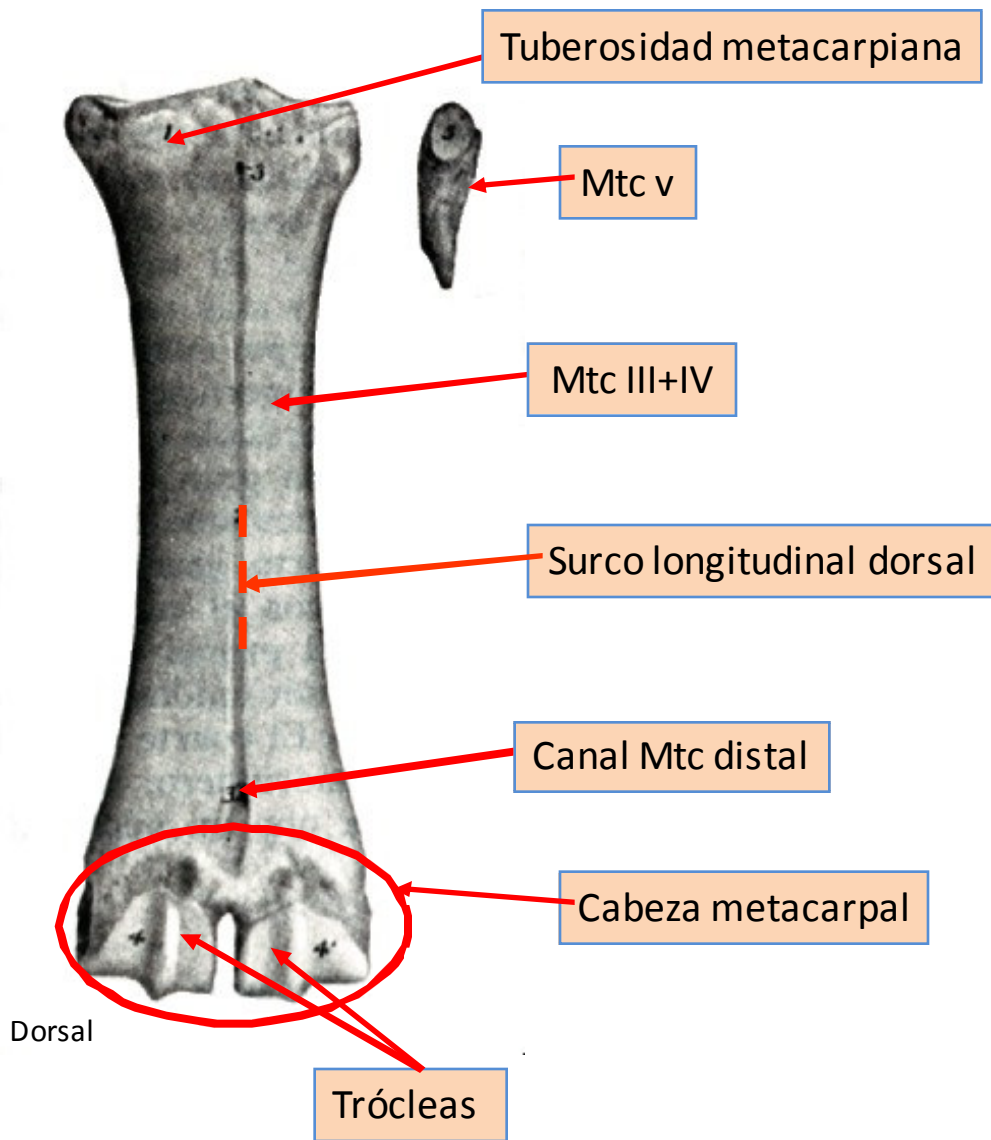


Lateral

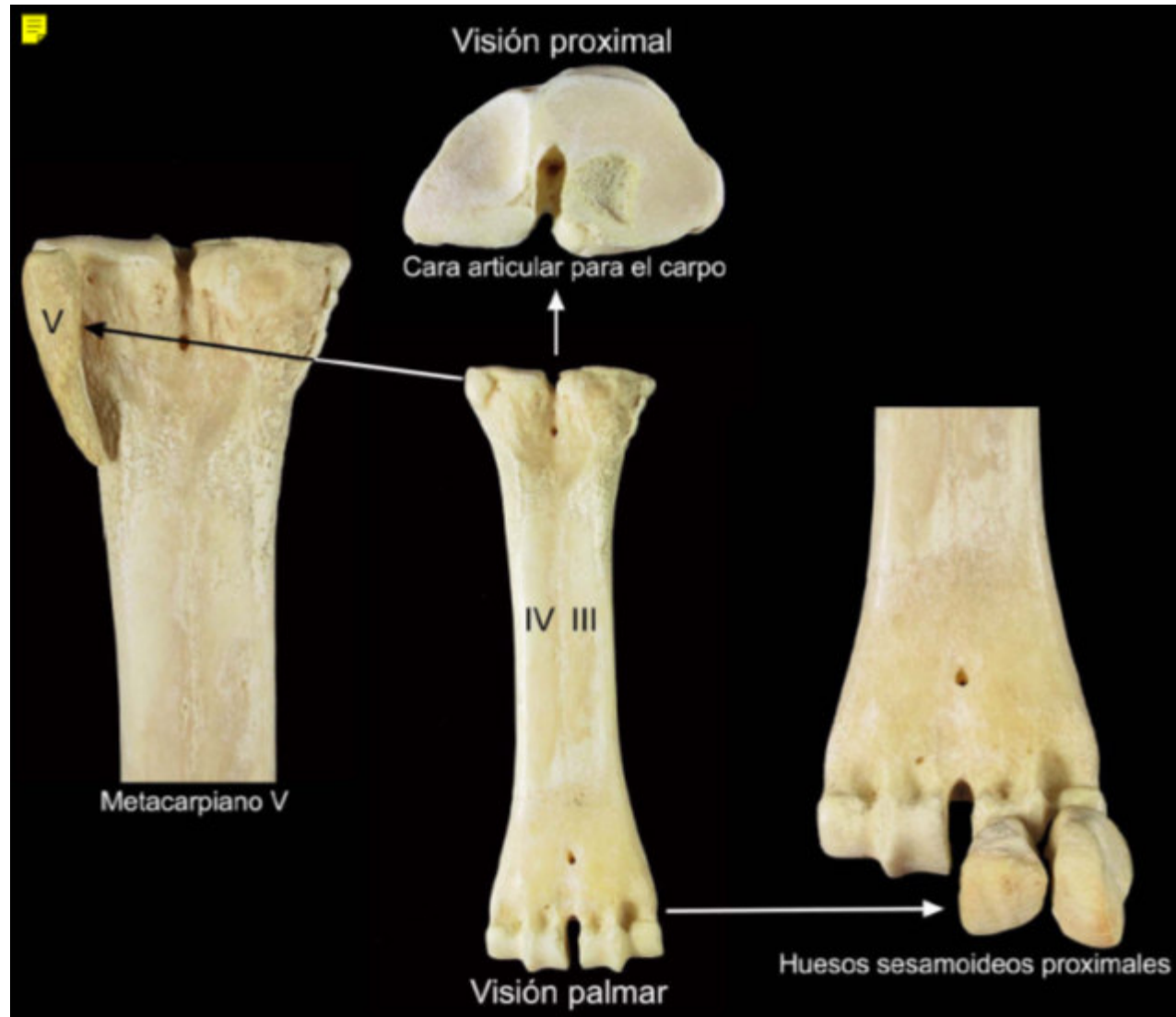


Accesorio

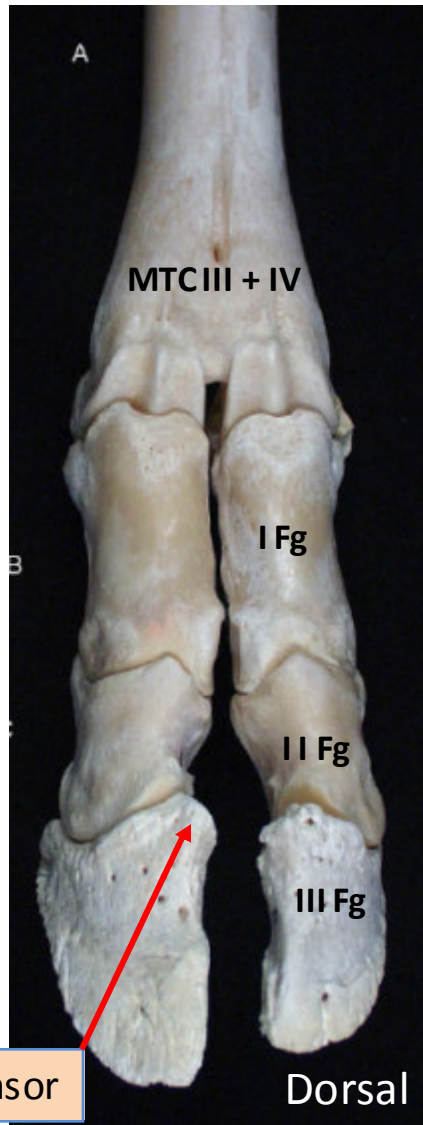
Mano: Metacarpo



Mano: Metacarpo



Mano: Dedos



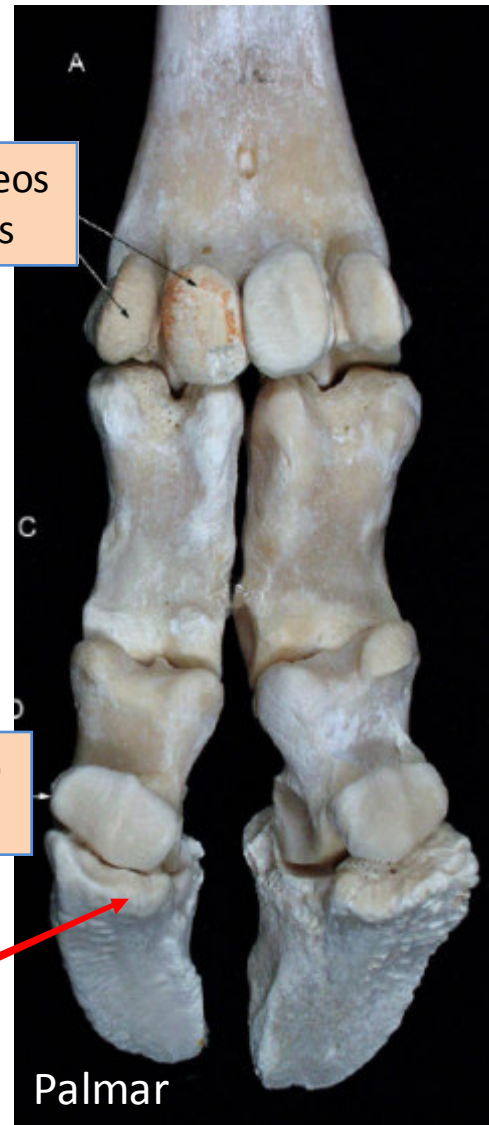P. Extensor

Dorsal

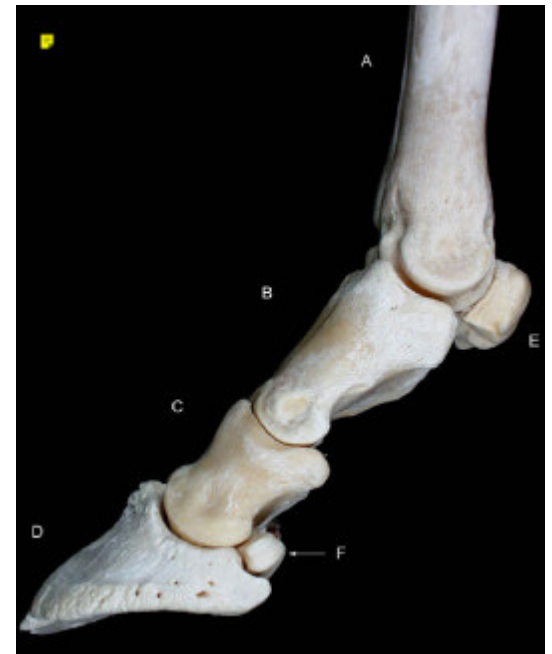Sesamoídeos proximales

Sesamoídeo distal

Sup. flexora



Palmar



PEZUÑAS

