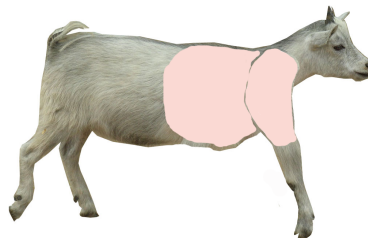
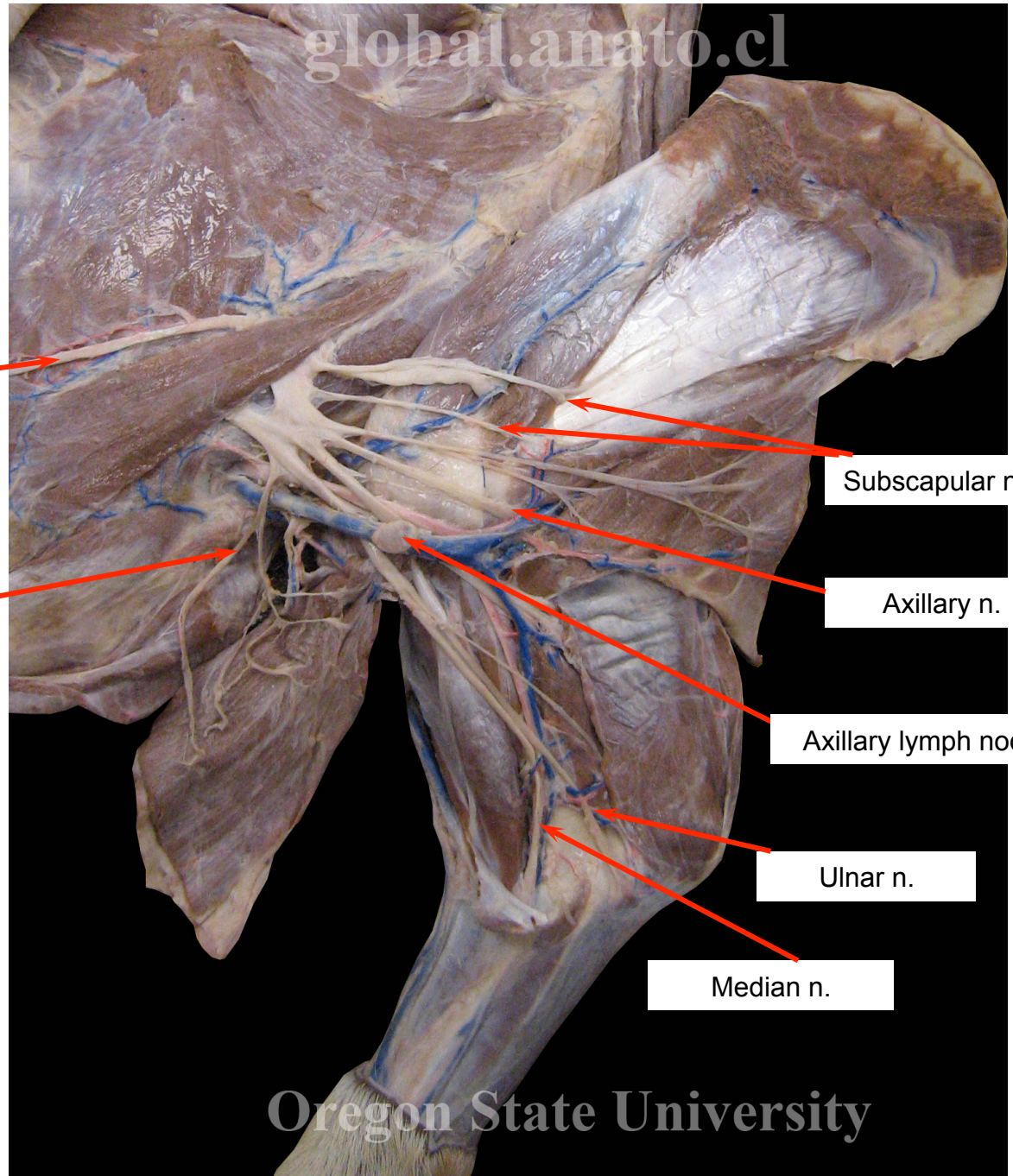
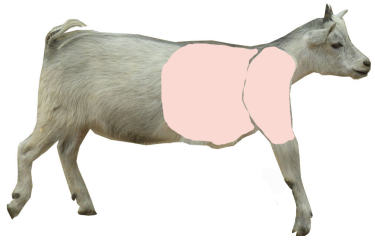


Nerves of the brachial plexus. Medial view of goat thoracic limb,



- Author: Lindsey Franz and Jodie Rhoades
Status: Students. email: franz.lindsey4@gmail.com
- Advisor: Dr. Terri Clark, Dr. Ismael Concha
- Institution: Anatomy Lab/ Oregon State University, College of Veterinary Medicine/ Corvallis, Oregon, United States of America
- Year: 2009
- Language: English



Long thoracic n.

Caudal pectoral n.

Subscapular nn.

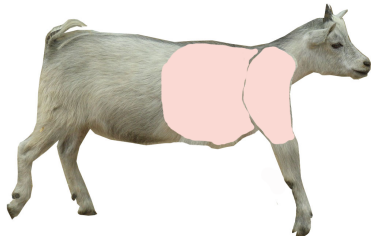
Axillary n.

Axillary lymph node

Ulnar n.

Median n.

Oregon State University



Long thoracic n.

Caudal pectoral n

Axillary lymph node

Median n.

Ulnar n.

Radial n.

Subscapular nn.

Axillary n.

global.anato.cl

Oregon State University

