Universidad Santo Tomás.
Escuela de Medicina Veterinaria.
Anatomía I.

Sistema cardiovascular.

Cabeza, cuello, tronco y cola.

Dr. César Caro Munizaga, DVM.

Sistema cardiovascular.

- Corazón:
  - Anatomía.
  - Fisioanatomía.
  - Circulación mayor y menor.
  - Irrigación y drenaje nutricios.
  - Sistema excitoconductor.
  - Saco pericárdico.
- Irrigación y drenaje:
  - Pared y órganos torácicos.
  - Cabeza.
  - Encéfalo y médula espinal.
  - Pared y órganos abdominales.
  - Cavidad y órganos pélvicos.
  - Circulación fetal.

Sistema cardiovascular, corazón, anatomía.

EIC 3,4 y 5.

Sistema cardiovascular, corazón, anatomía.

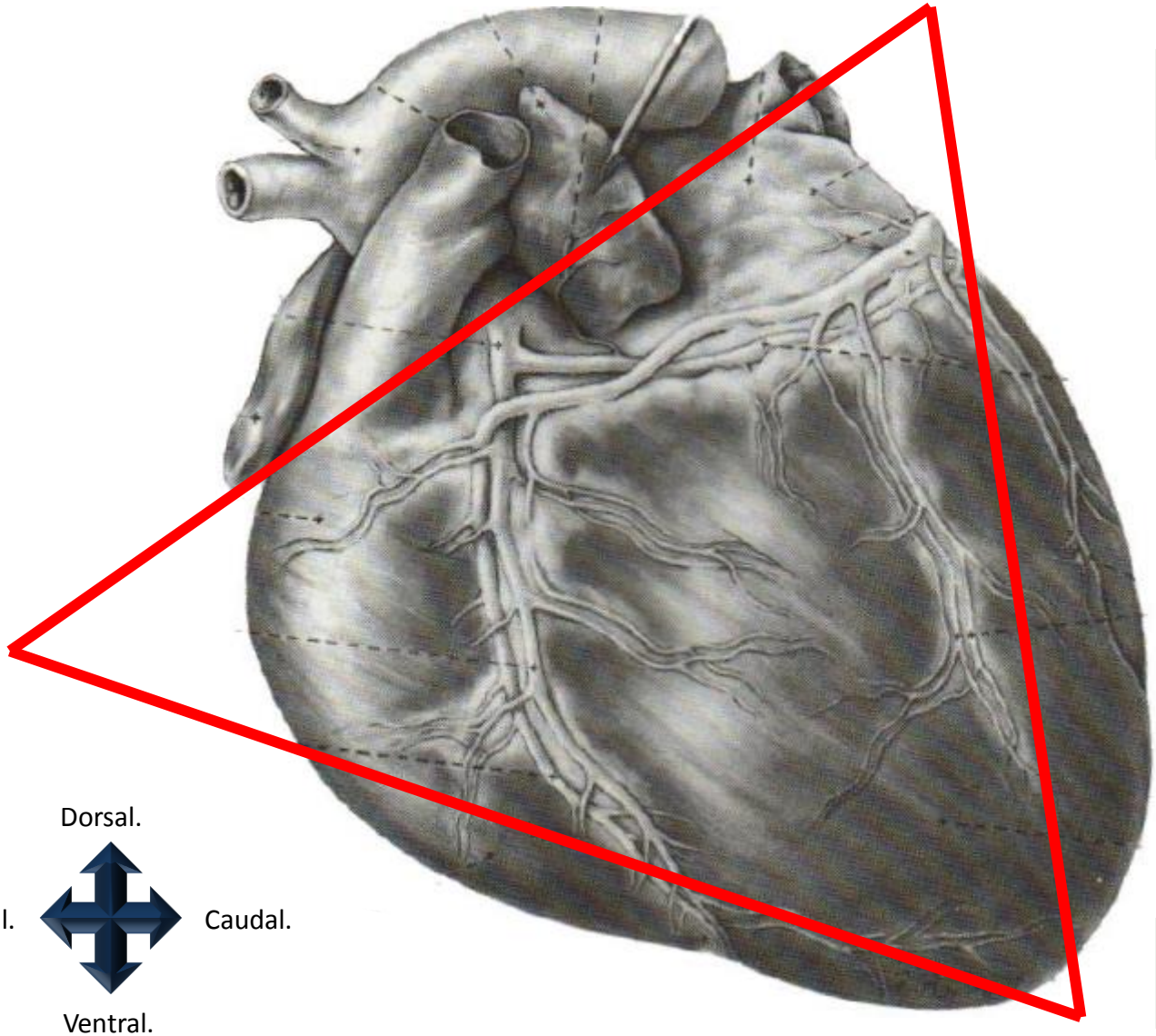

Base.

Vértice.

Dorsal.

Craneal.

Caudal.

Ventral.

Sistema cardiovascular, corazón, anatomía.

Cara auricular (lado izquierdo).

Cara atrial (lado derecho).

Es importante identificar la cara del corazón para saber cuáles son las estructuras a identificar.

Sistema cardiovascular, corazón, anatomía.

Cara auricular.

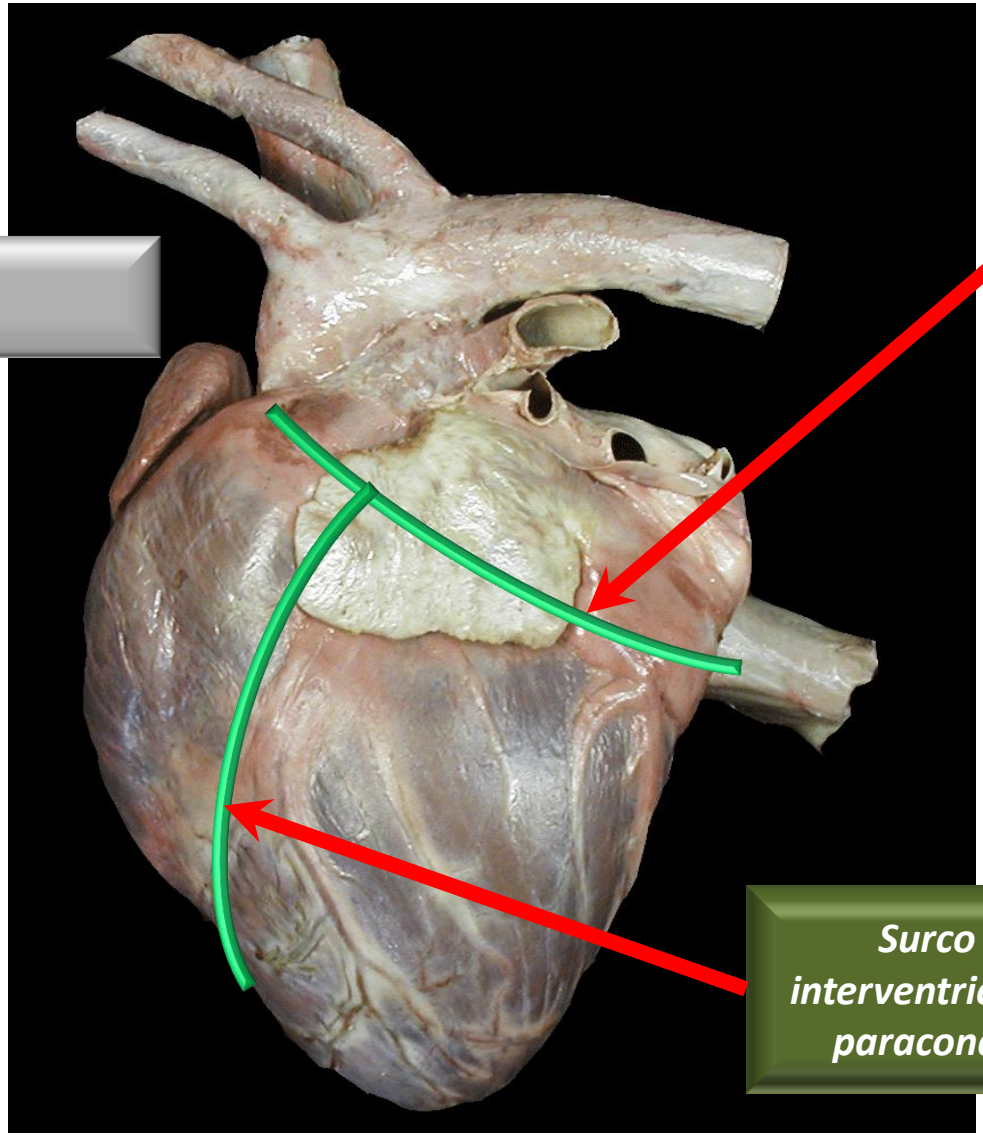

Sistema cardiovascular, corazón, anatomía.

Cara atrial.

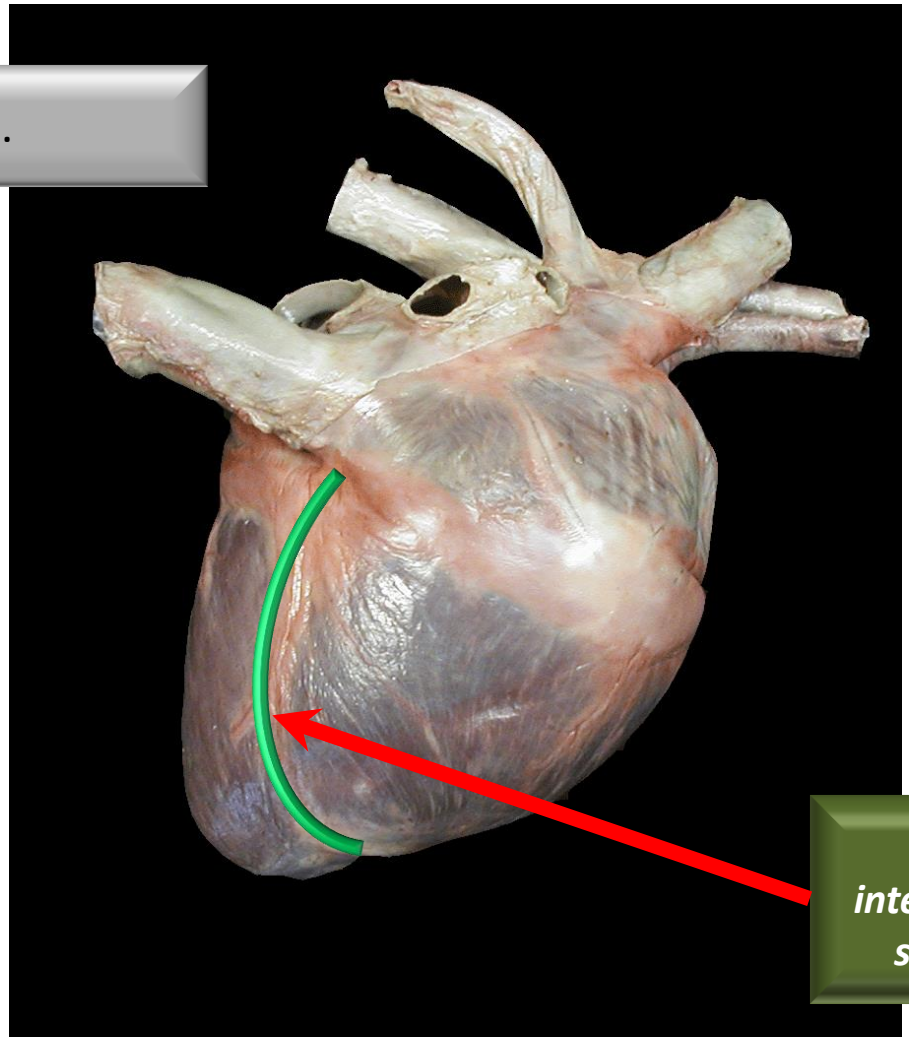

Surco interventricular subsinusal.

Sistema cardiovascular, corazón, anatomía.

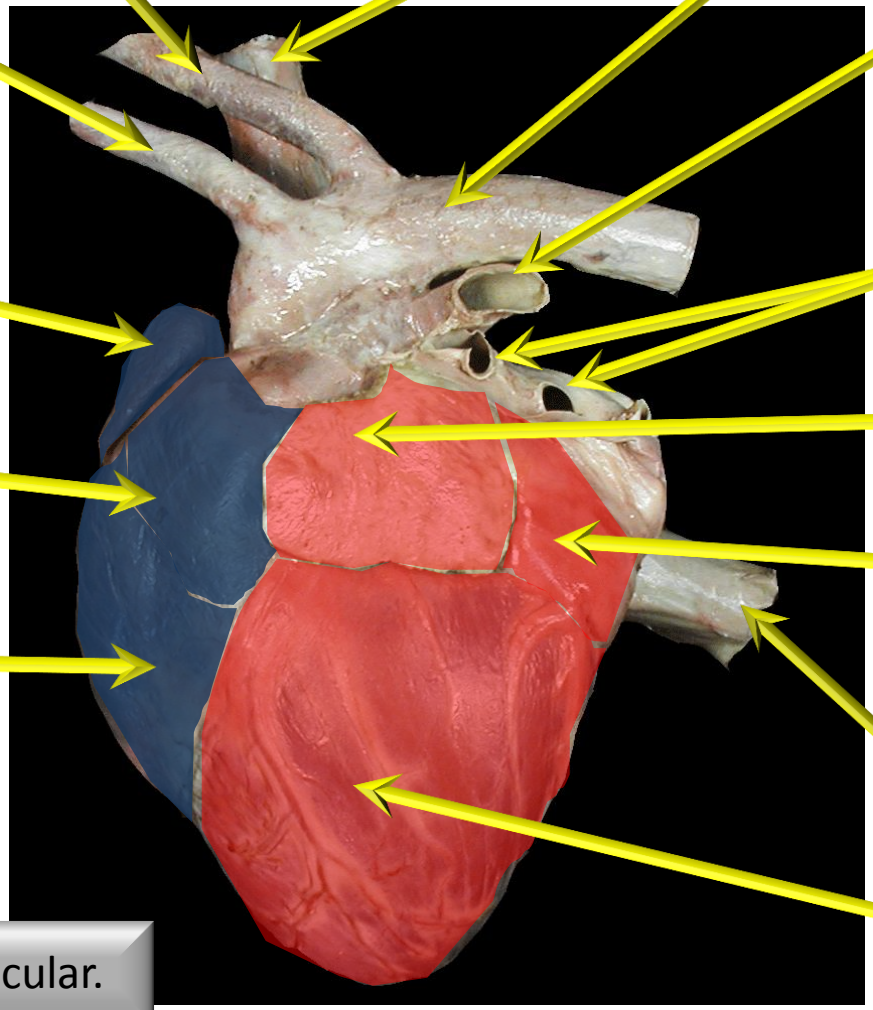

Sistema cardiovascular, corazón, anatomía.

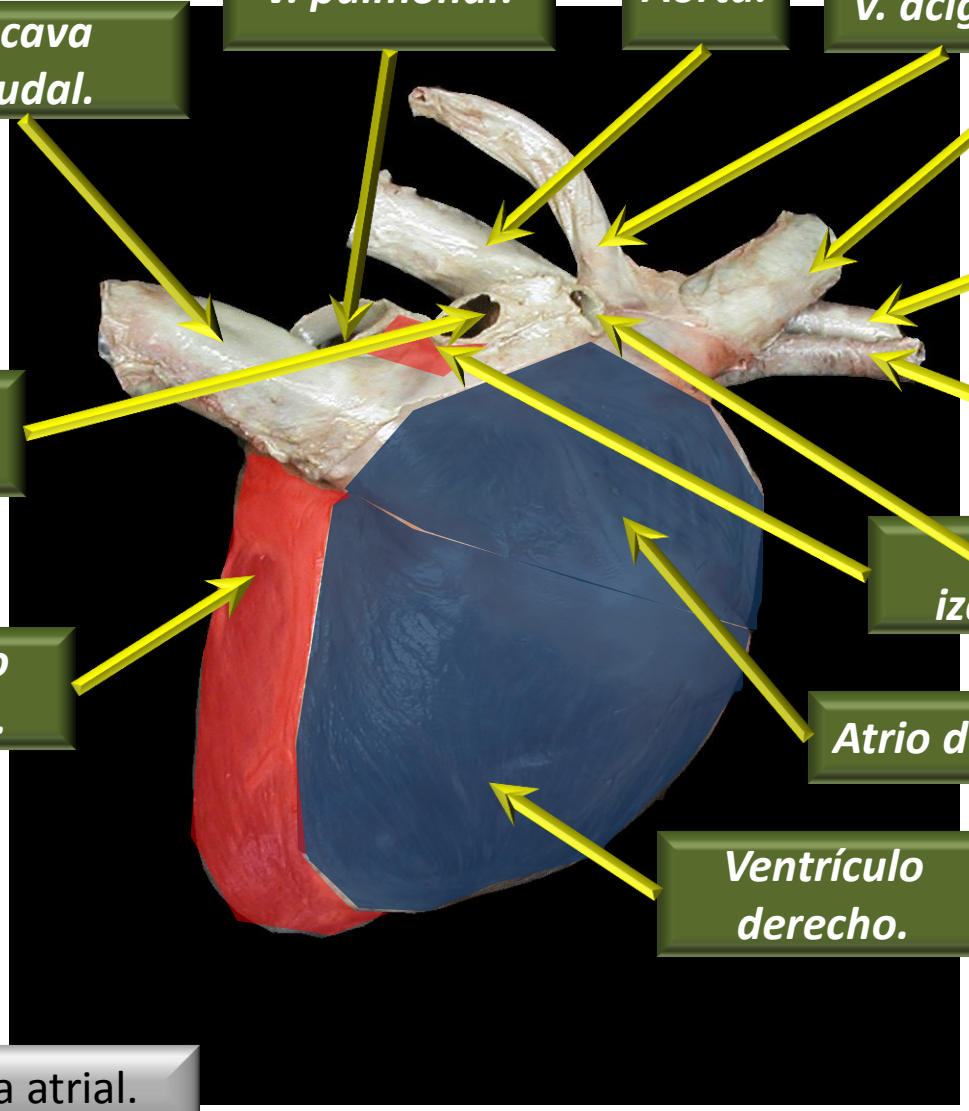

Cara atrial.

Sistema cardiovascular, corazón, anatomía.

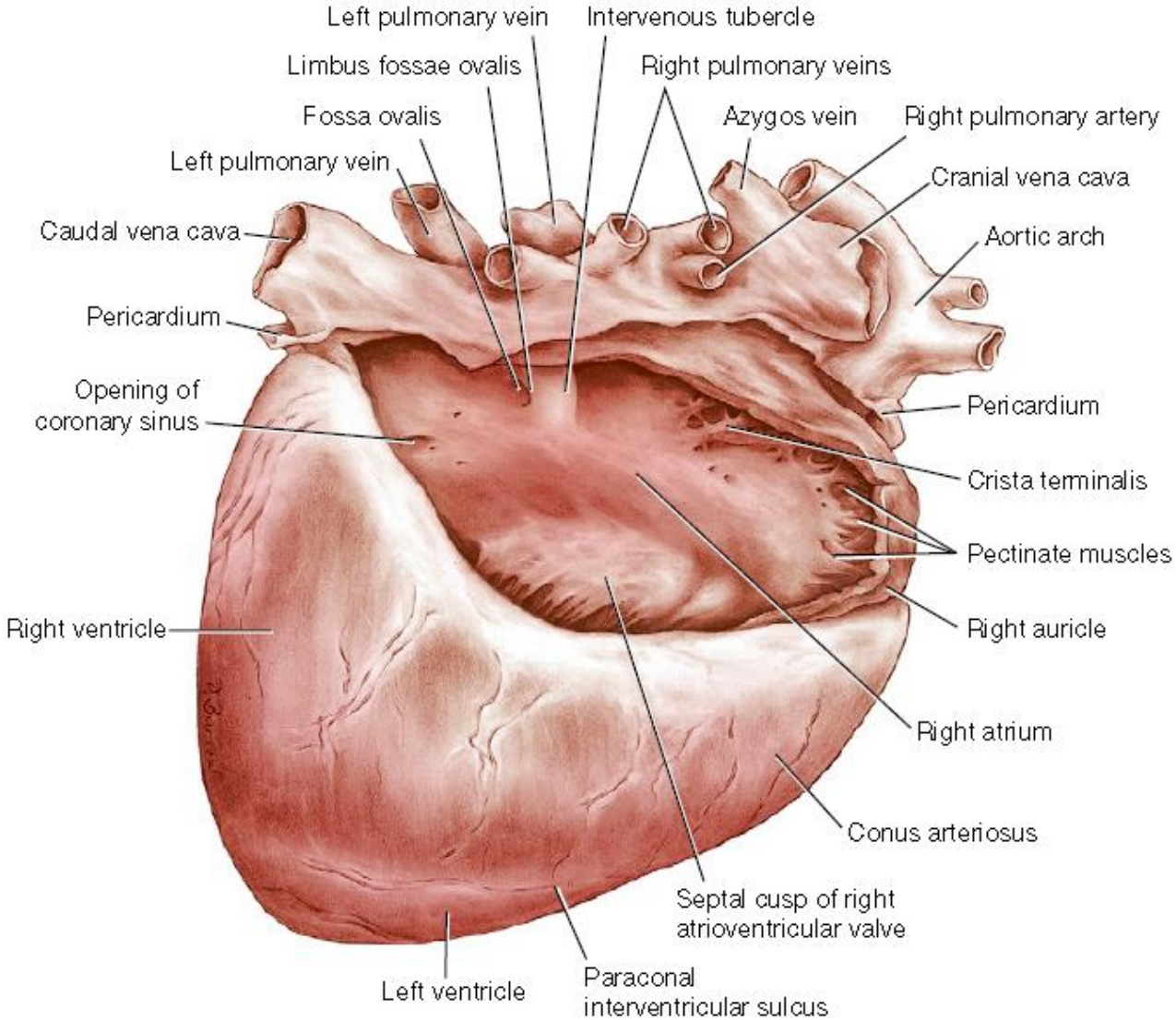

Fig. 3-22 Interior of right atrium, right lateral aspect.

Sistema cardiovascular, corazón, anatomía.

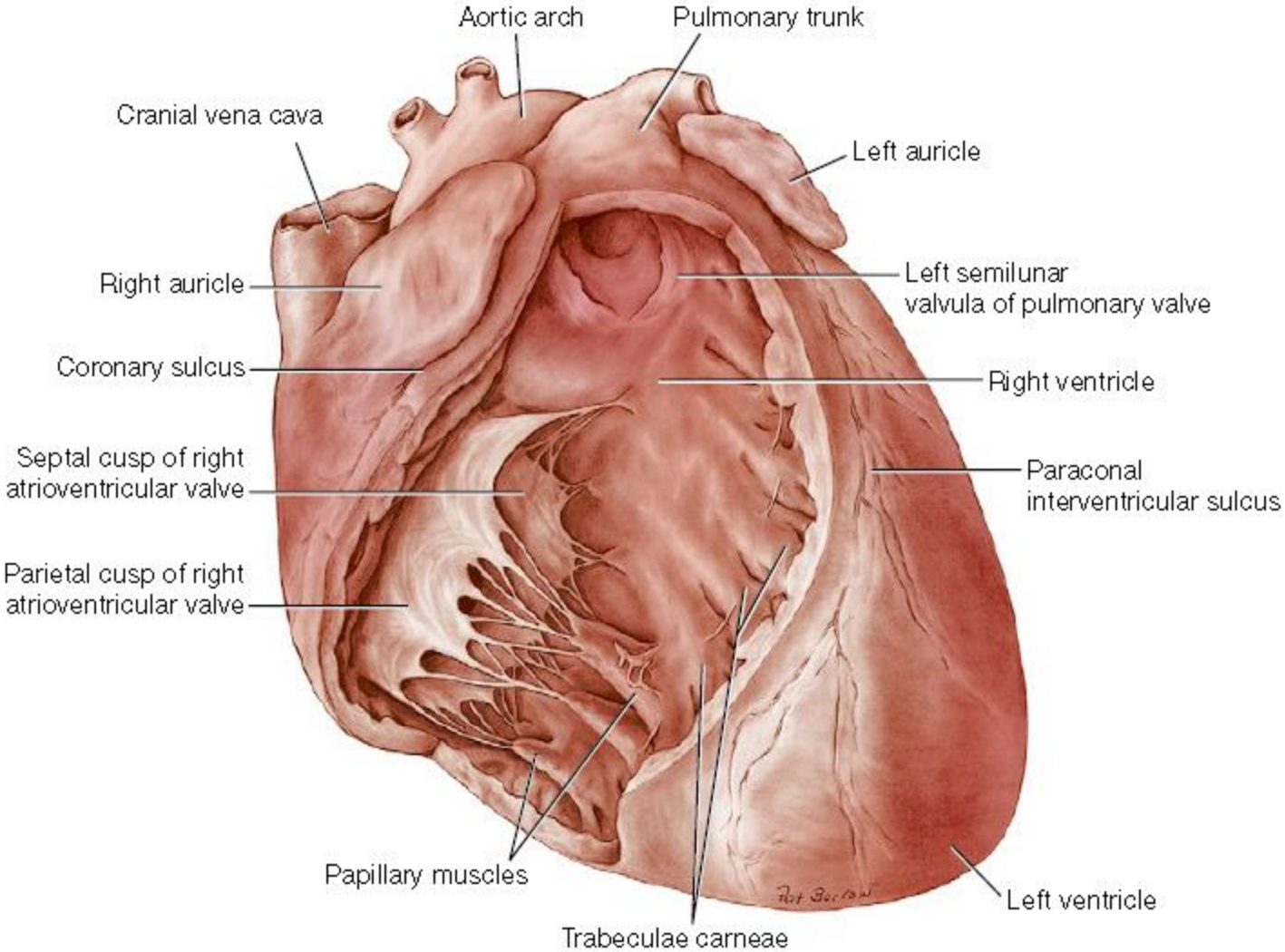

Fig. 3-23 Interior of right ventricle, left lateral aspect.

Sistema cardiovascular, corazón, anatomía.

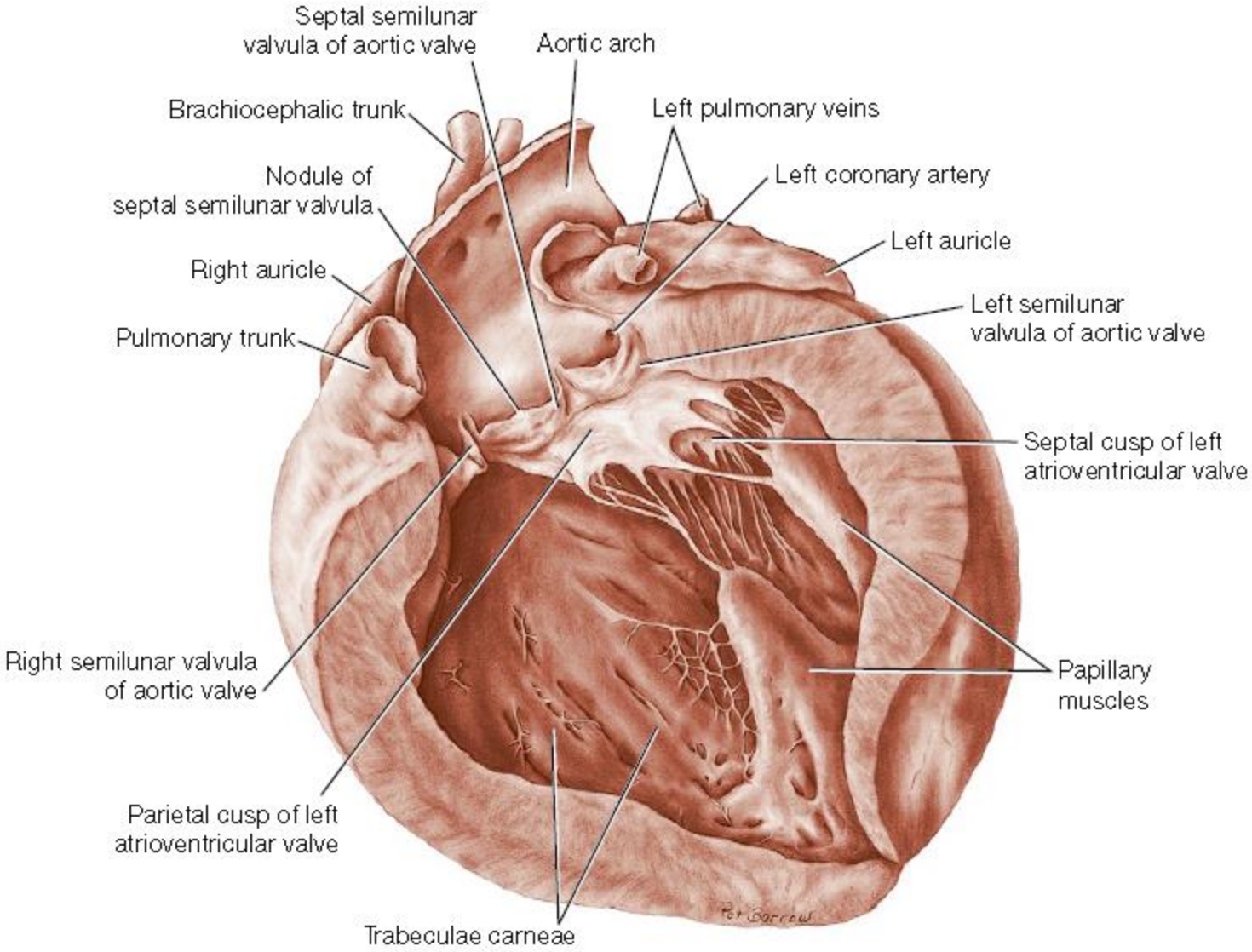

Fig. 3-24 Interior of left ventricle, left lateral aspect.

Sistema cardiovascular, corazón, anatomía.

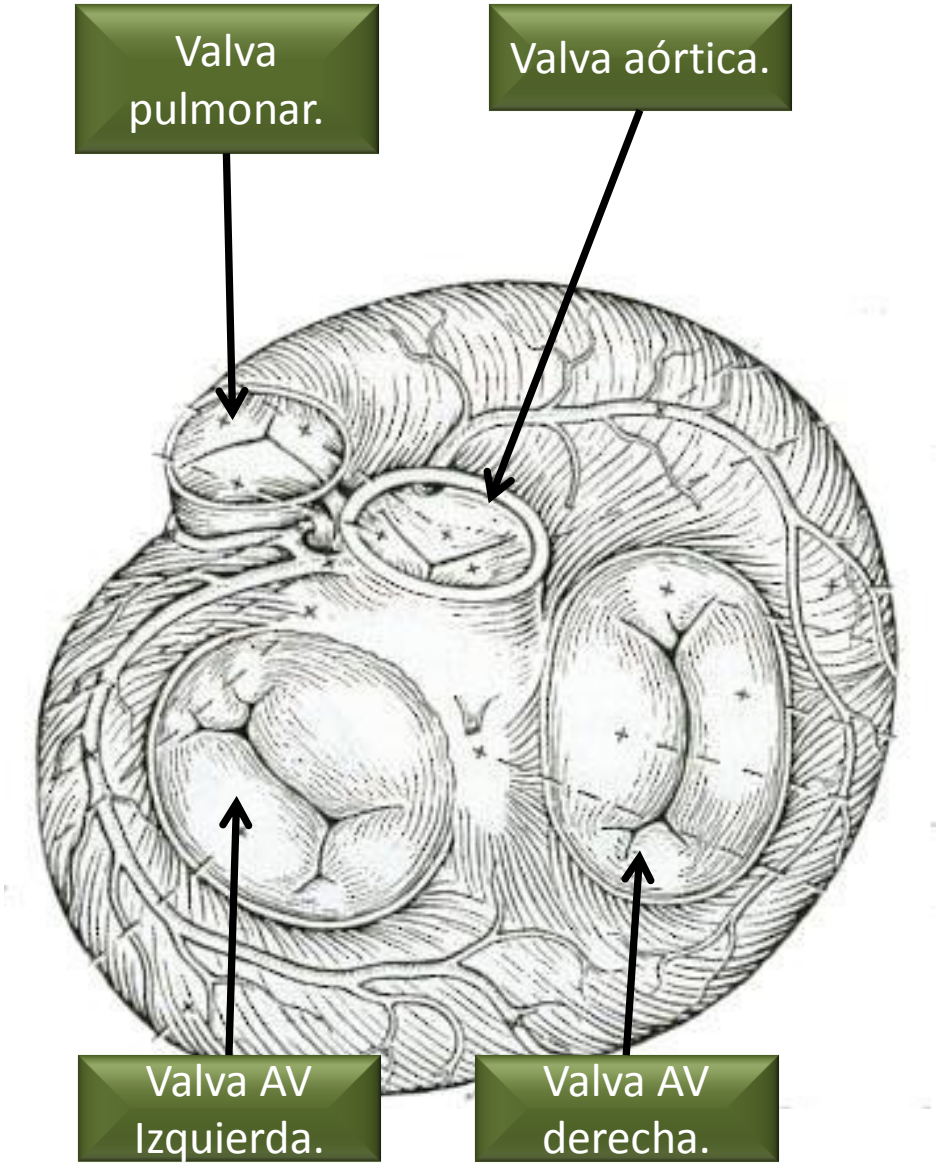

Sistema cardiovascular, corazón, anatomía.

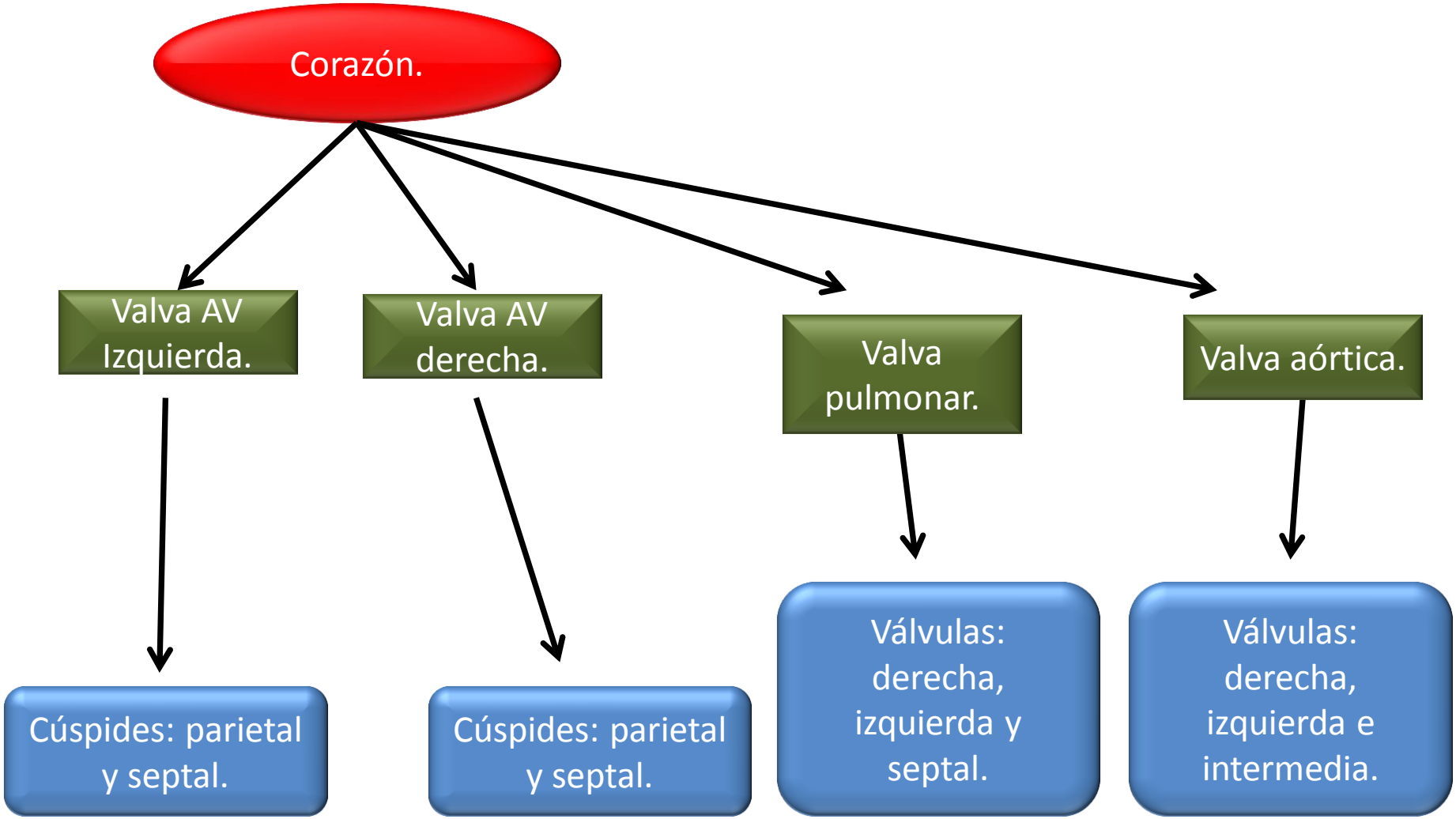

Las valvas AV derecha e izquierda poseen cúspides; las valvas aórtica y pulmonar poseen válvulas semilunares. Además se encuentran válvulas en venas y vasos linfáticos.

Sistema cardiovascular, corazón, anatomía.

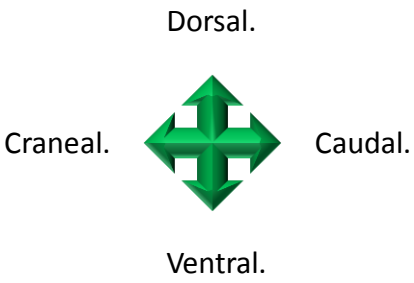

Esquema de la irrigación nutricia del corazón, cara auricular (vista izquierda).

Sistema cardiovascular, corazón, anatomía.

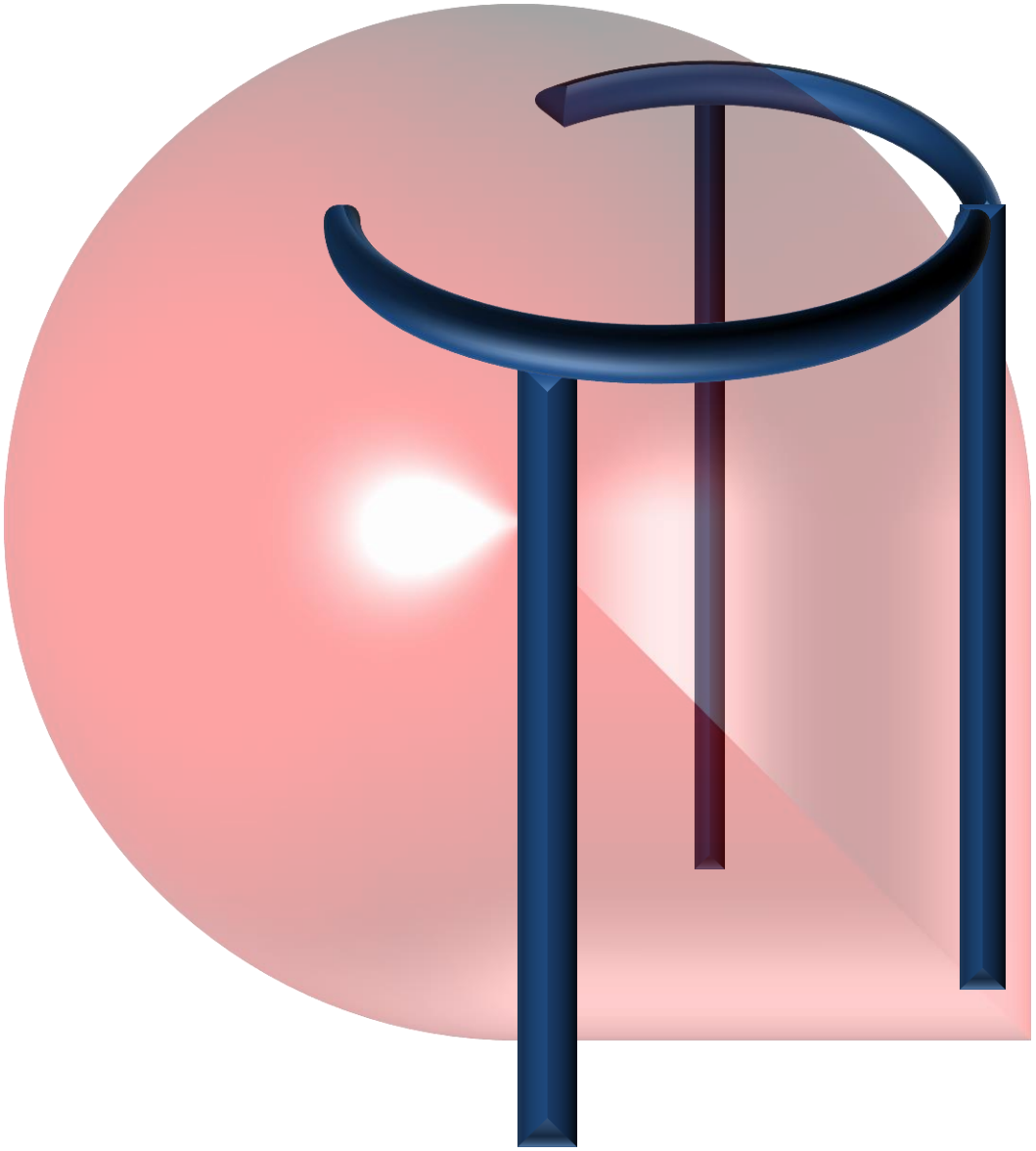

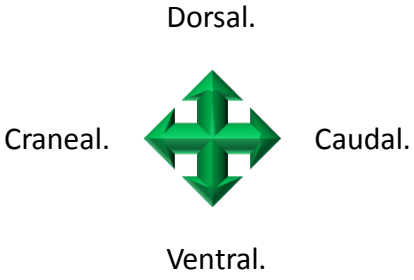

Esquema del drenaje nutricio del corazón, vista izquierda (cara auricular).

Sistema cardiovascular, corazón, anatomía.

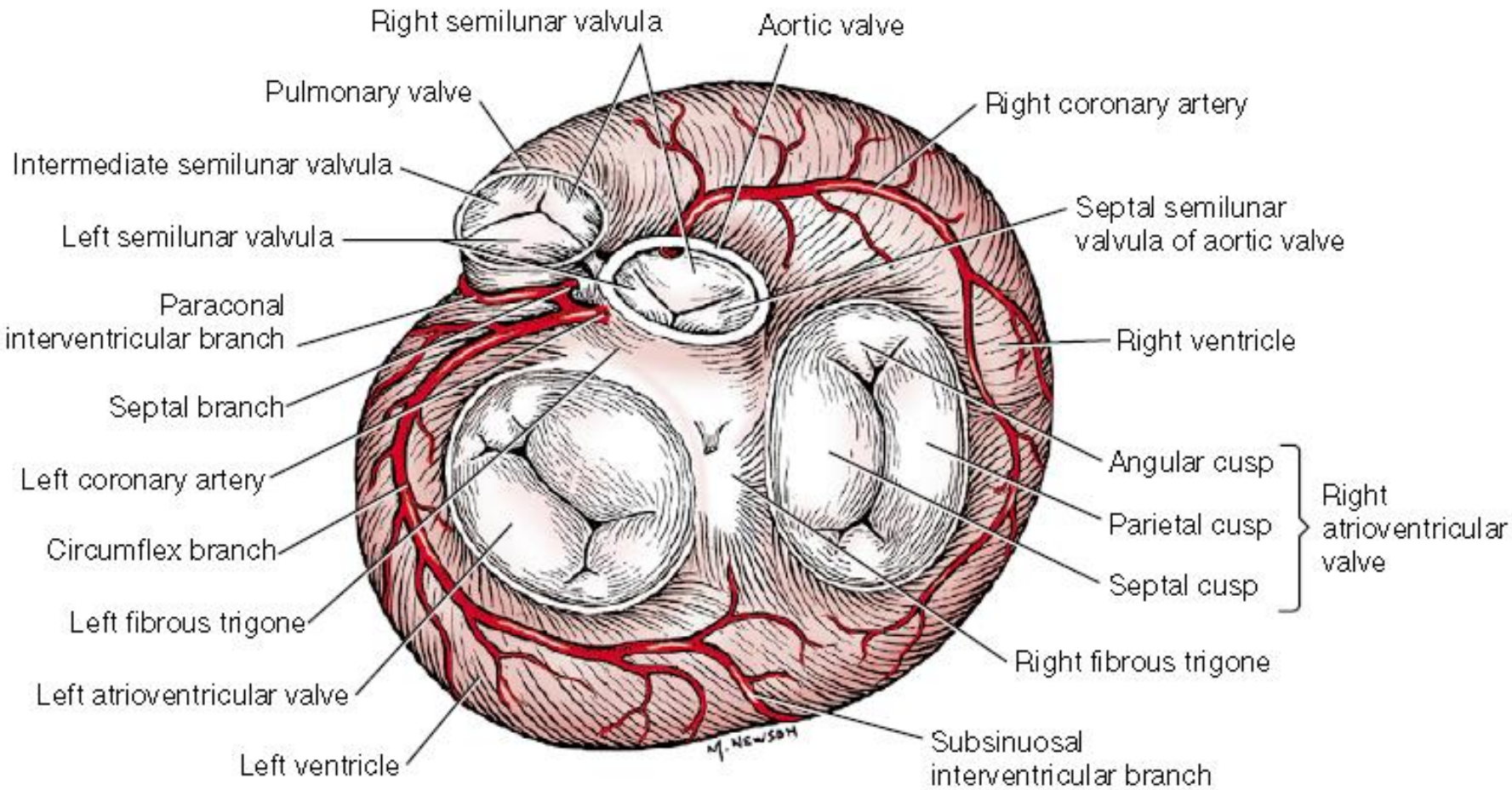

Fig. 3-25 Atrioventricular, aortic, and pulmonary valves, dorsoventral view.

Sistema cardiovascular, corazón, anatomía.

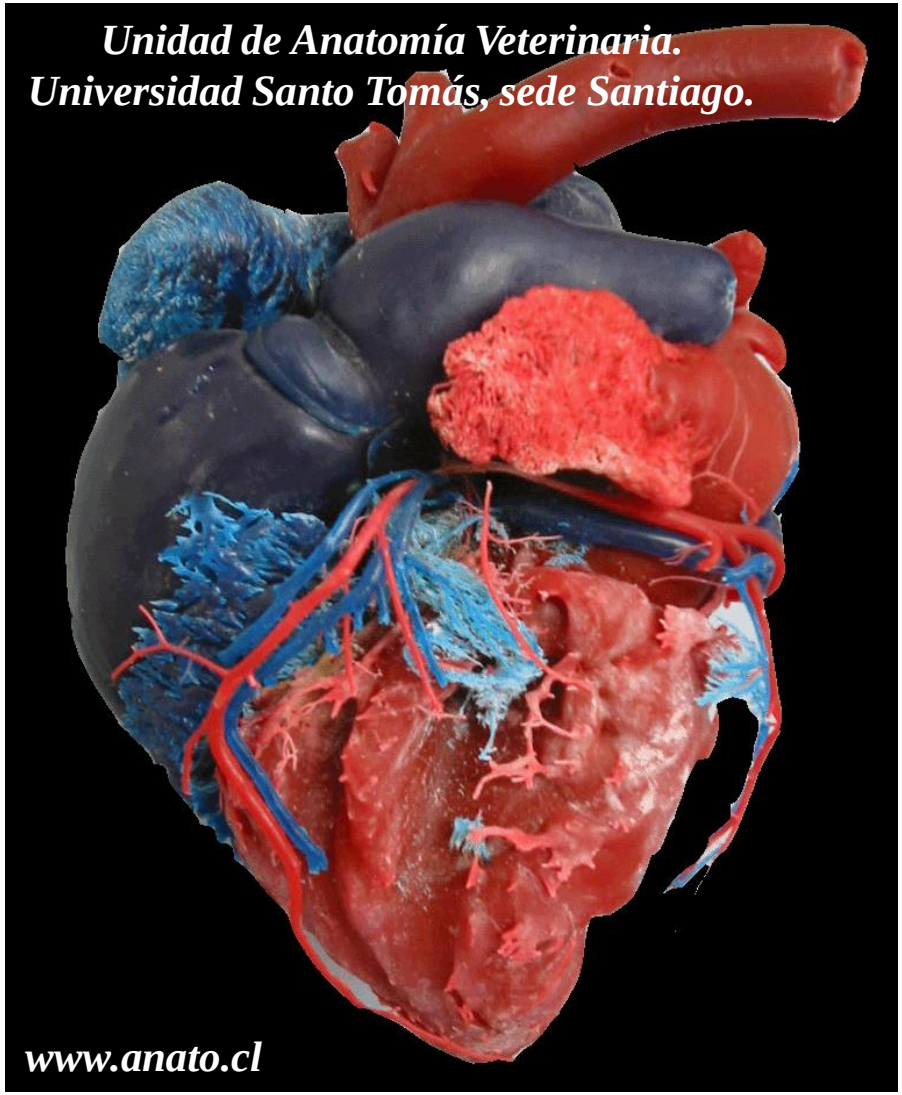

Dorsal.

Craneal.

Caudal.

Ventral.

Corrosión de corazón de canino, cara auricular (vista izquierda).

Sistema cardiovascular, corazón, anatomía.

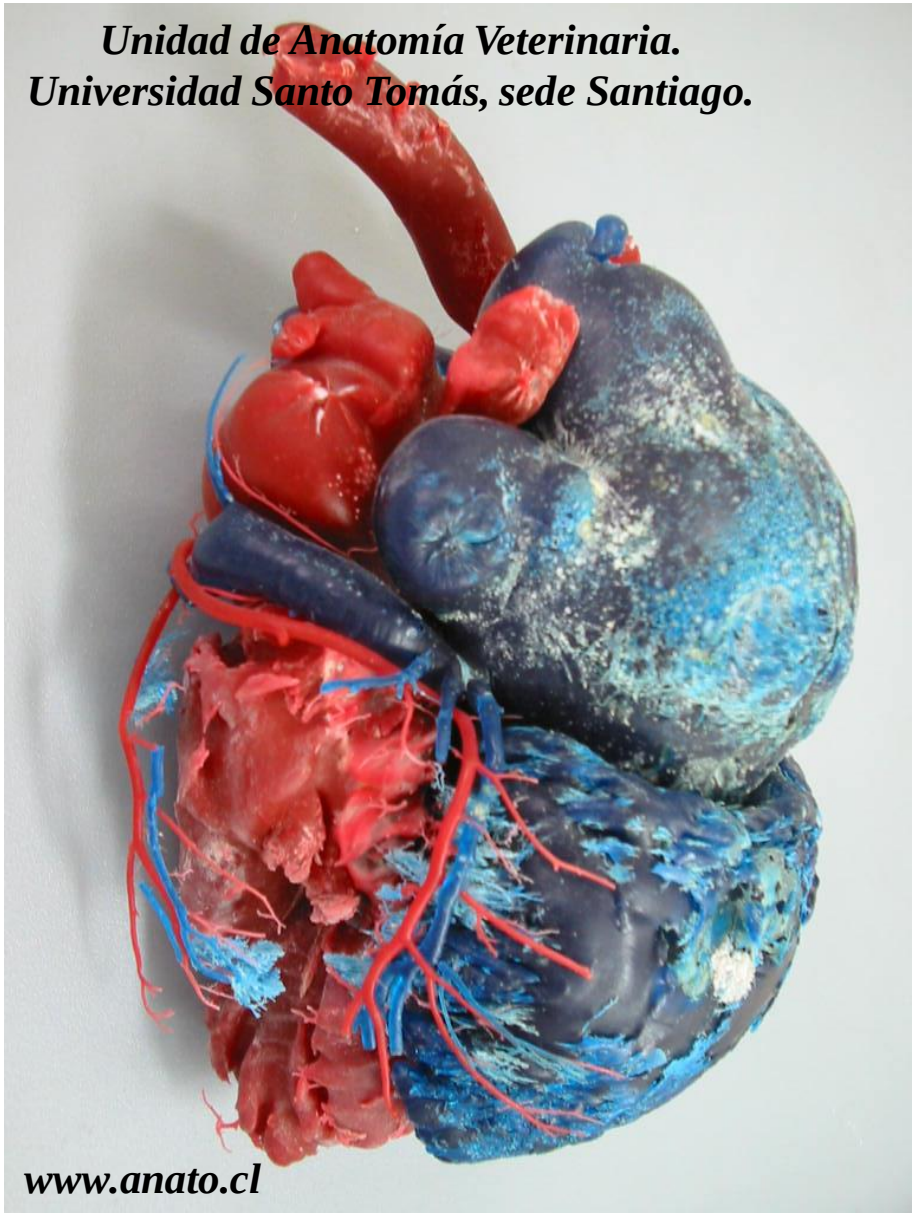

Dorsal.

Craneal.

Caudal.

Ventral.

Corrosión de corazón de canino, cara atrial (vista derecha).

Sistema cardiovascular, corazón, anatomía.

Nodo sinoatrial: Ubicado en la cresta terminal, en el seno de las venas cavas (v. cava craneal). Marcapaso.

Nodo atrioventricular: relacionado con el seno coronario.

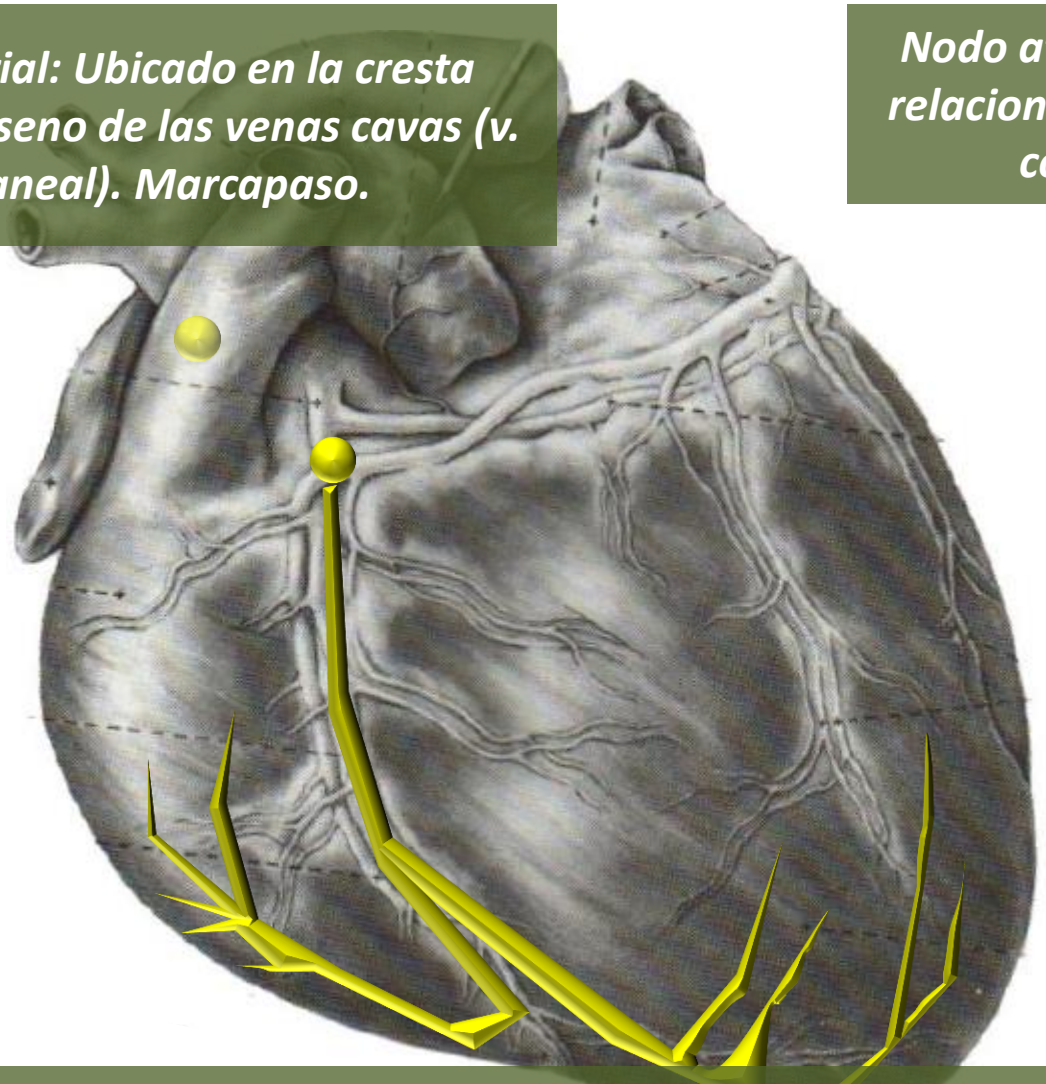

Fascículo atrioventricular: posee un tronco y pilares derecho e izquierdo. Produce la propagación del estímulo nervioso a los ventrículos.

Sistema cardiovascular, corazón, anatomía.

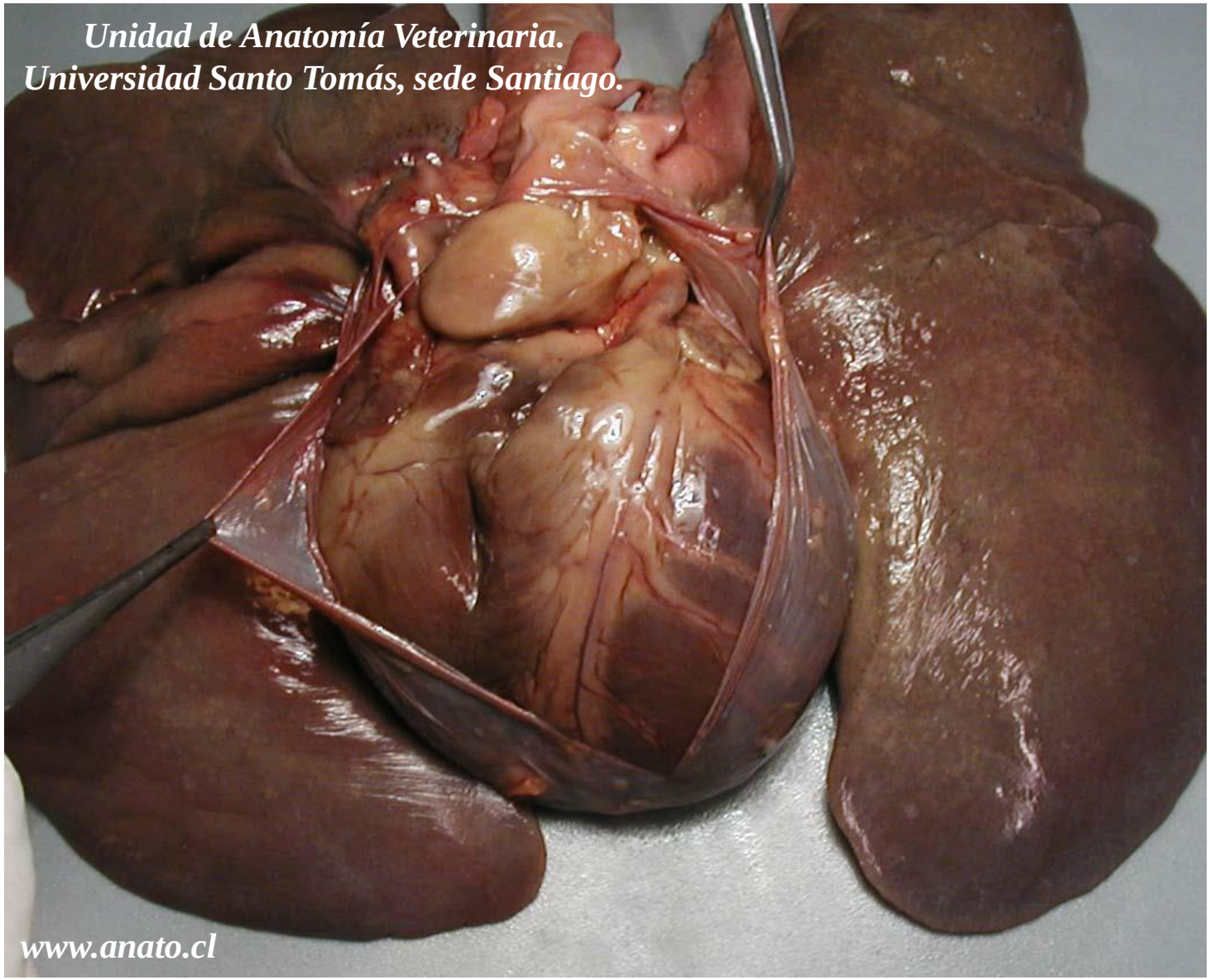

Sistema cardiovascular, corazón, anatomía.

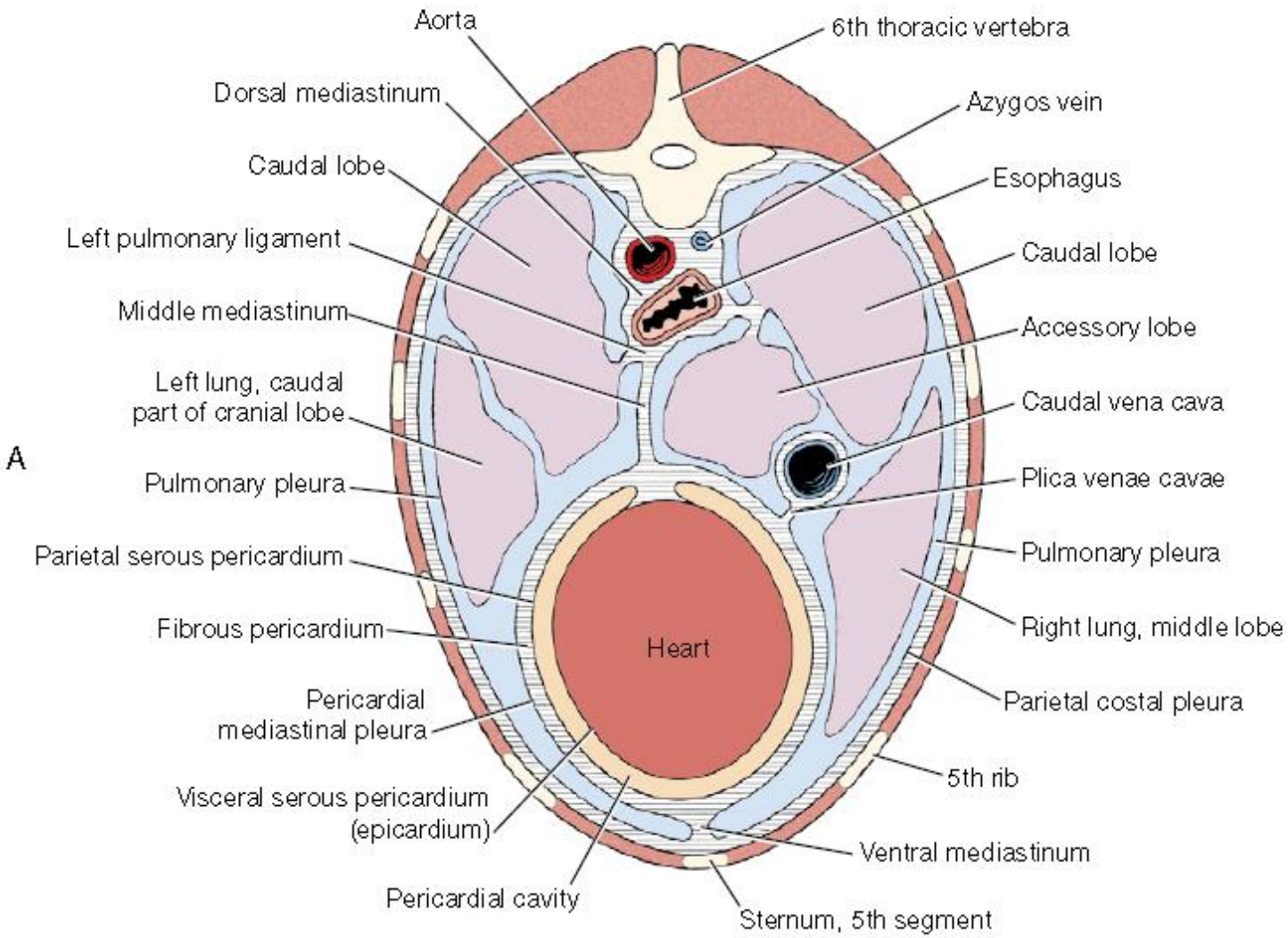

Fig. 3-9 **A**, Schematic transverse section of thorax through heart, caudal view.

Sistema cardiovascular, corazón, fisioanatomía.

Corazón derecho.

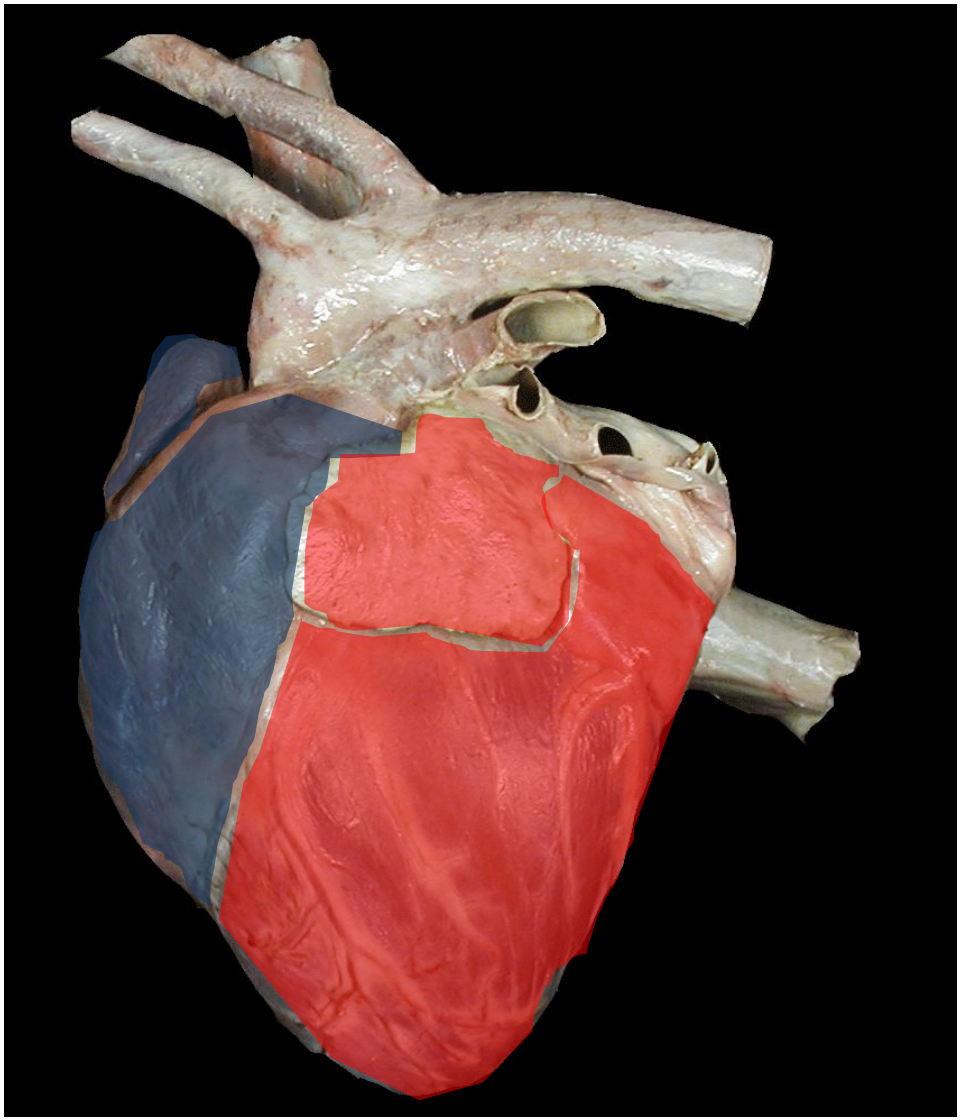

Corazón izquierdo.

Sistema cardiovascular, corazón, fisioanatomía.

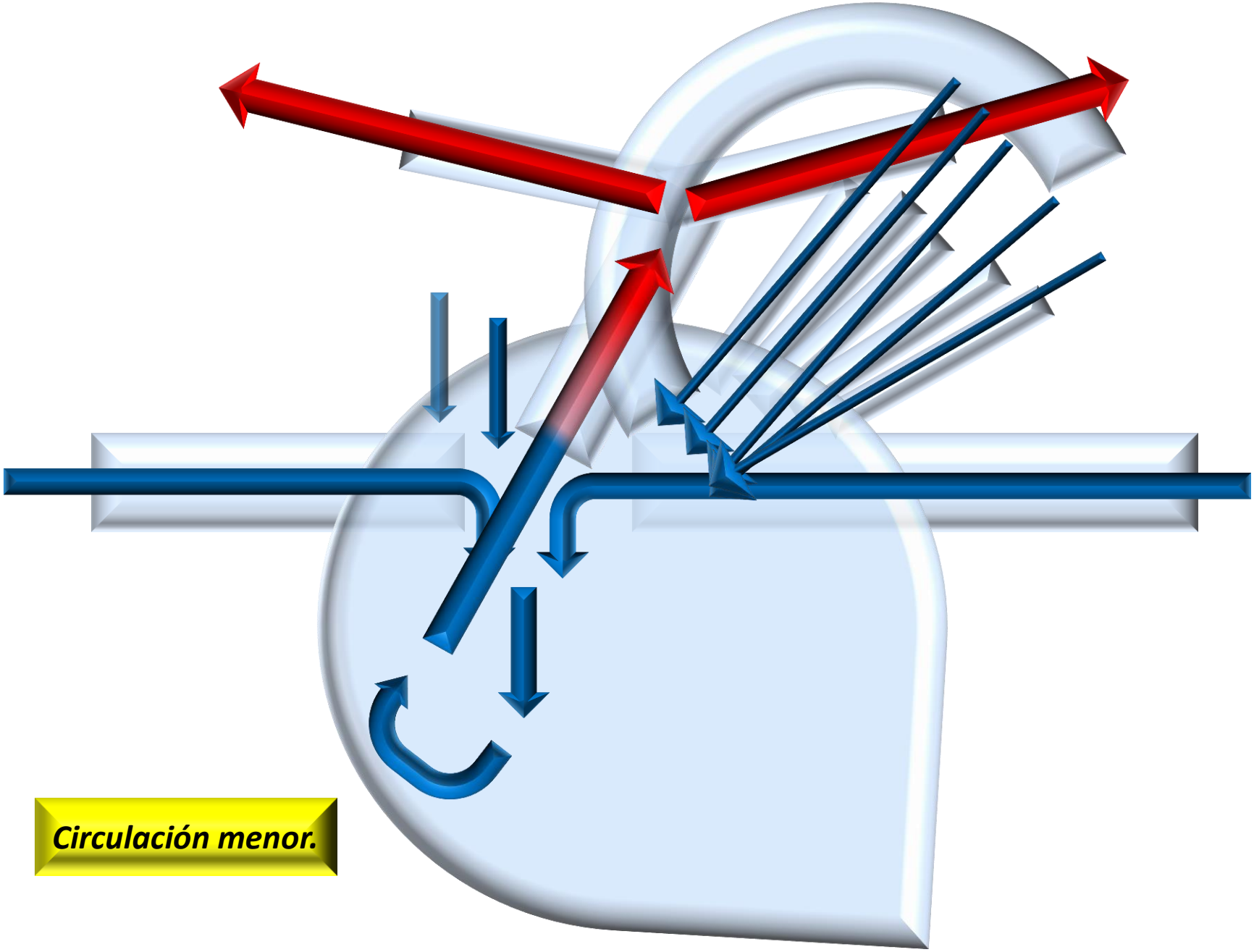

Sistema cardiovascular, corazón, fisioanatomía.

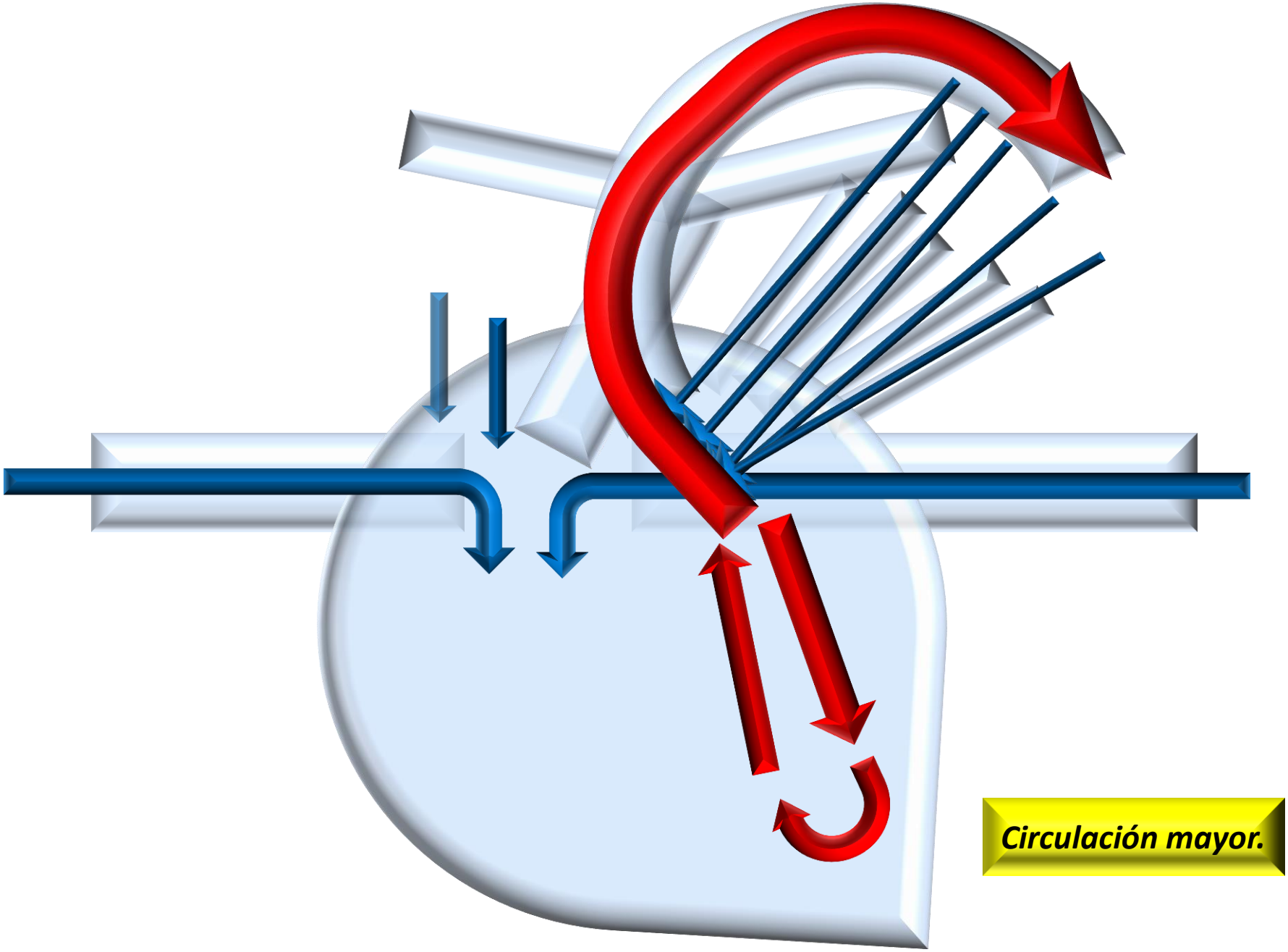

Sistema cardiovascular, corazón, fisioanatomía.

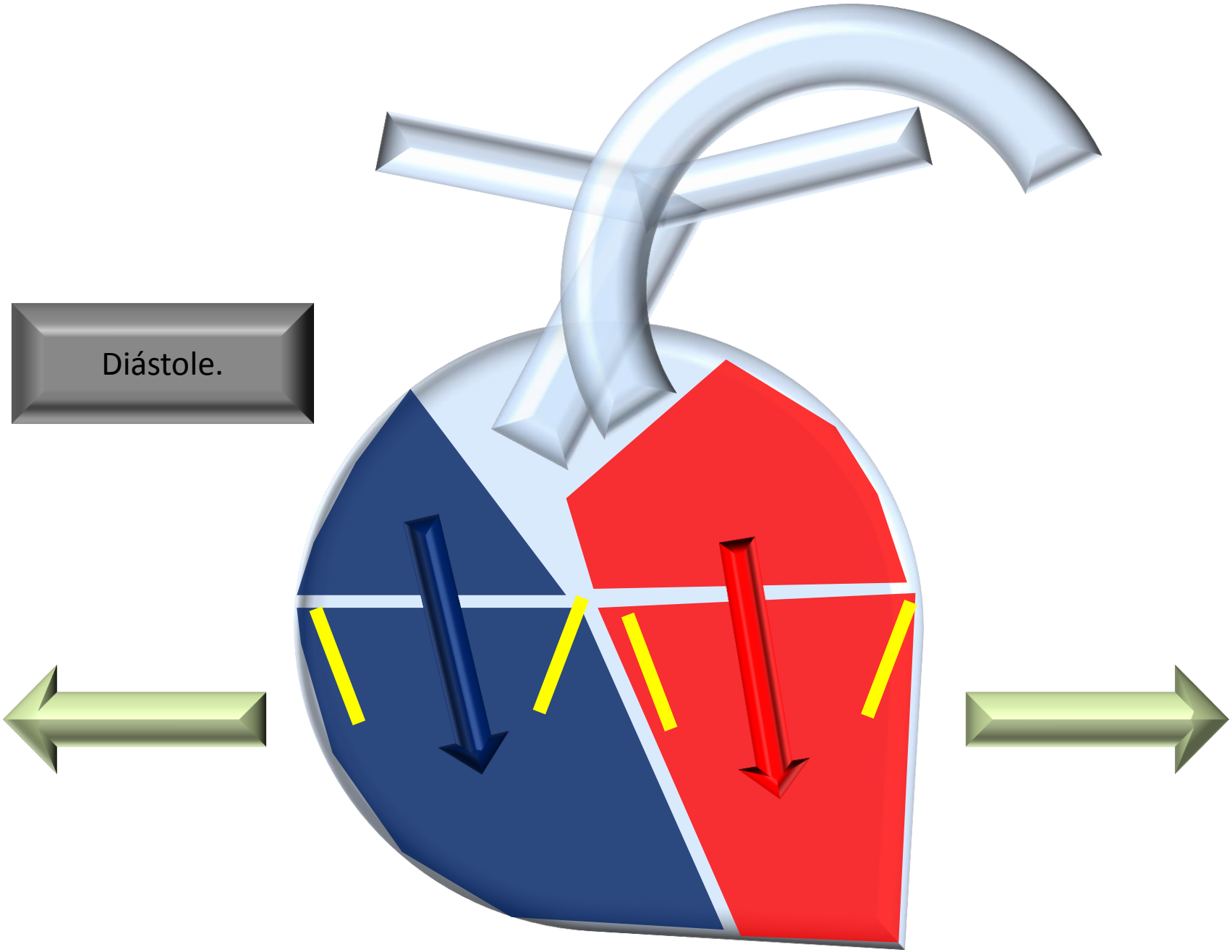

Sistema cardiovascular, corazón, fisioanatomía.

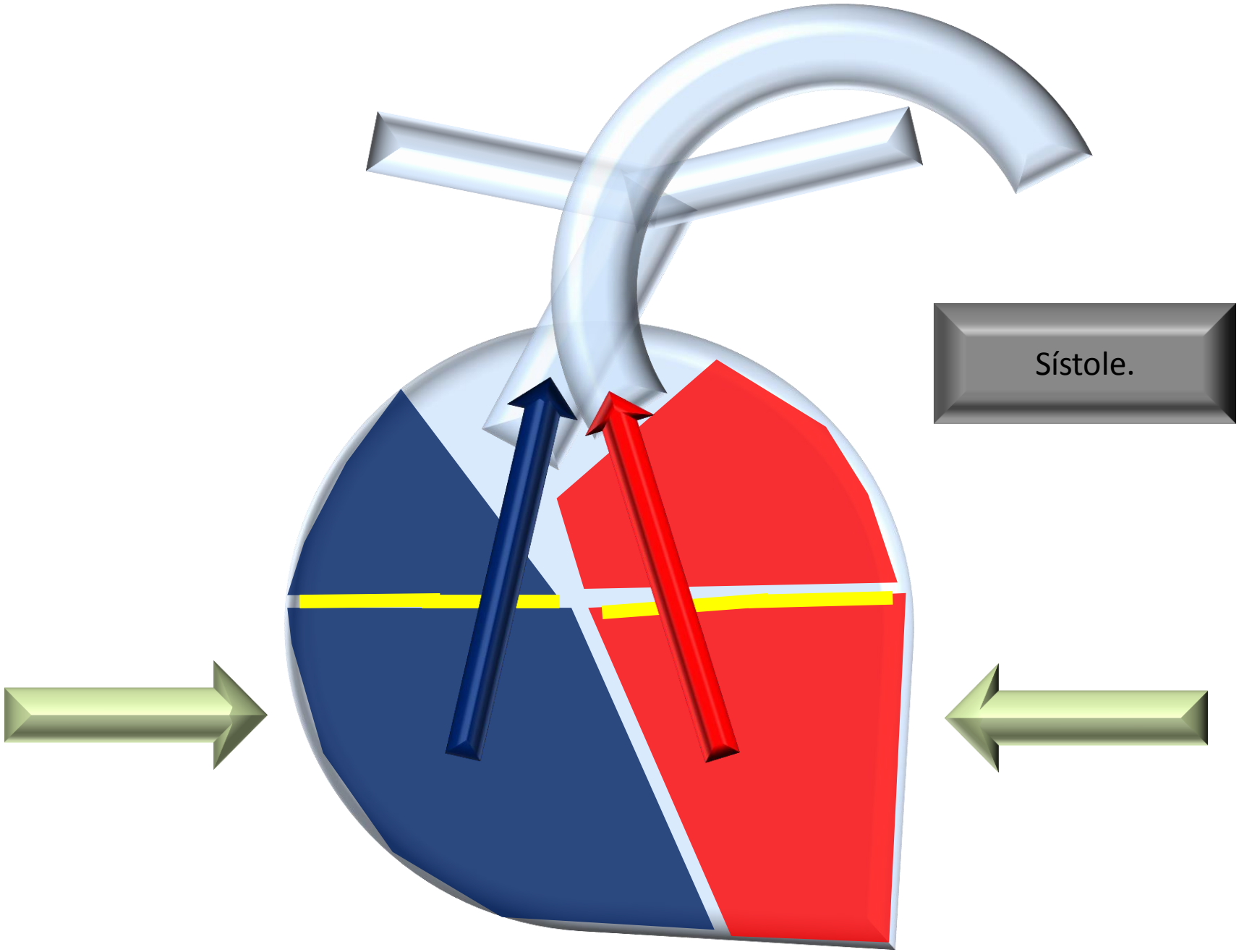

Sistema cardiovascular, corazón, fisioanatomía.

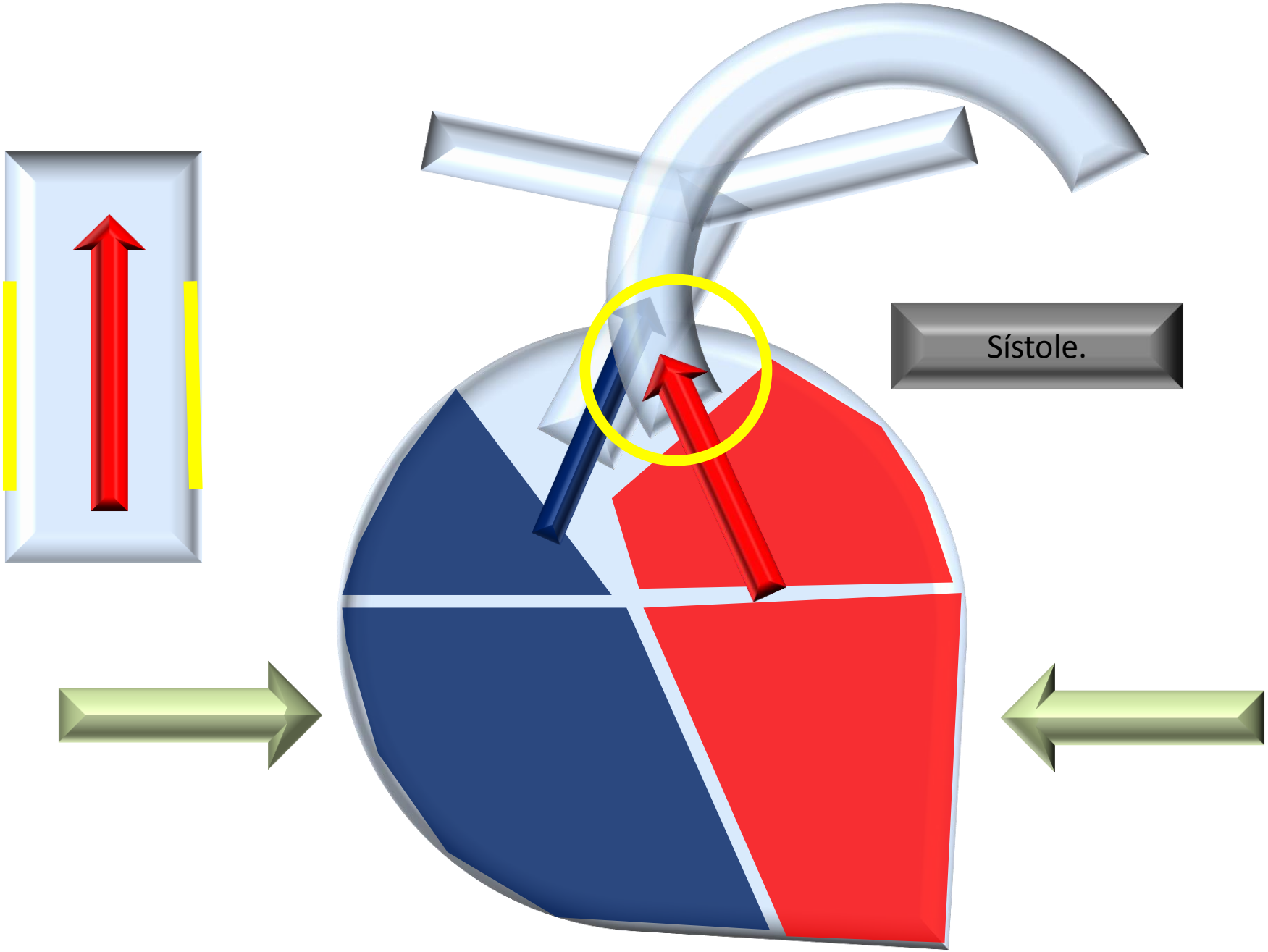

Sistema cardiovascular, corazón, fisioanatomía.

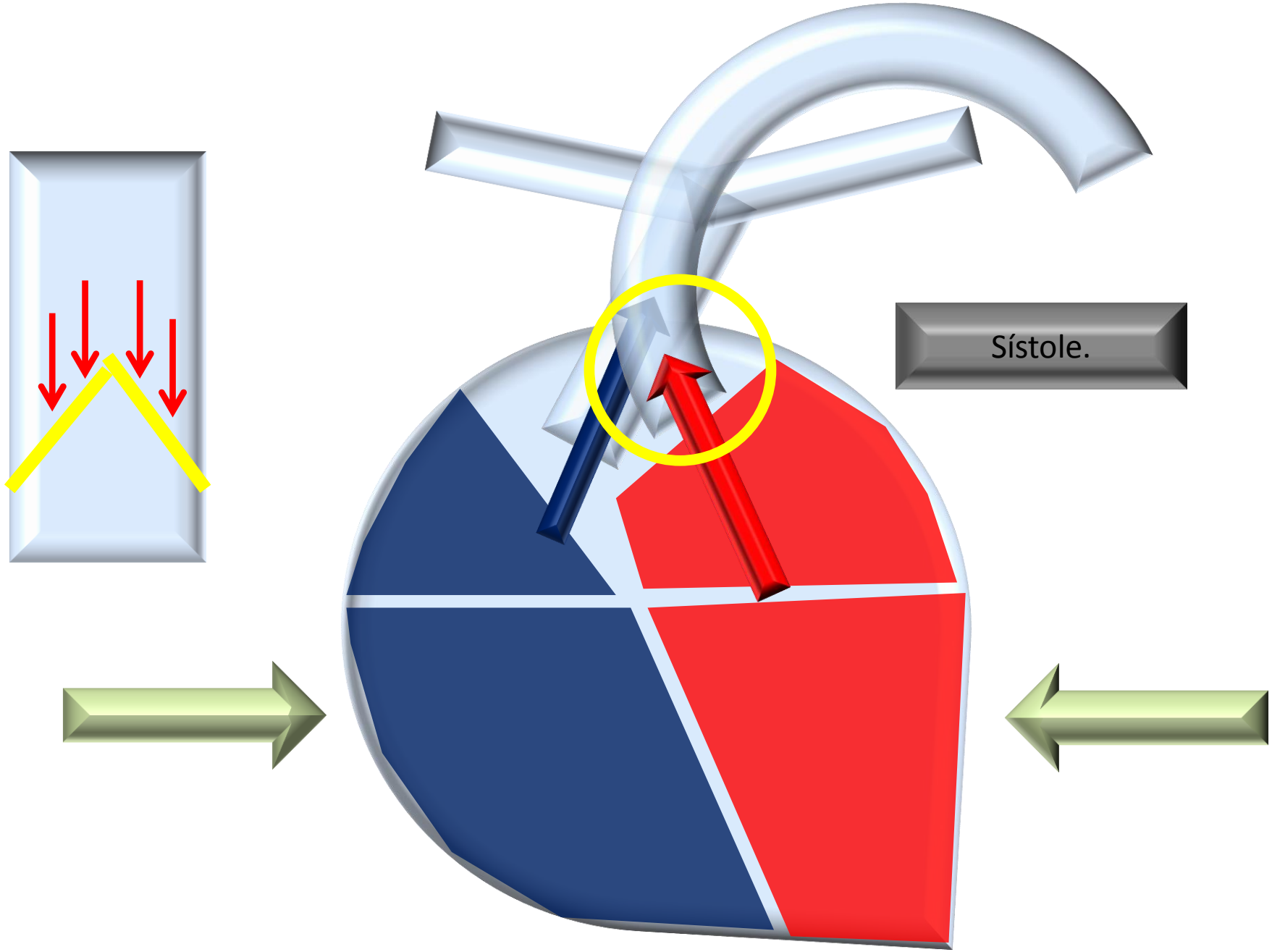

Sistema cardiovascular, irrigación de tórax, cuello y cabeza.

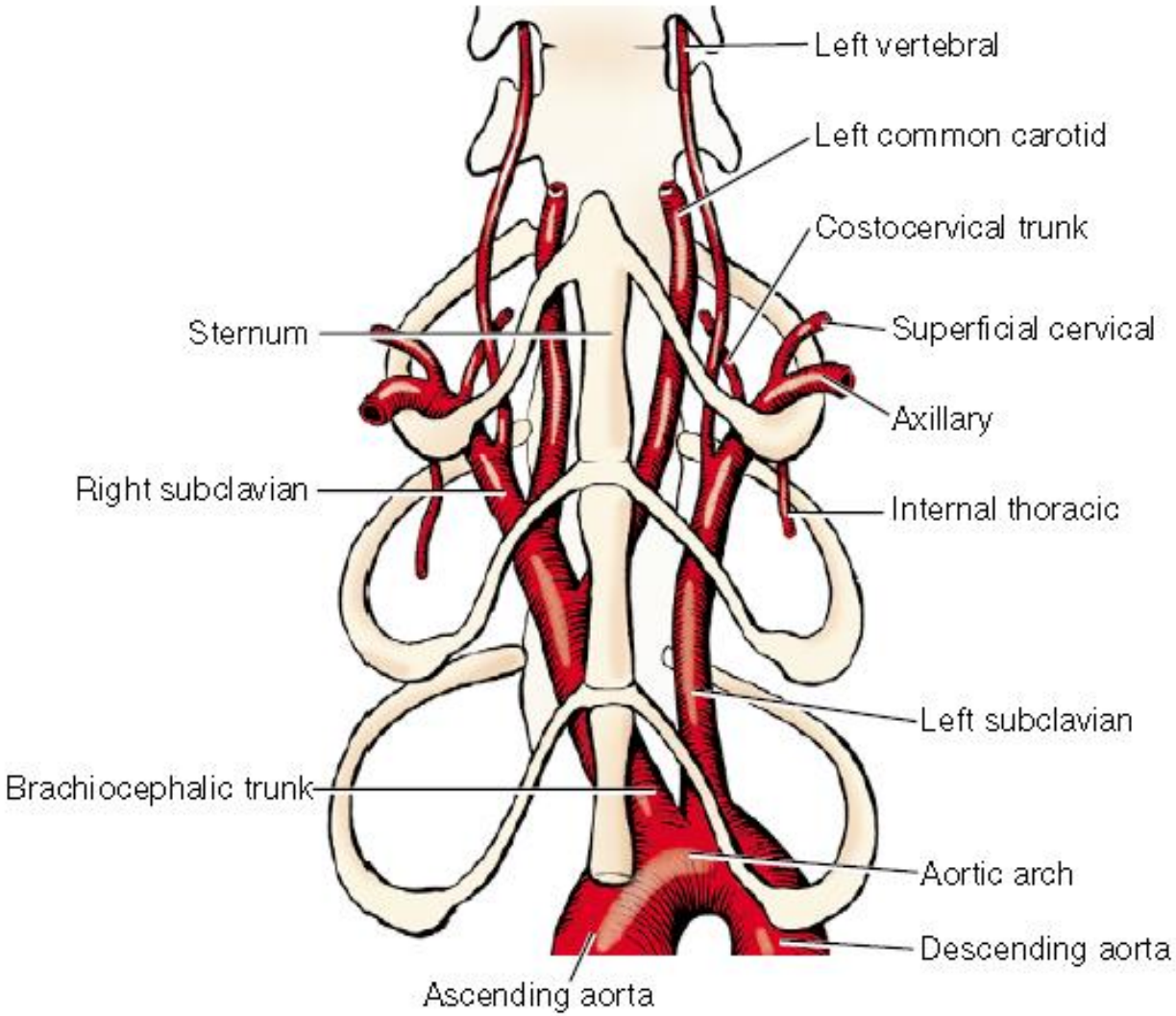

Fig. 3-18 Branches of aortic arch, ventral view.

Sistema cardiovascular, irrigación de tórax, cuello y cabeza.

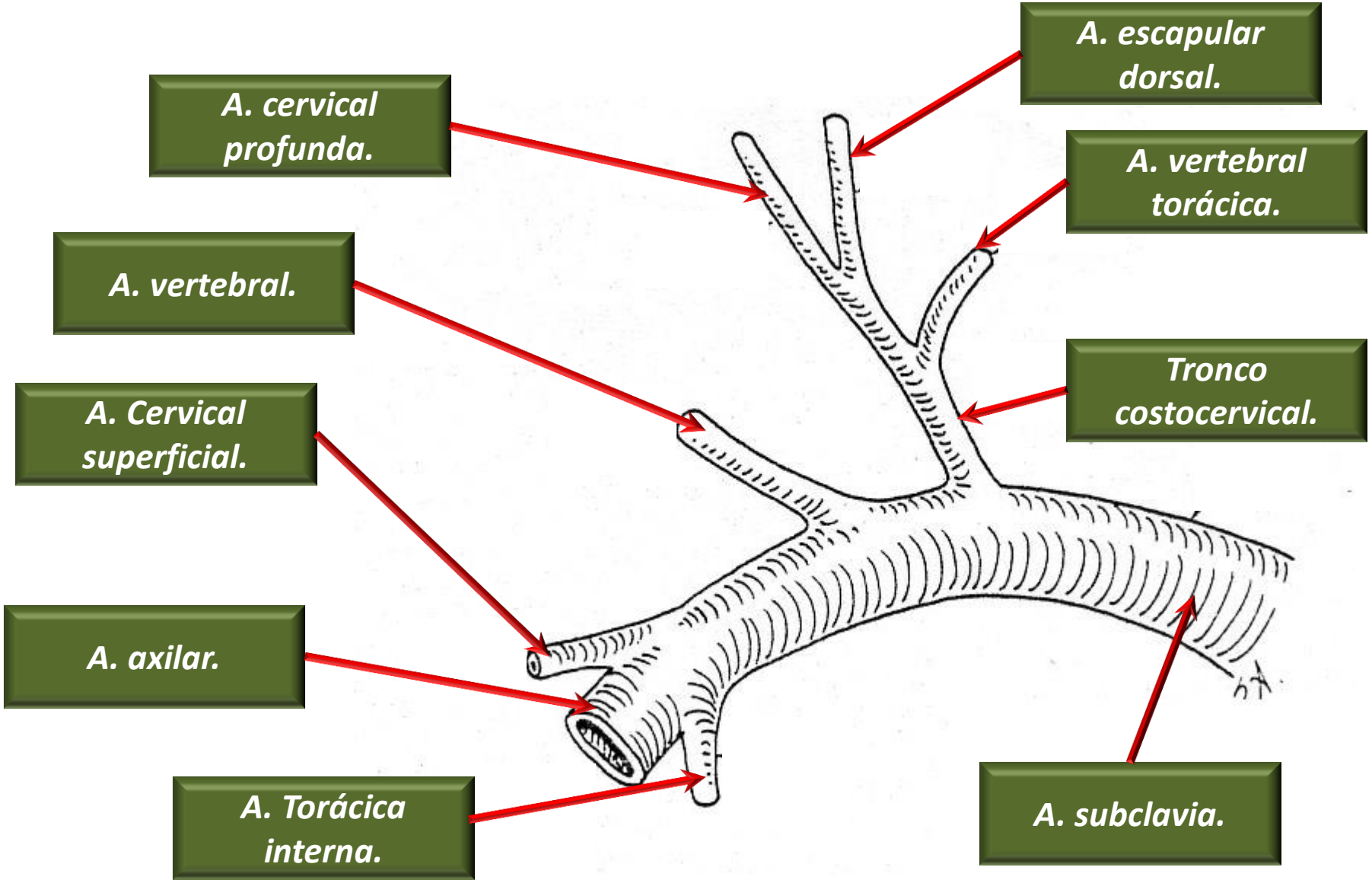

Sistema cardiovascular, irrigación de tórax, cuello y cabeza.

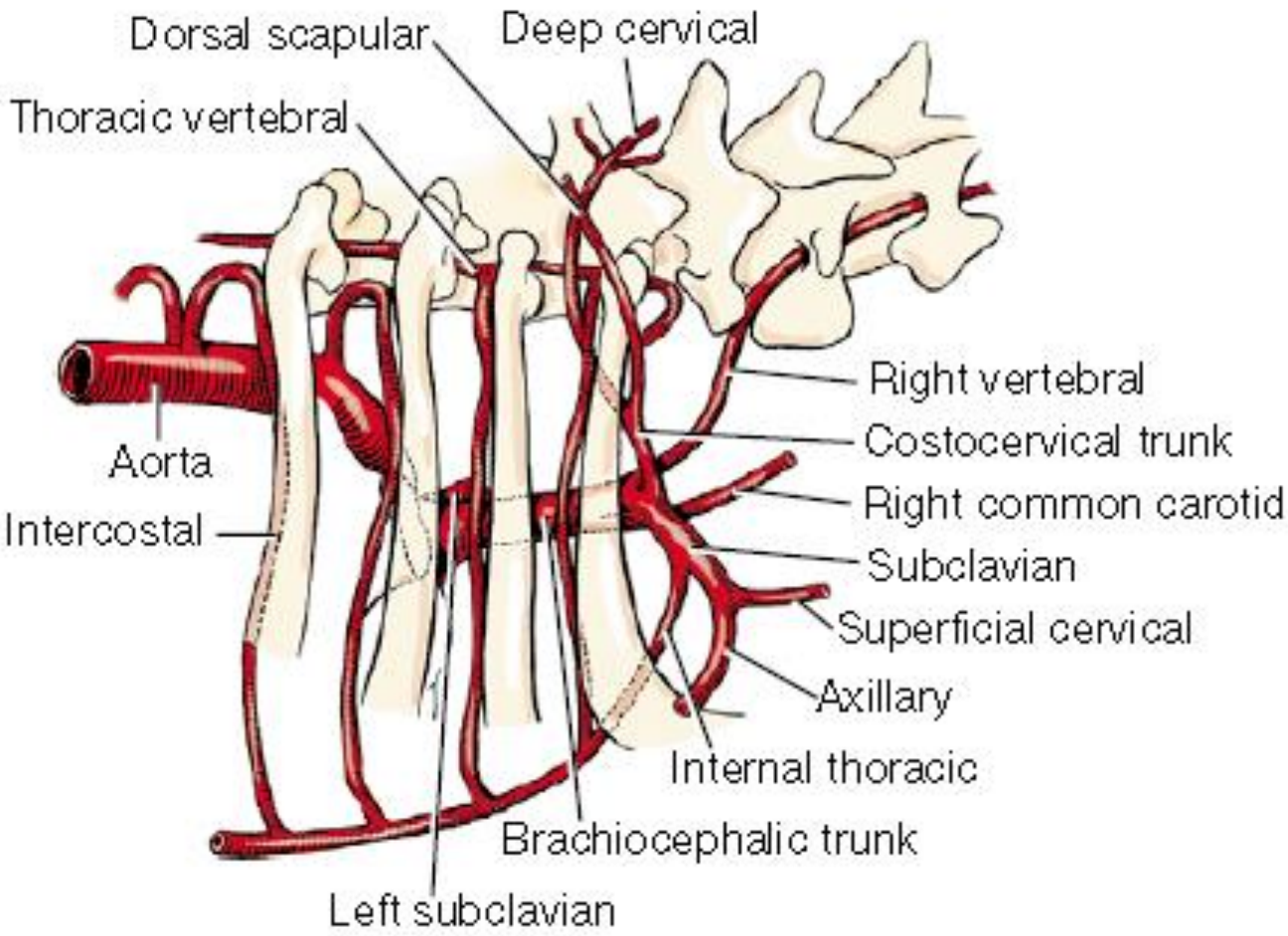

Fig. 3-19 Branches of brachiocephalic trunk, right lateral view.

Sistema cardiovascular, irrigación de tórax, cuello y cabeza.

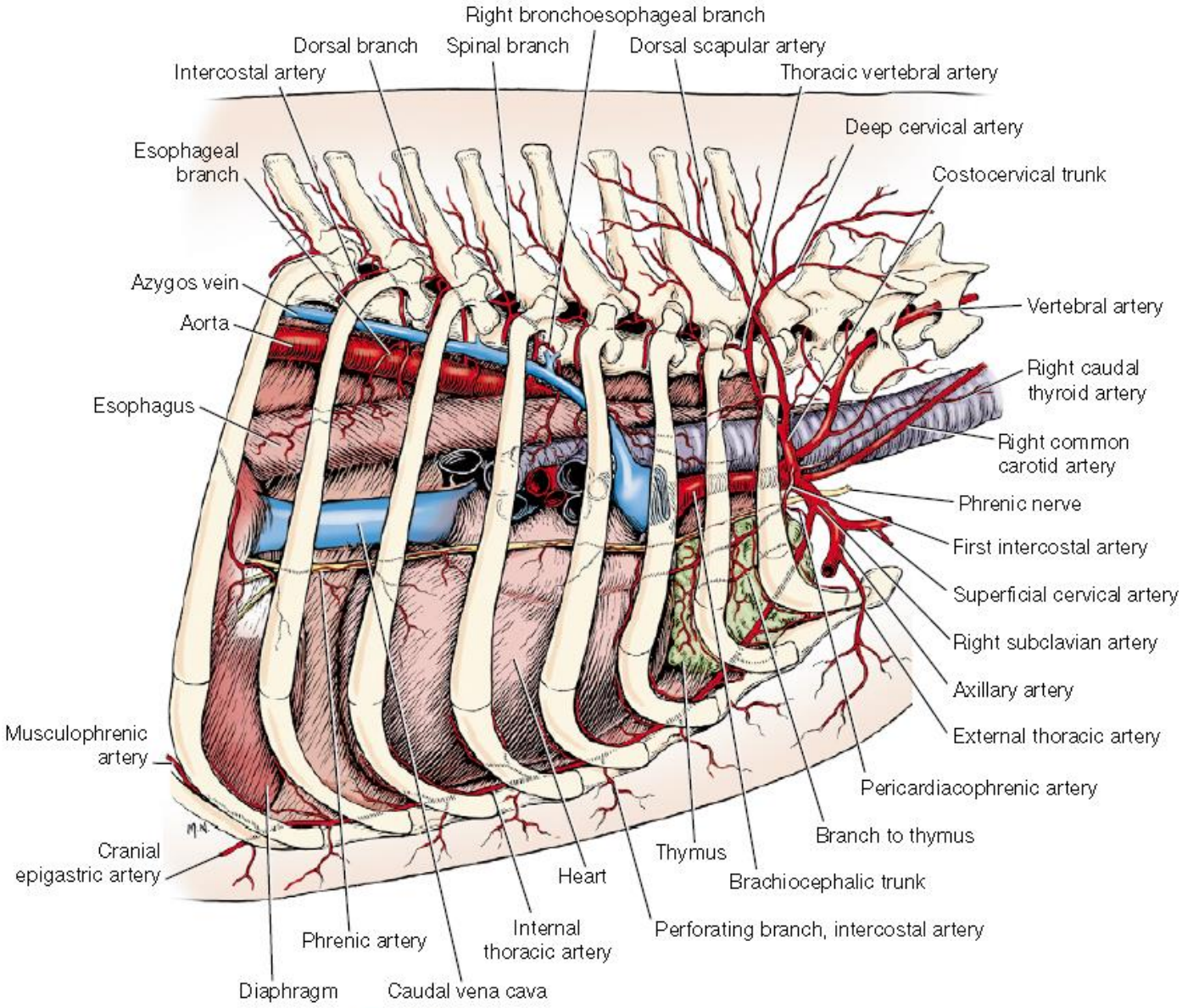

Fig. 3-14 Arteries of thorax, right lateral view.

Sistema cardiovascular, irrigación de tórax, cuello y cabeza.

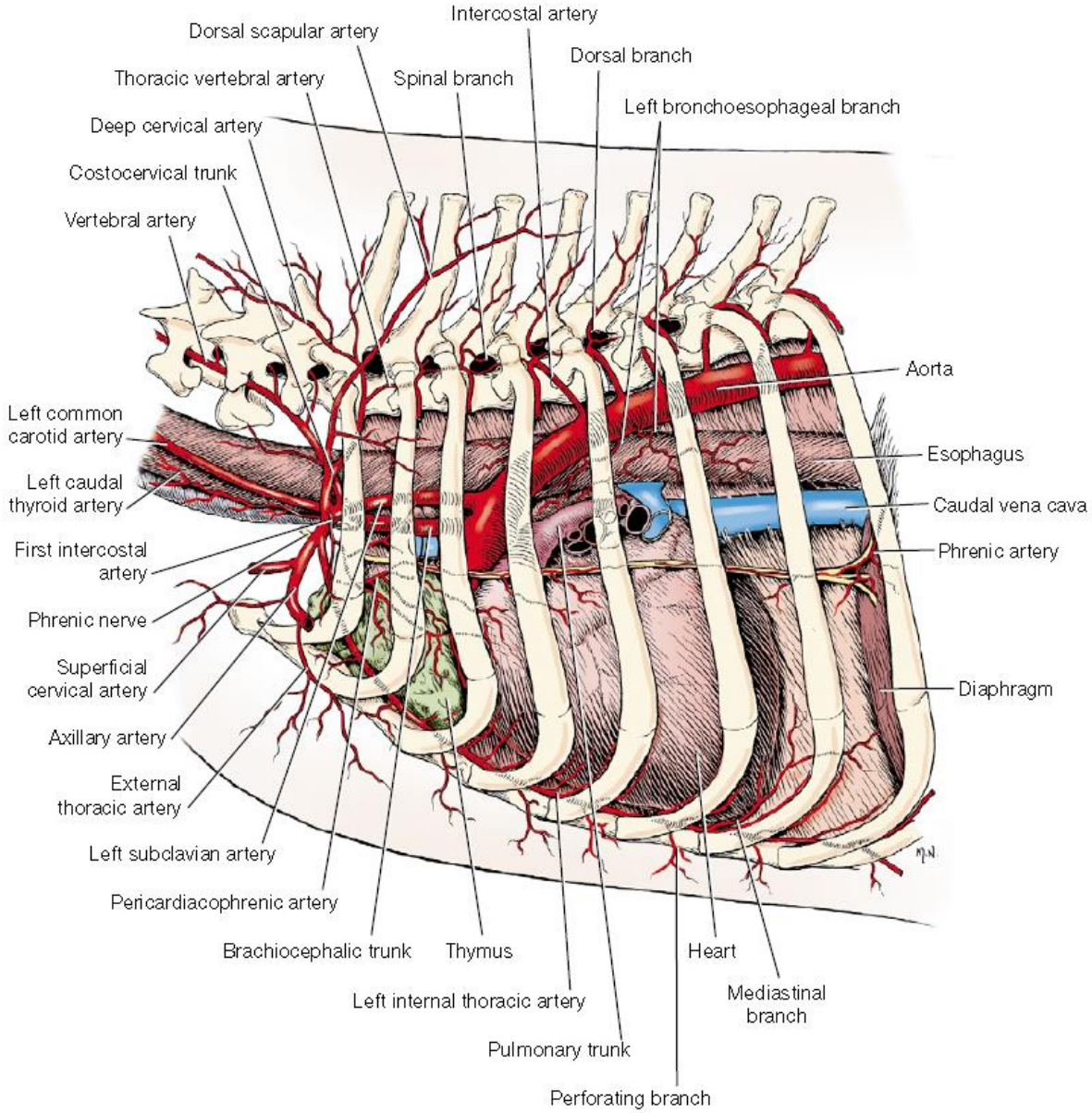

Fig. 3-16 Arteries of thorax, left lateral view.

Sistema cardiovascular, irrigación de tórax, cuello y cabeza.

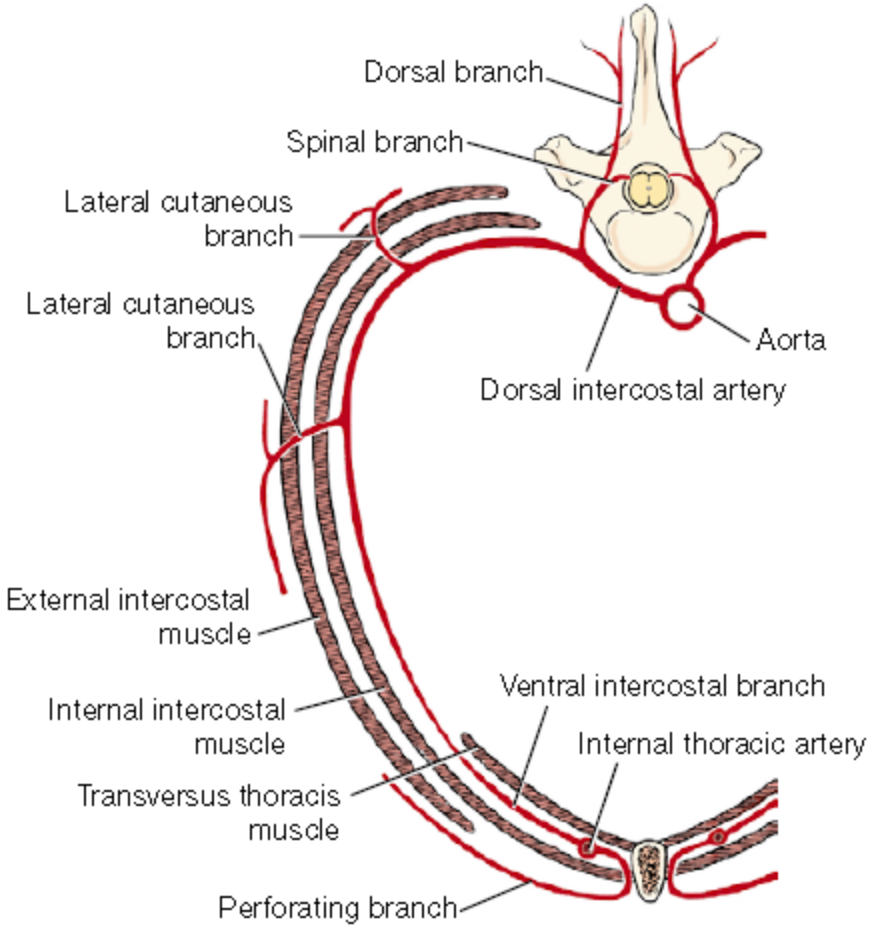

Fig. 3-4 Schematic transection of thoracic wall to show distribution of an intercostal artery.

Sistema cardiovascular, irrigación de tórax, cuello y cabeza.

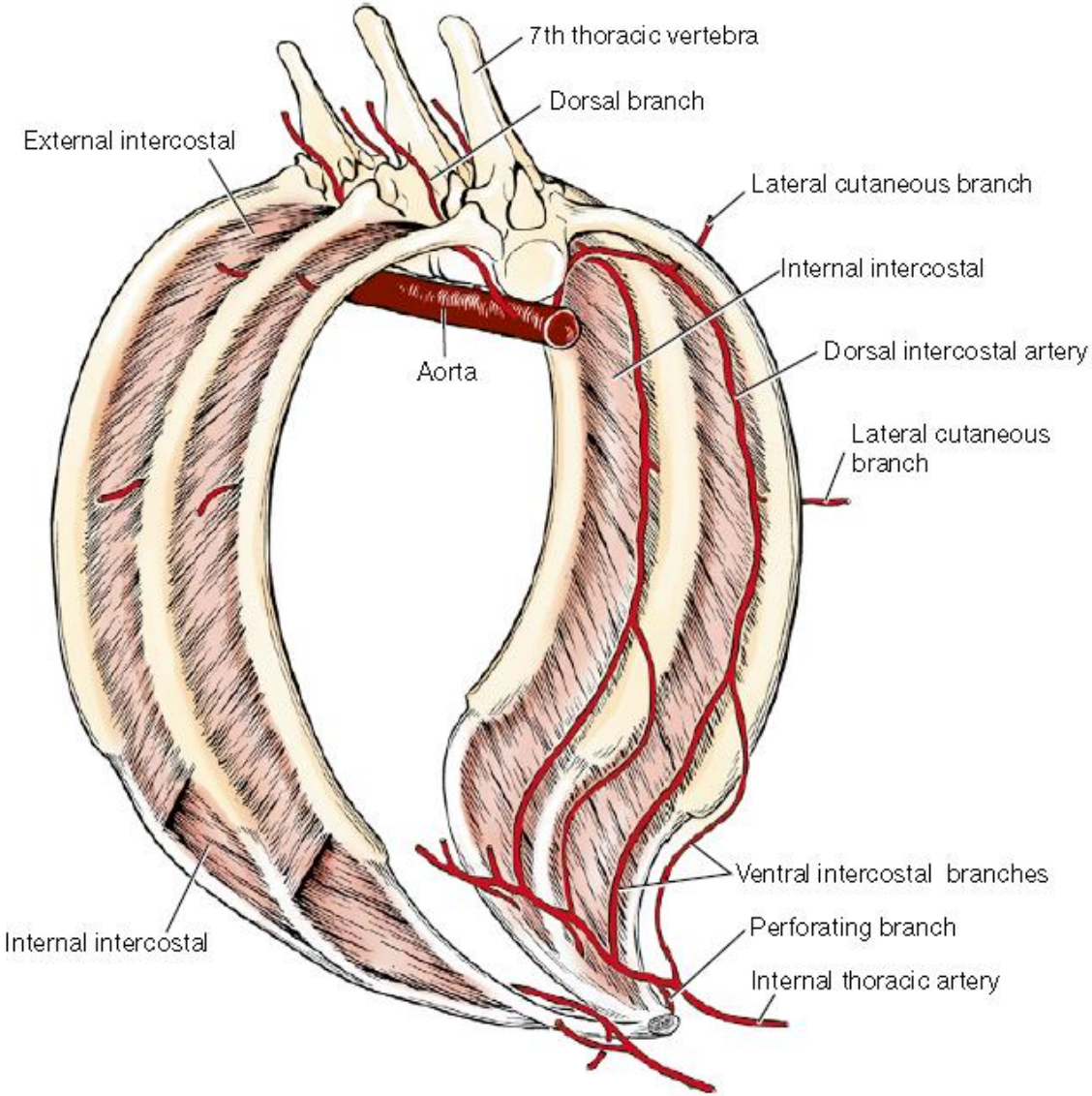

Fig. 3-5 Intercostal arteries as seen within rib cage.

Sistema cardiovascular, irrigación de tórax, cuello y cabeza.

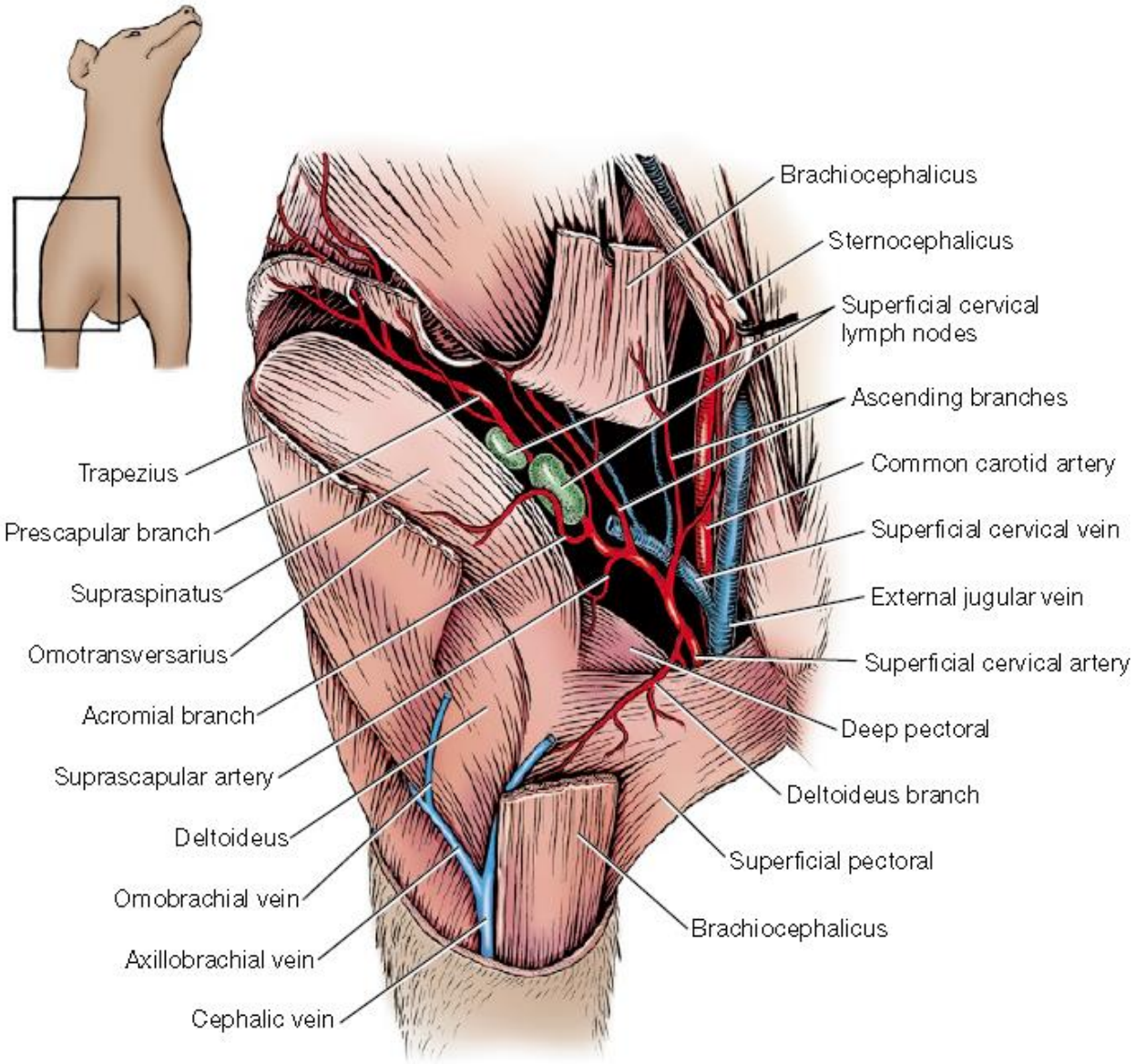

Fig. 3-26 Branches of superficial cervical artery.

Sistema cardiovascular, irrigación de tórax, cuello y cabeza.

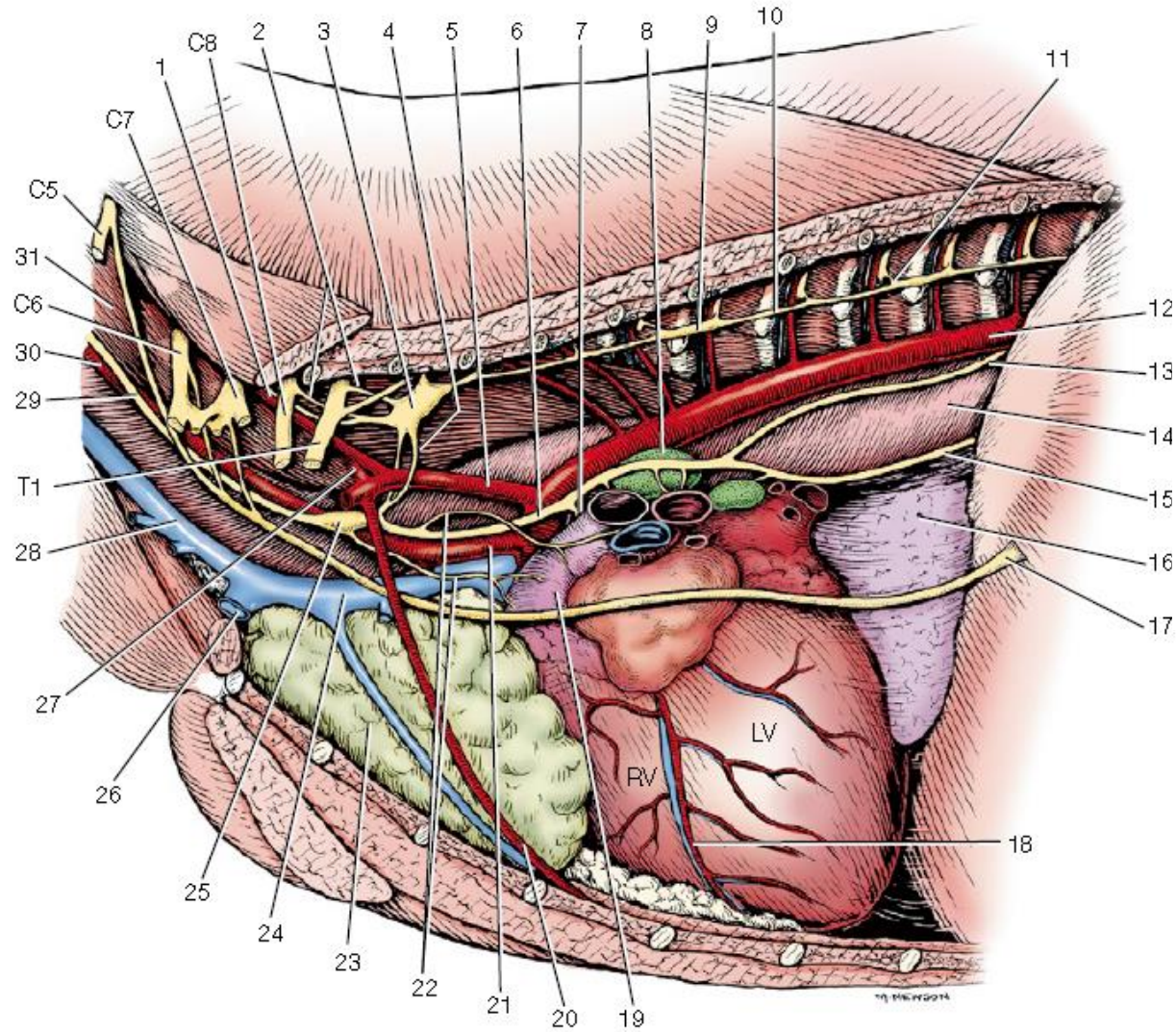

Timo.

Fig. 3-20 Thoracic autonomic nerves, left lateral view, lung removed.

1. Vertebral artery and nerve
2. Communicating rami from cervicothoracic ganglion to ventral branches of cervical and thoracic nerves
3. Left cervicothoracic ganglion
4. Ansa subclavia
5. Left subclavian artery
6. Left vagus nerve
7. Left recurrent laryngeal nerve
8. Left tracheobronchial lymph node
9. Sympathetic trunk ganglion
10. Sympathetic trunk
11. Ramus communicans
12. Aorta
13. Dorsal branch of vagus nerve
14. Esophagus
15. Ventral trunk of vagus nerve
16. Accessory lobe of lung (through caudal mediastinum)
17. Phrenic nerve to diaphragm
18. Paraconal interventricular a., v., and groove
19. Pulmonary trunk
20. Internal thoracic artery and vein
21. Brachiocephalic trunk
22. Cardiac autonomic nerves
23. Thymus
24. Cranial vena cava
25. Middle cervical ganglion
26. Left subclavian vein
27. Costocervical trunk
28. External jugular vein
29. Vagosympathetic trunk
30. Common carotid artery
31. Longus colli muscle

Sistema cardiovascular, irrigación de tórax, cuello y cabeza.

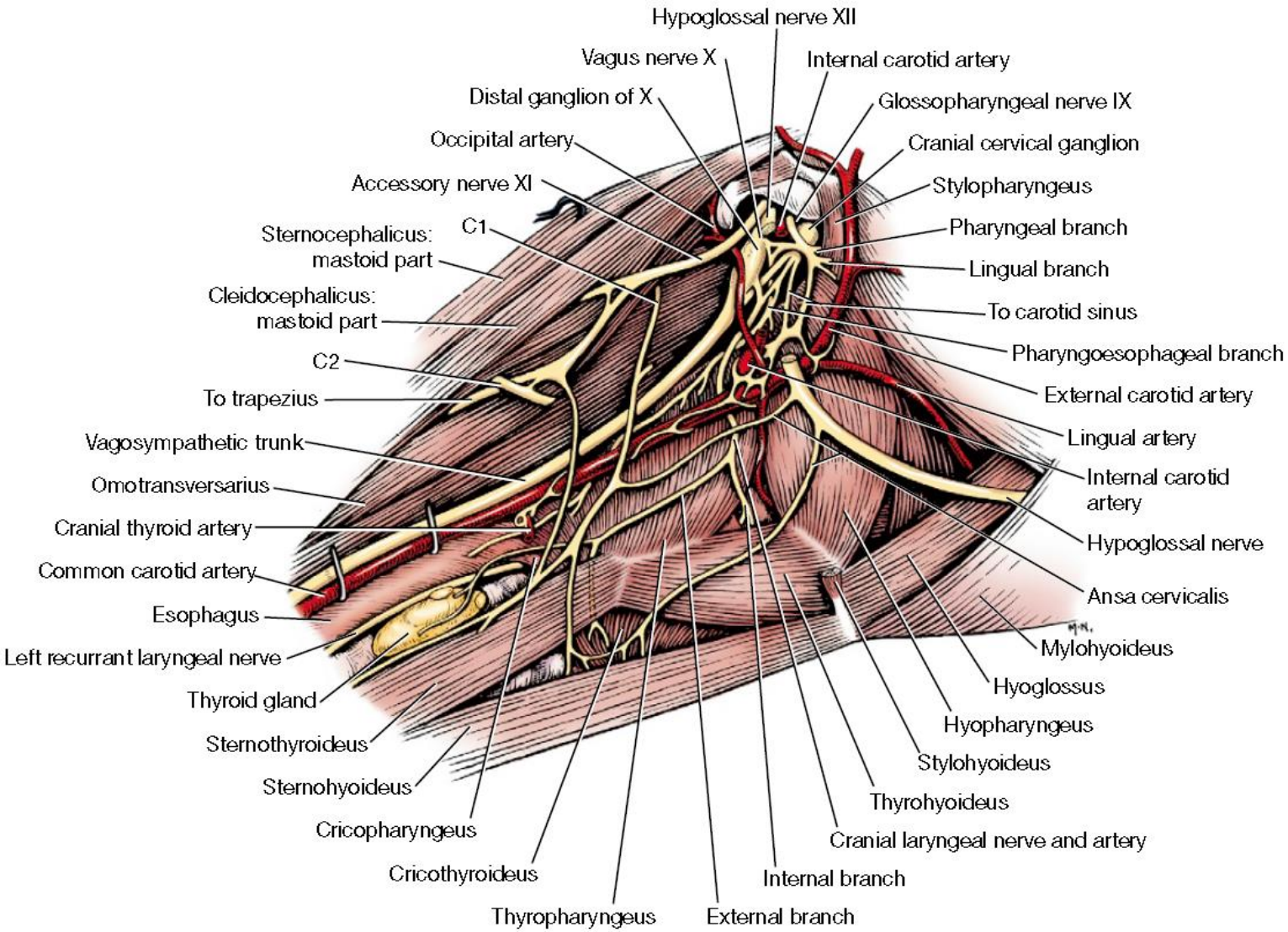

Fig. 5-52 Nerves emerging from tympano-occipital fissure, right lateral view. The digastricus muscle and the medial retropharyngeal lymph node were removed.

Sistema cardiovascular, irrigación de tórax, cuello y cabeza.

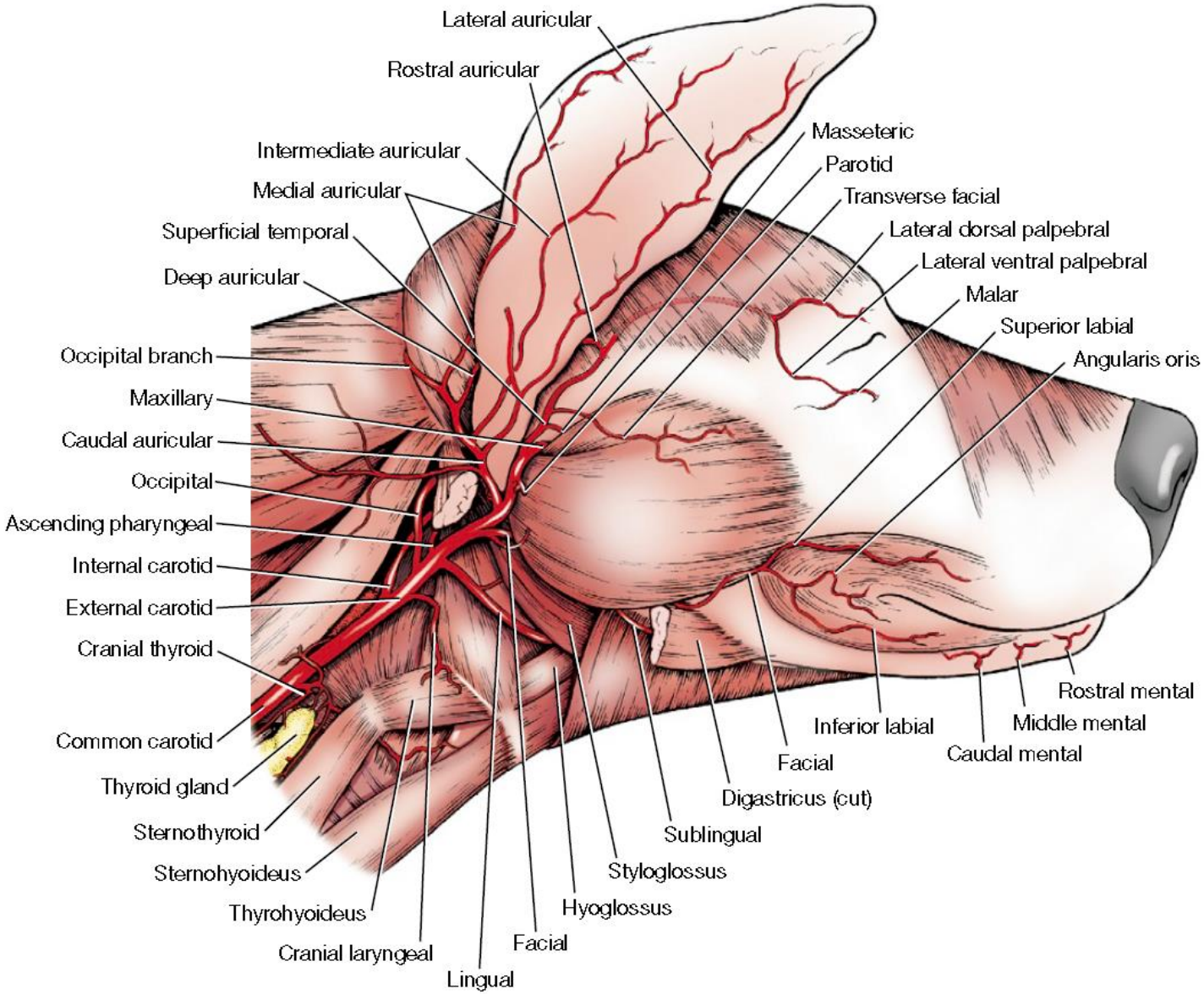

Fig. 5-43 Branches of common carotid artery, superficial lateral view, part of digastricus removed.

Sistema cardiovascular, irrigación de tórax, cuello y cabeza.

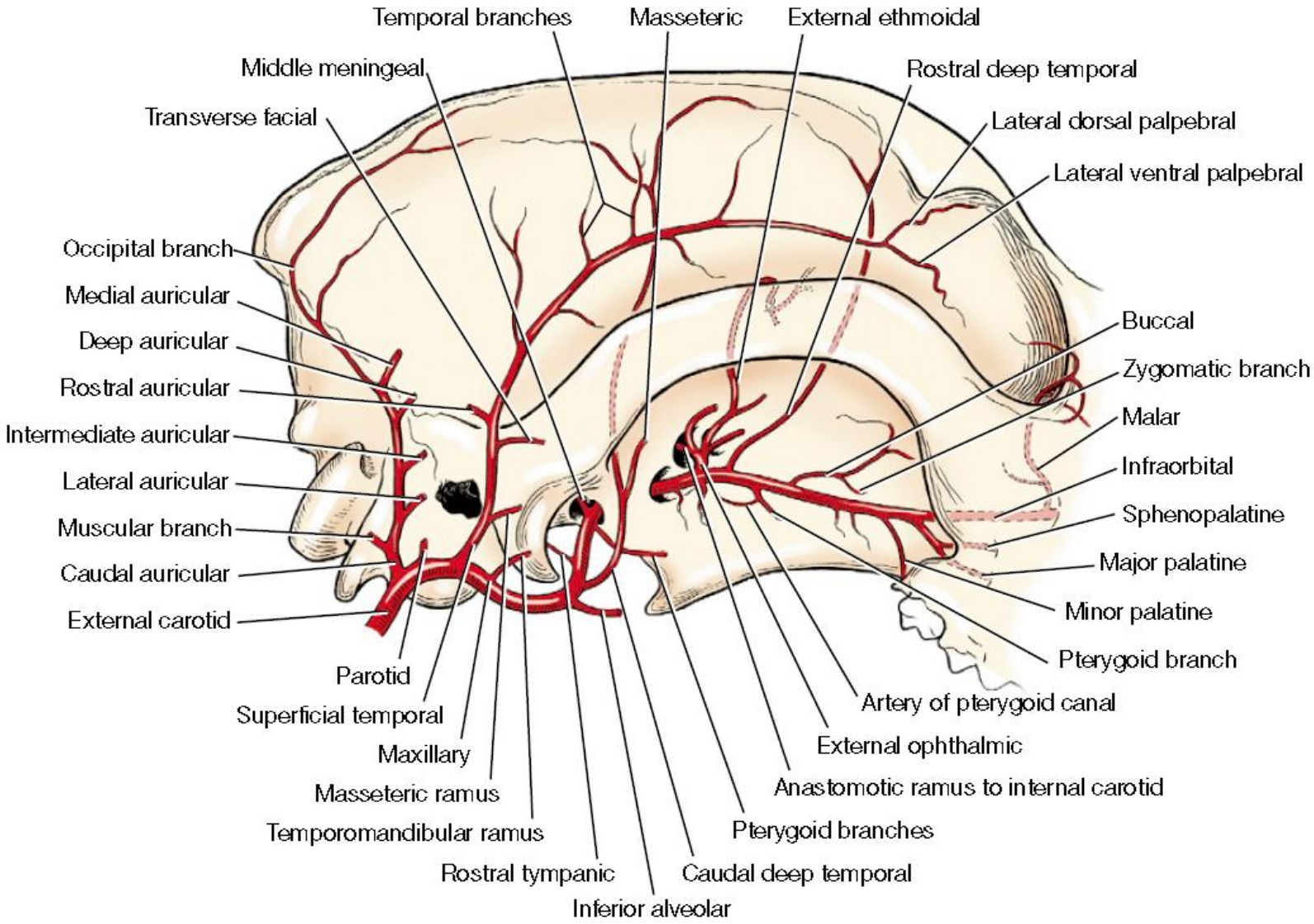

Fig. 5-44 Arteries of head in relation to lateral aspect of skull.

Sistema cardiovascular, irrigación de tórax, cuello y cabeza.

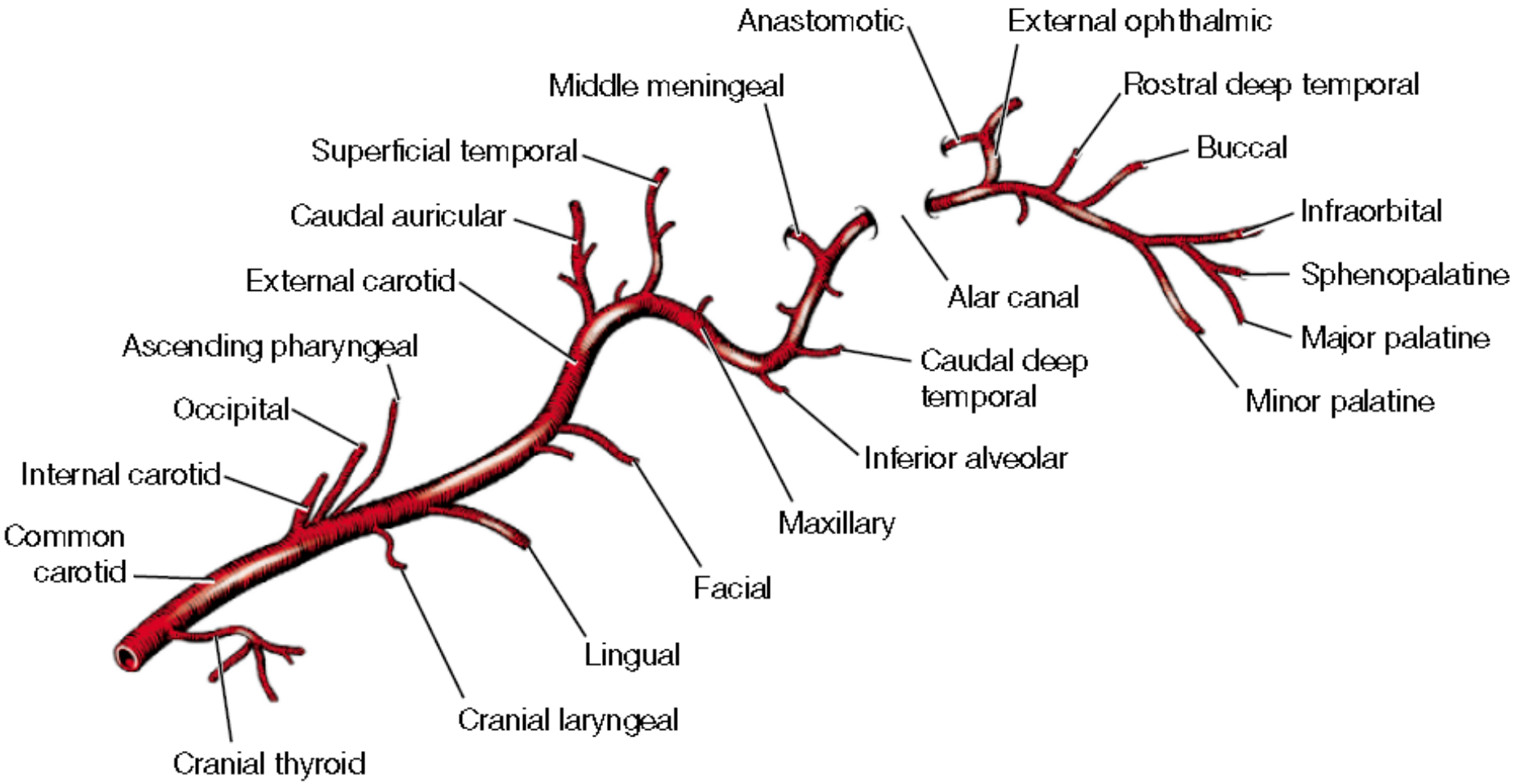

Fig. 5-45 Branches of right common carotid artery, deep view.

Sistema cardiovascular, irrigación de tórax, cuello y cabeza.

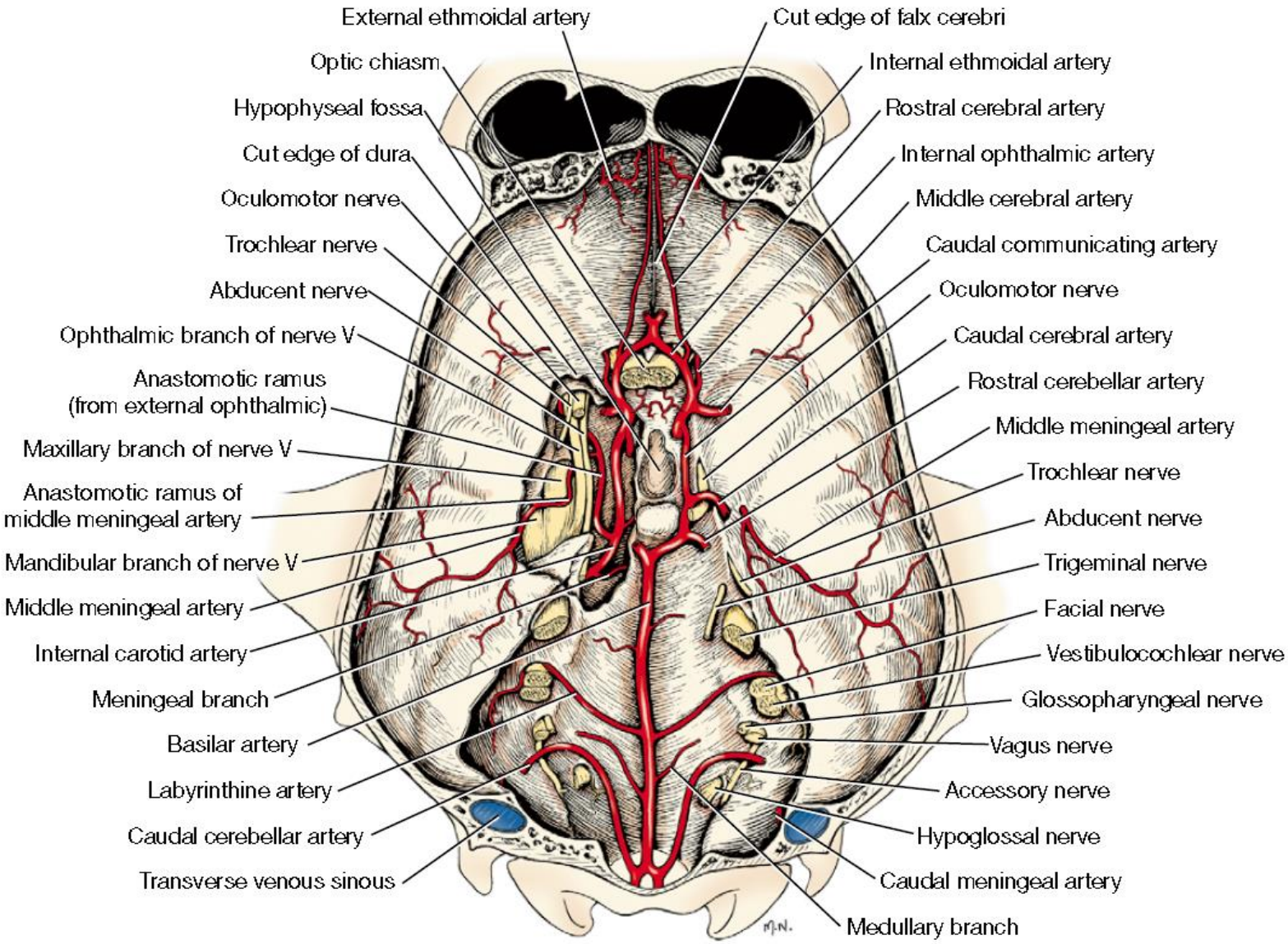

Fig. 5-50 Dorsal aspect of base of the skull showing arteries and nerves.

Sistema cardiovascular, irrigación de tórax, cuello y cabeza.

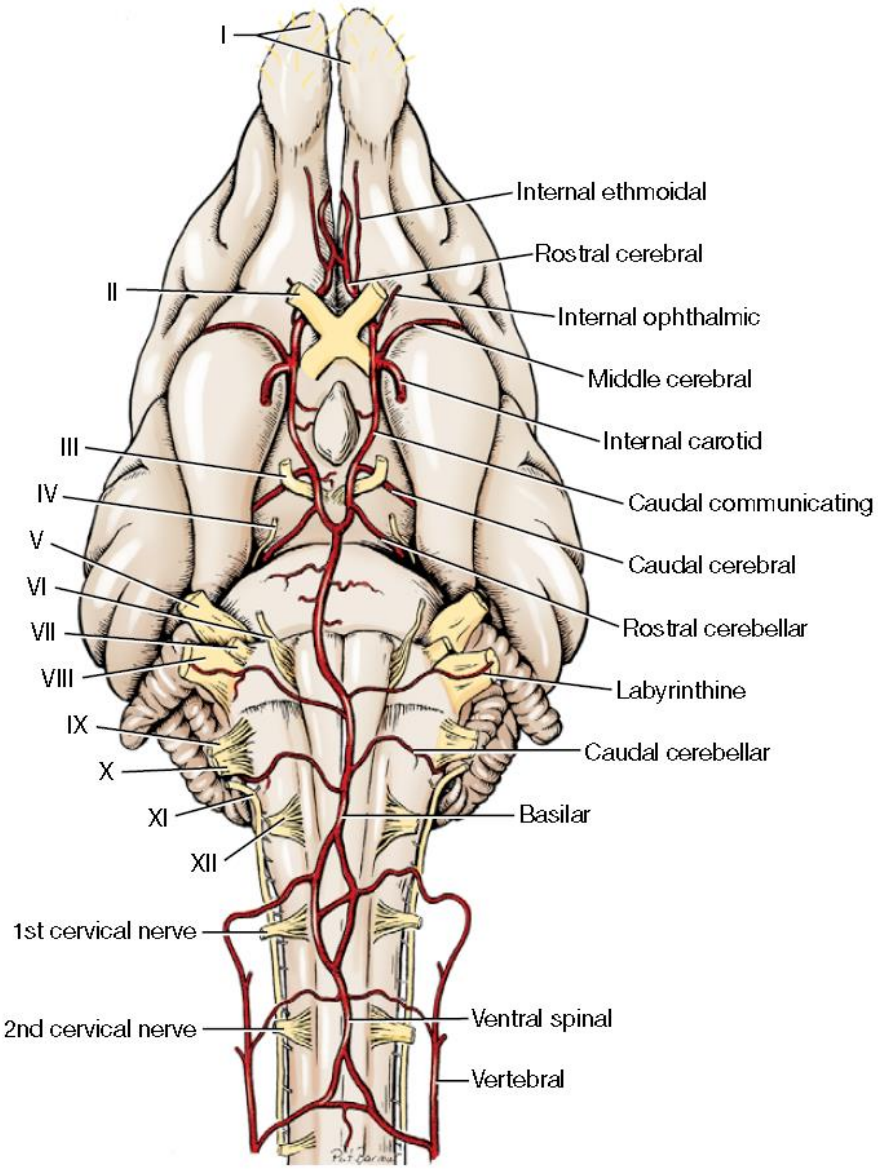

Fig. 5-51 Vessels and nerves of brain and first two cervical spinal cord segments, ventral view.

Sistema cardiovascular, irrigación de tórax, cuello y cabeza.

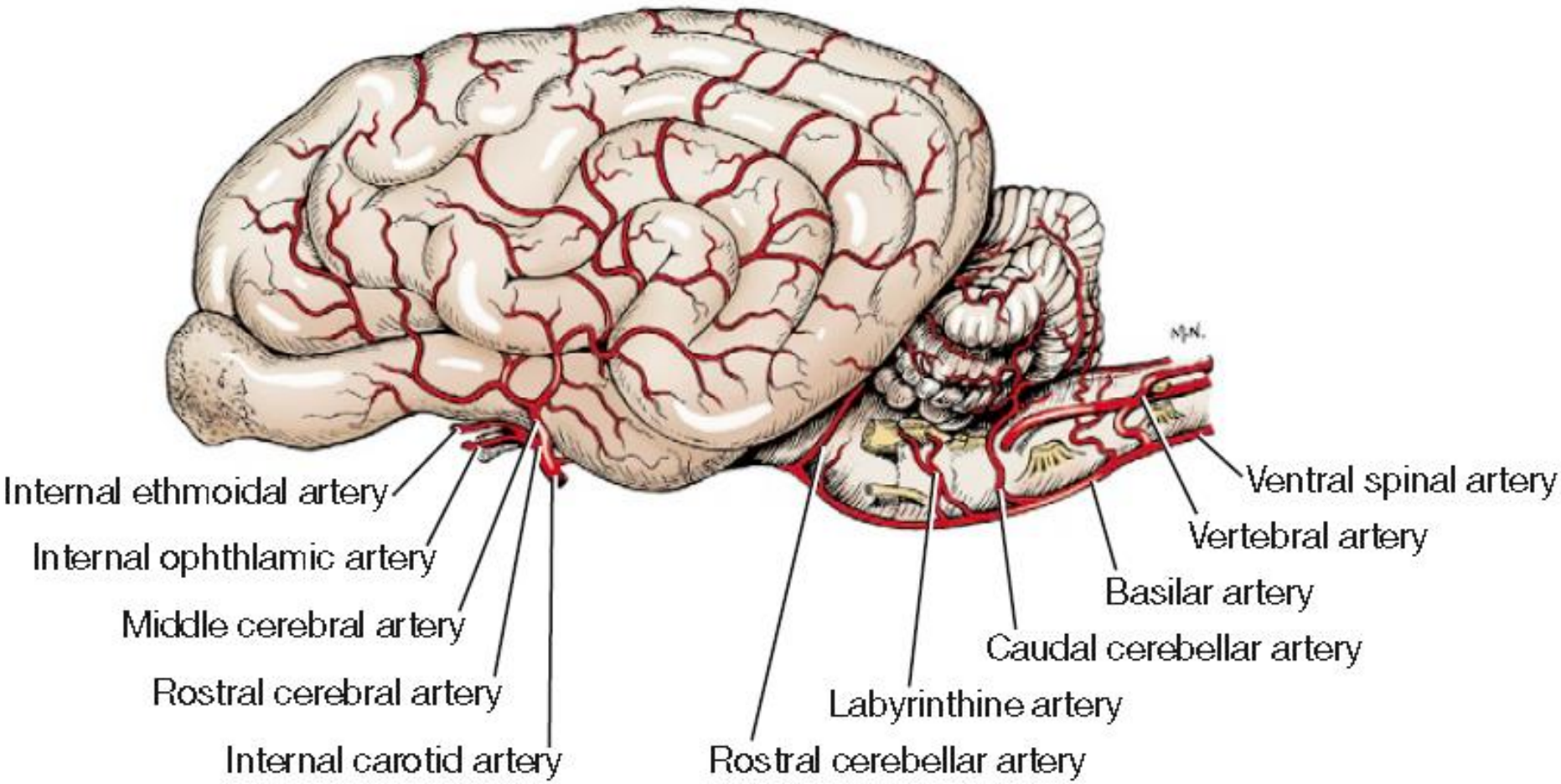

Fig. 6-2 Distribution of middle cerebral artery, lateral aspect.

Sistema cardiovascular, irrigación de tórax, cuello y cabeza.

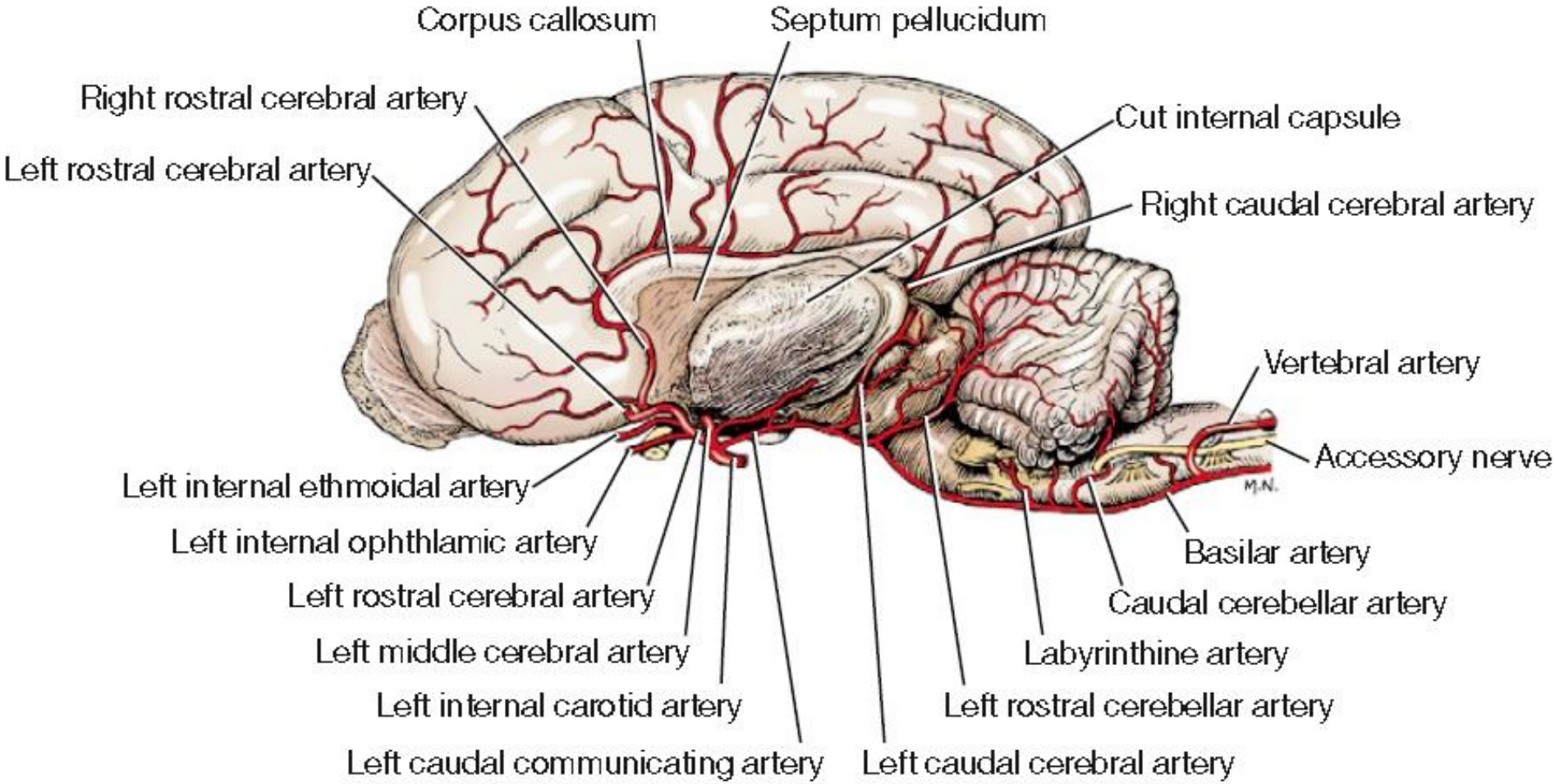

Fig. 6-3 Arteries of cerebellum and medial surface of cerebrum.

Sistema cardiovascular, drenaje venoso de tórax, cuello y cabeza.

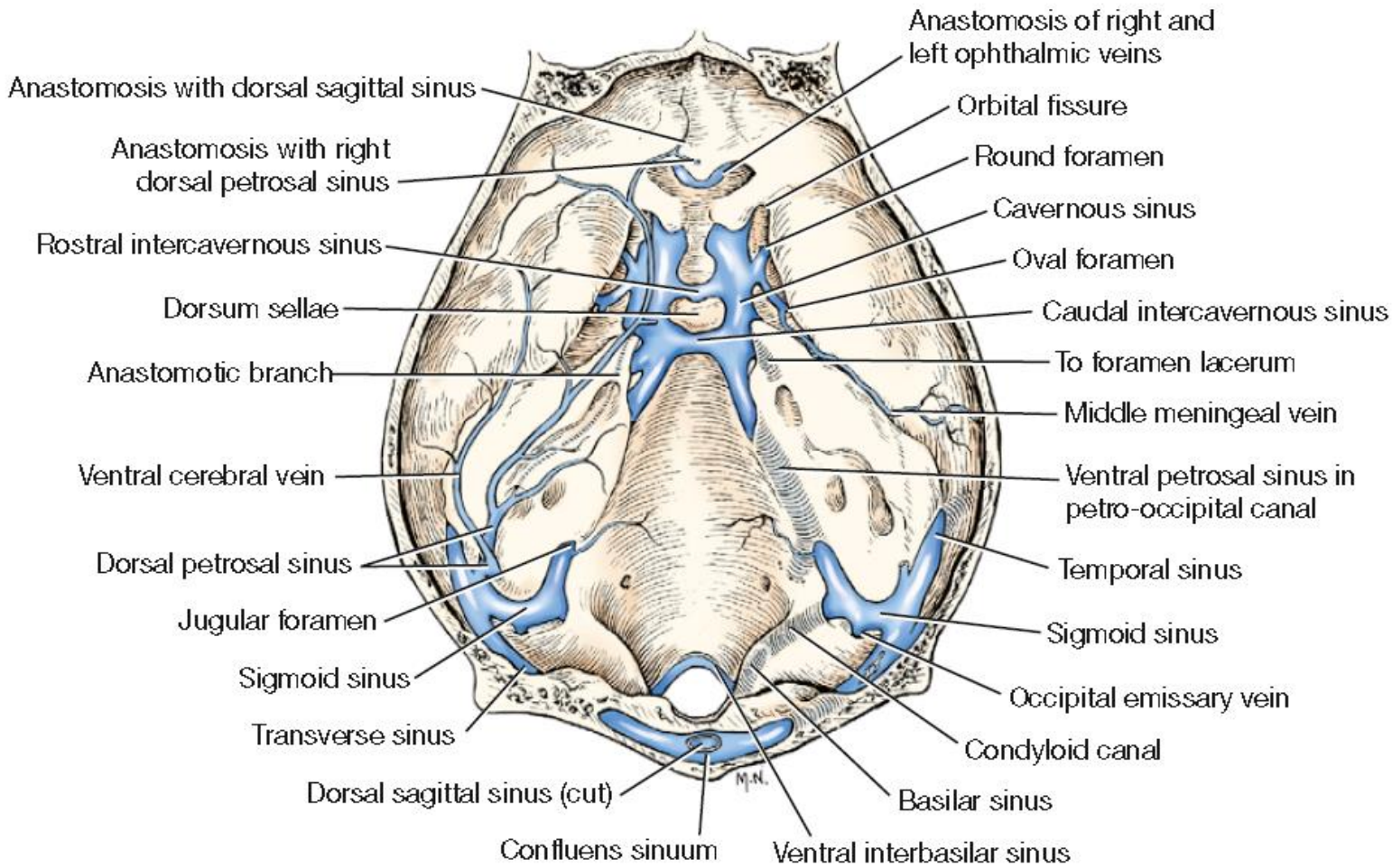

Fig. 6-6 Cranial venous sinuses, dorsal aspect, calvaria removed. (From Reinhard K, Miller M, Evans H: The craniovertebral veins and sinuses of the dog, *Am J Anat* 11:67-87, 1962.)

Sistema cardiovascular, drenaje venoso de tórax, cuello y cabeza.

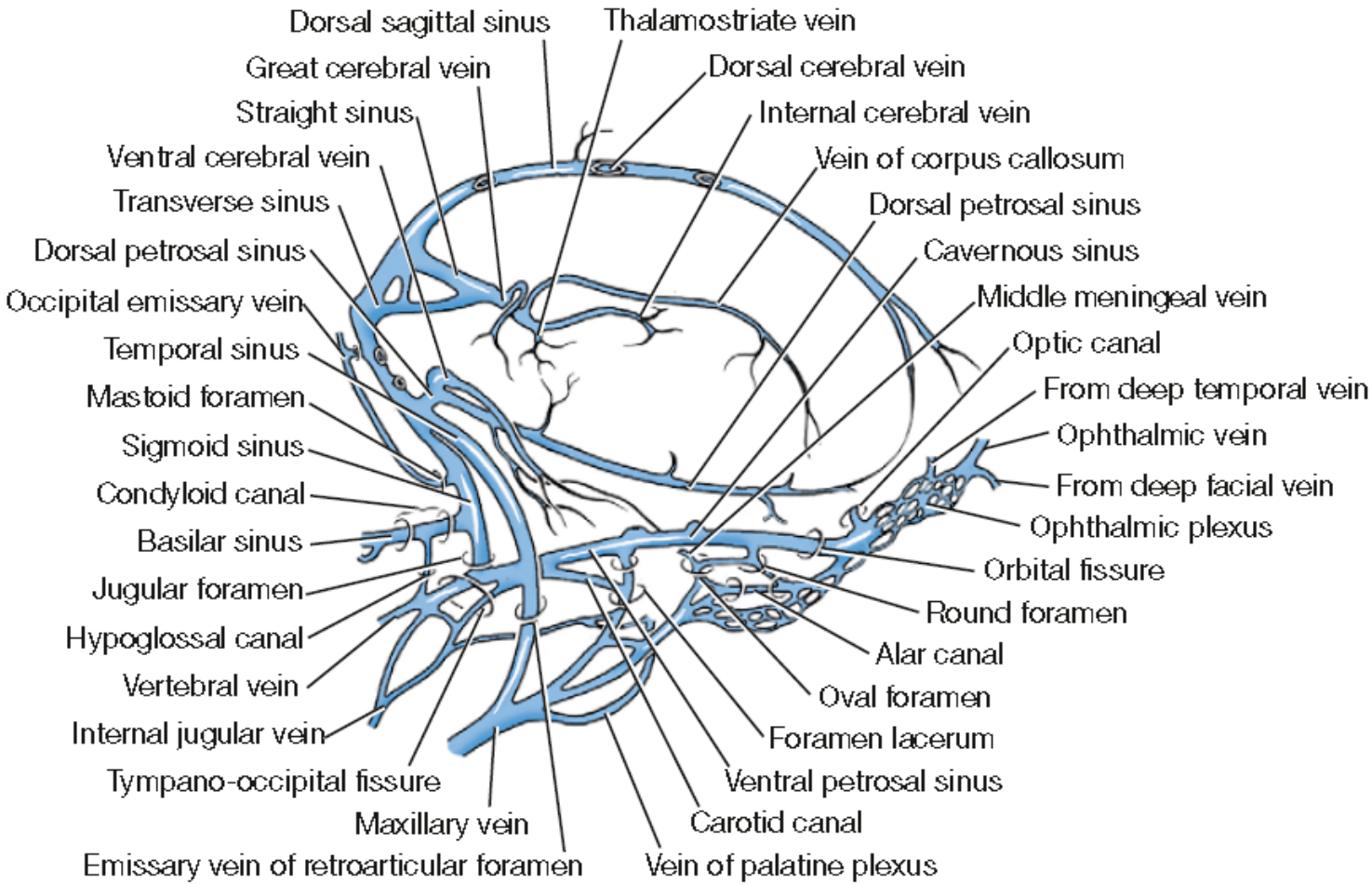

Fig. 6-5 Cranial venous sinuses, right lateral aspect. (From Reinhard K, Miller M, Evans H: The craniovertebral veins and sinuses of the dog, *Am J Anat* 11:67-87, 1962. Copyright © 1962 Wiley-Liss. Reprinted by permission of Wiley-Liss, Inc., a subsidiary of John Wiley & Sons, Inc.)

Sistema cardiovascular, drenaje venoso de tórax, cuello y cabeza.

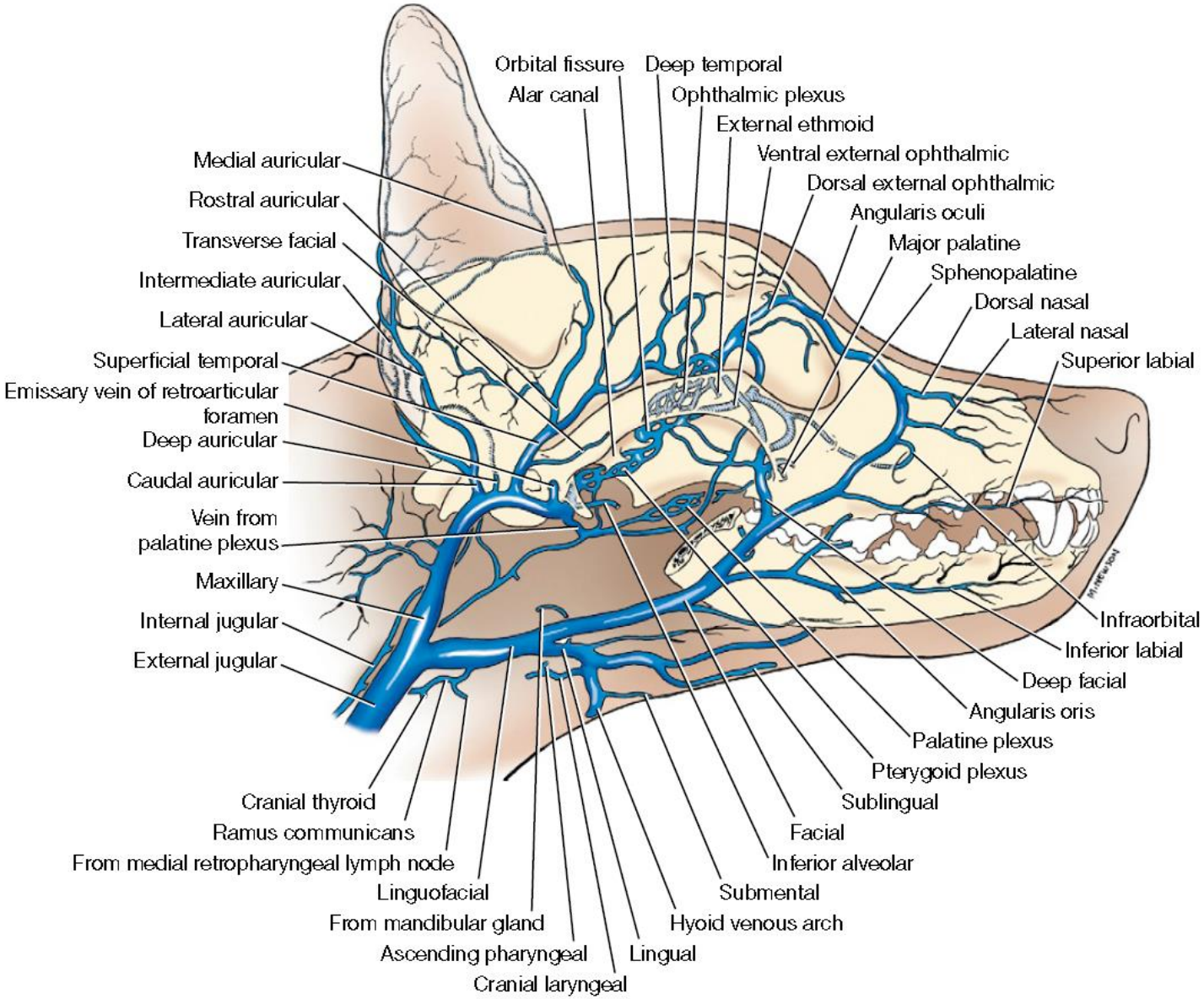

Fig. 5-40 Superficial veins of head, right lateral aspect.

Sistema cardiovascular, drenaje venoso de tórax, cuello y cabeza.

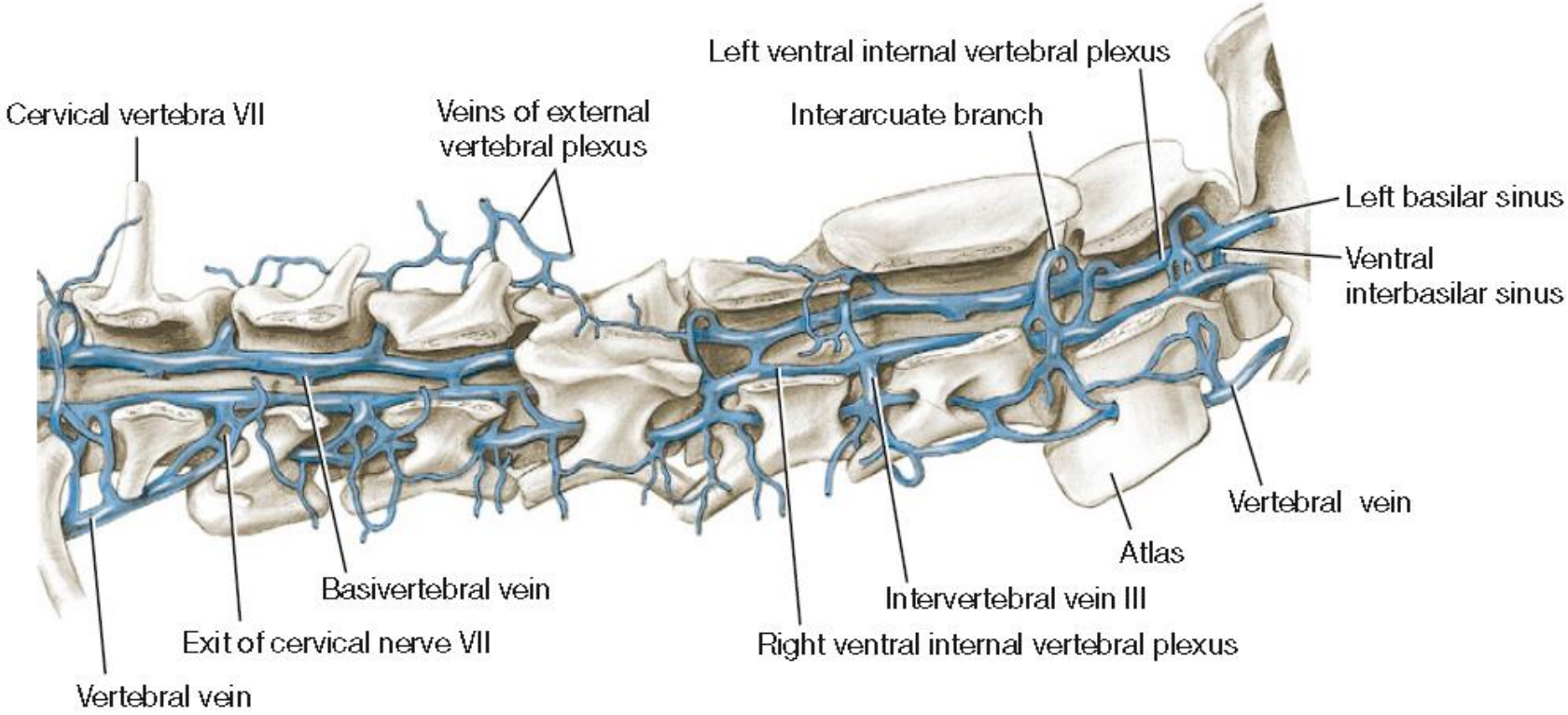

Fig. 6-4 Cervical vertebral veins, right lateral aspect. (From Reinhard K, Miller M, Evans H: The craniovertebral veins and sinuses of the dog, *Am J Anat* 11:67-87, 1962. Copyright © 1962 Wiley-Liss. Reprinted by permission of Wiley-Liss, Inc., a subsidiary of John Wiley & Sons, Inc.)

Sistema cardiovascular, drenaje venoso de tórax, cuello y cabeza.

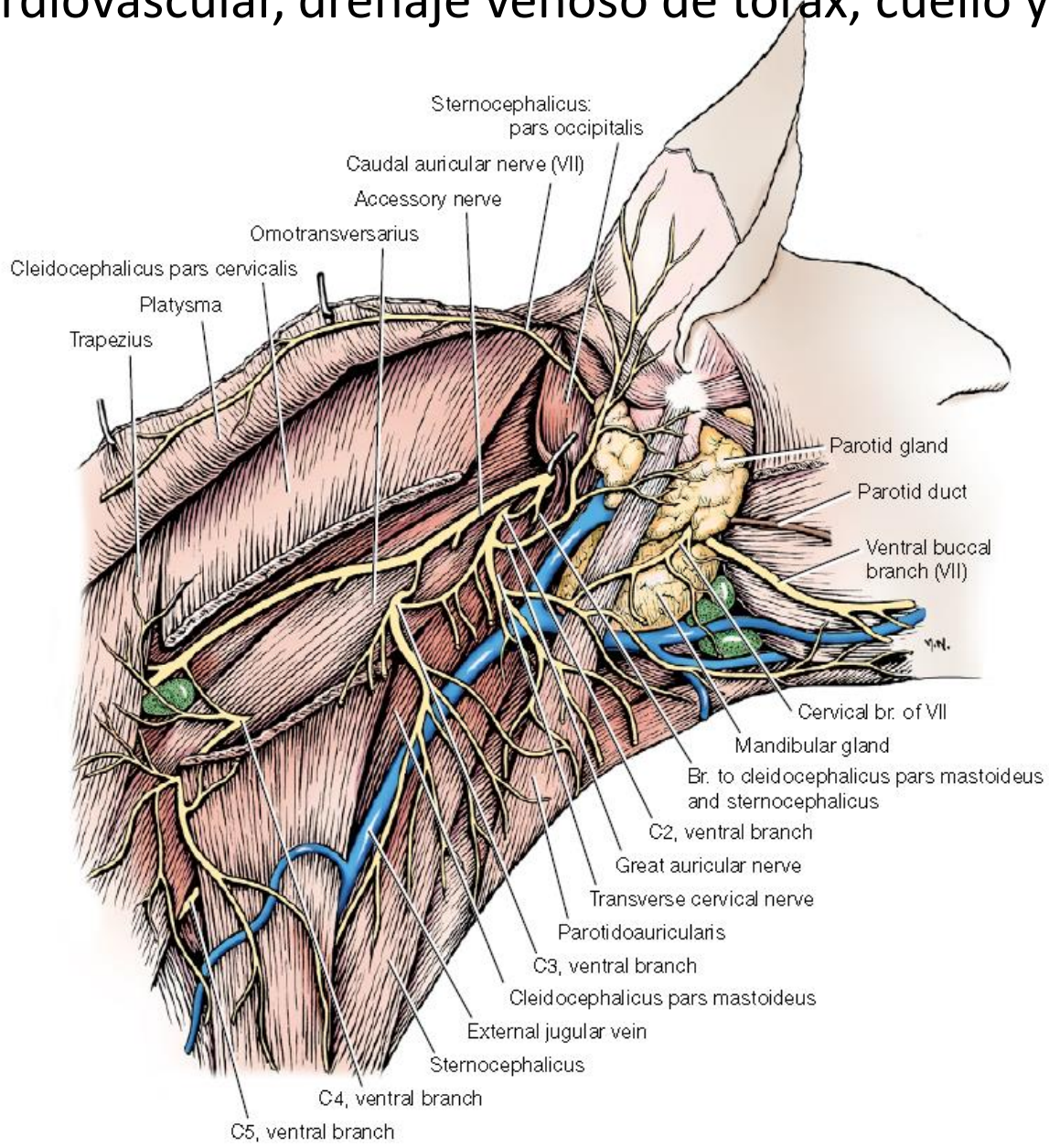

Fig. 3-2 Superficial nerves of the neck, lateral aspect.

Sistema cardiovascular, drenaje venoso de tórax, cuello y cabeza.

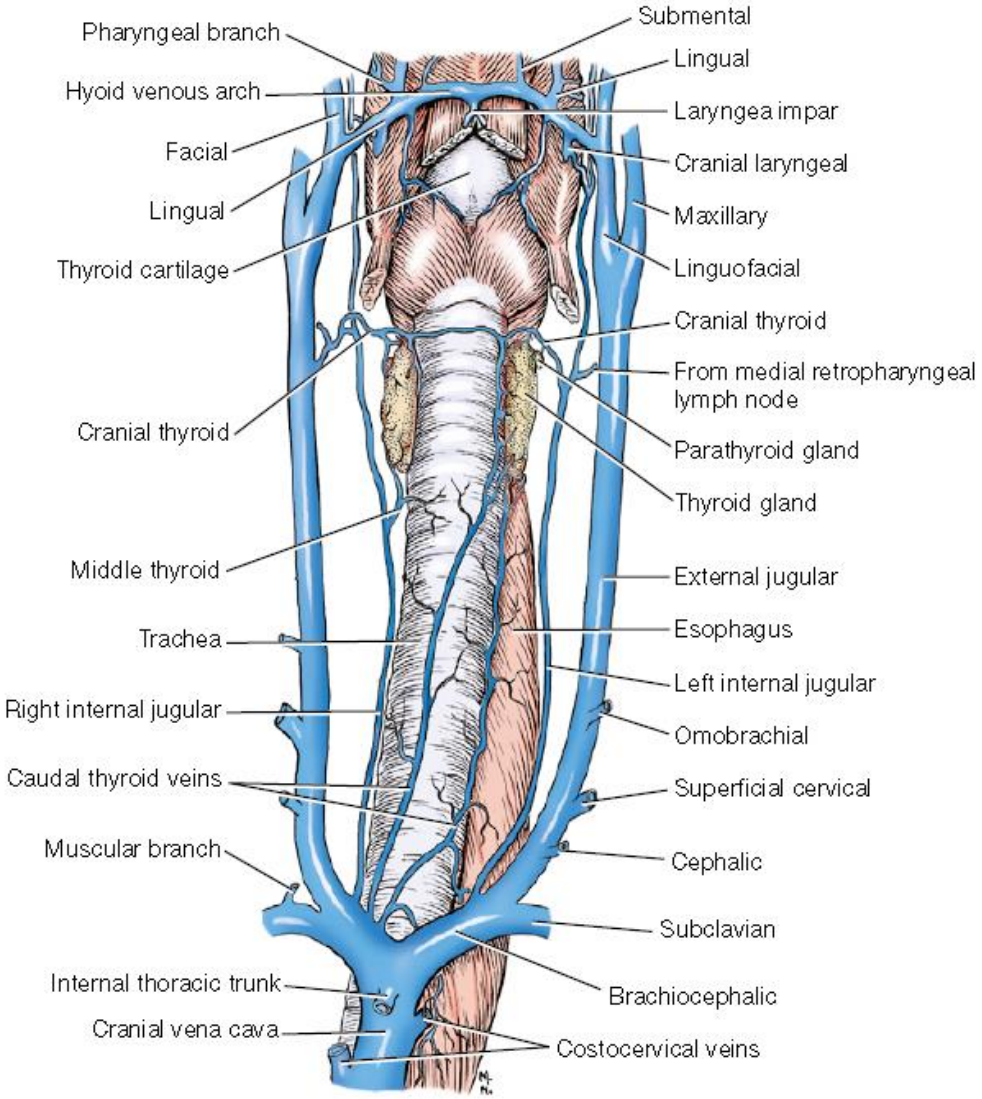

Fig. 3-15 Veins of the neck, ventral aspect.

Sistema cardiovascular, drenaje venoso de tórax, cuello y cabeza.

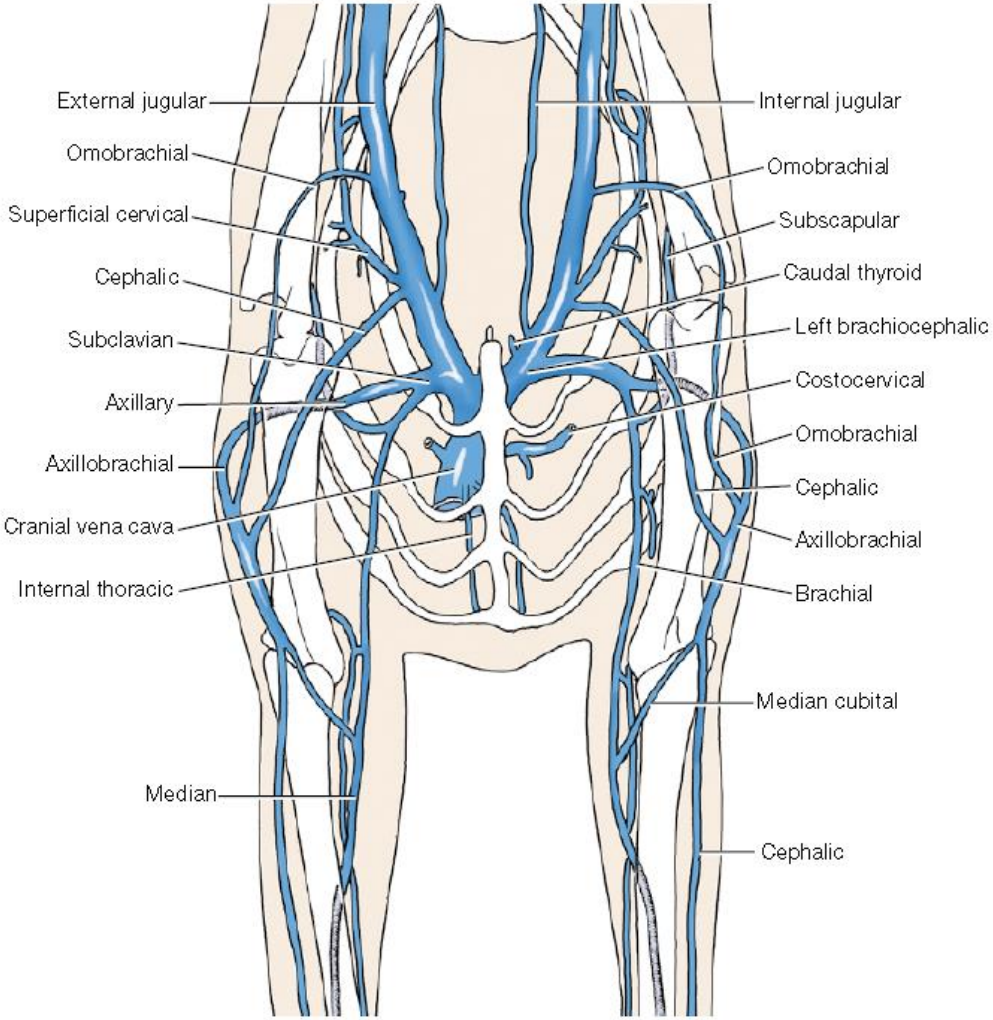

Fig. 3-35 Veins of neck, thoracic inlet, and proximal forelimb, schematic cranial aspect.

Sistema cardiovascular, drenaje venoso de tórax, cuello y cabeza e irrigación de abdomen y pelvis.

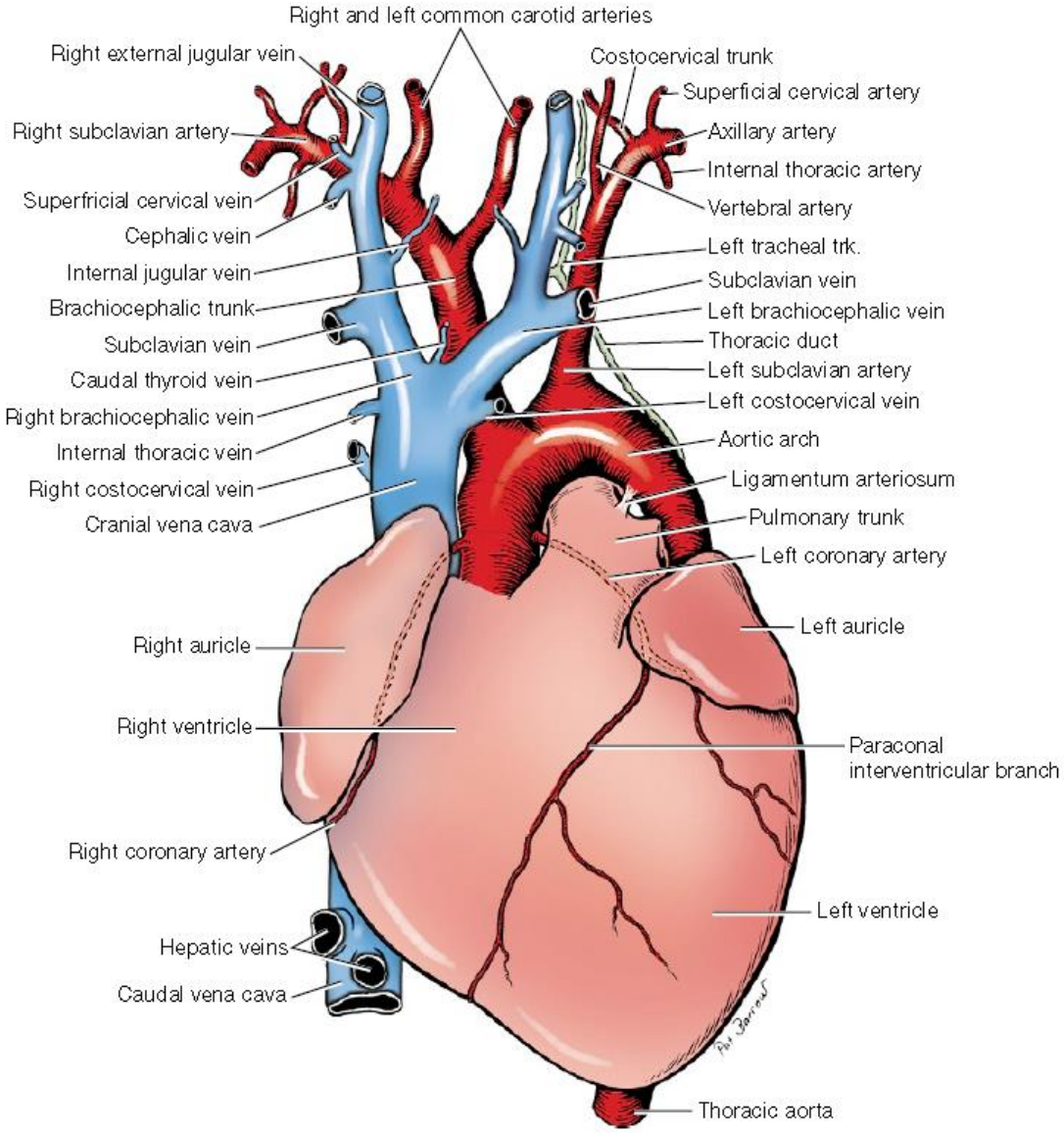

Fig. 3-17 Heart and great vessels, ventral view.

Sistema cardiovascular, irrigación de abdomen y pelvis.

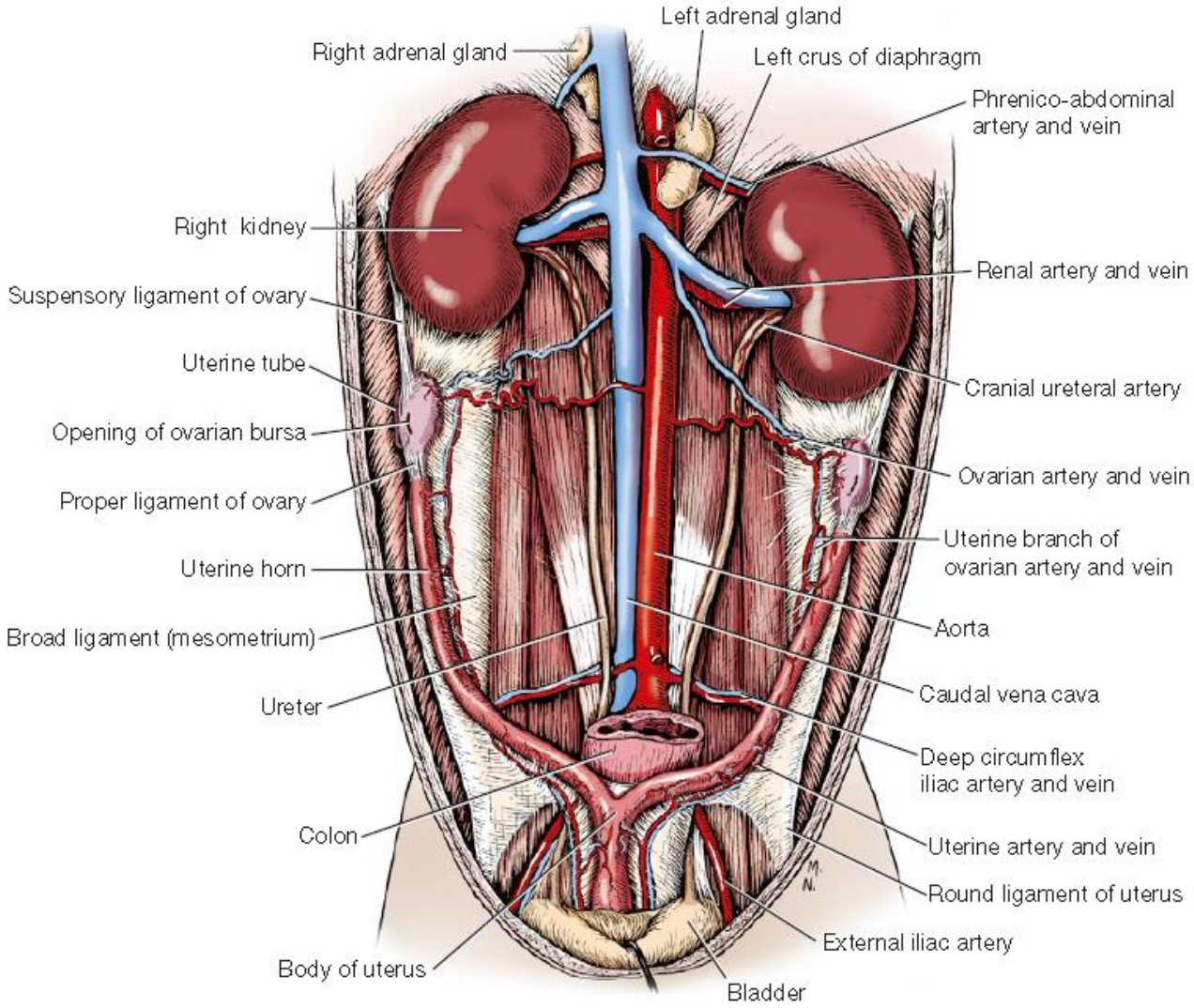

Fig. 4-12 Female urogenital system, ventral aspect.

Sistema cardiovascular, irrigación de abdomen y pelvis.

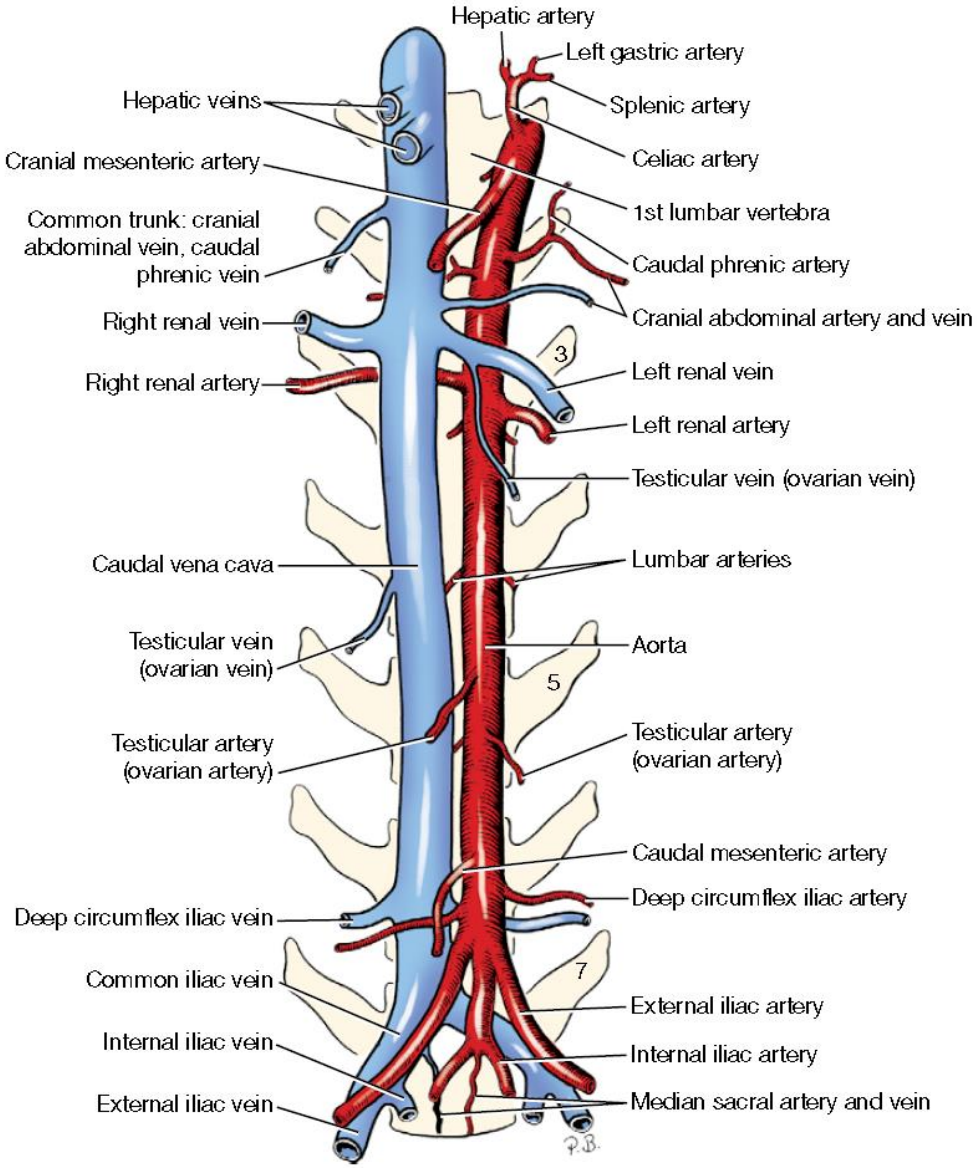

Fig. 4-28 Branches of abdominal aorta and tributaries of the caudal vena cava, ventral view.

Sistema cardiovascular, irrigación de abdomen y pelvis.

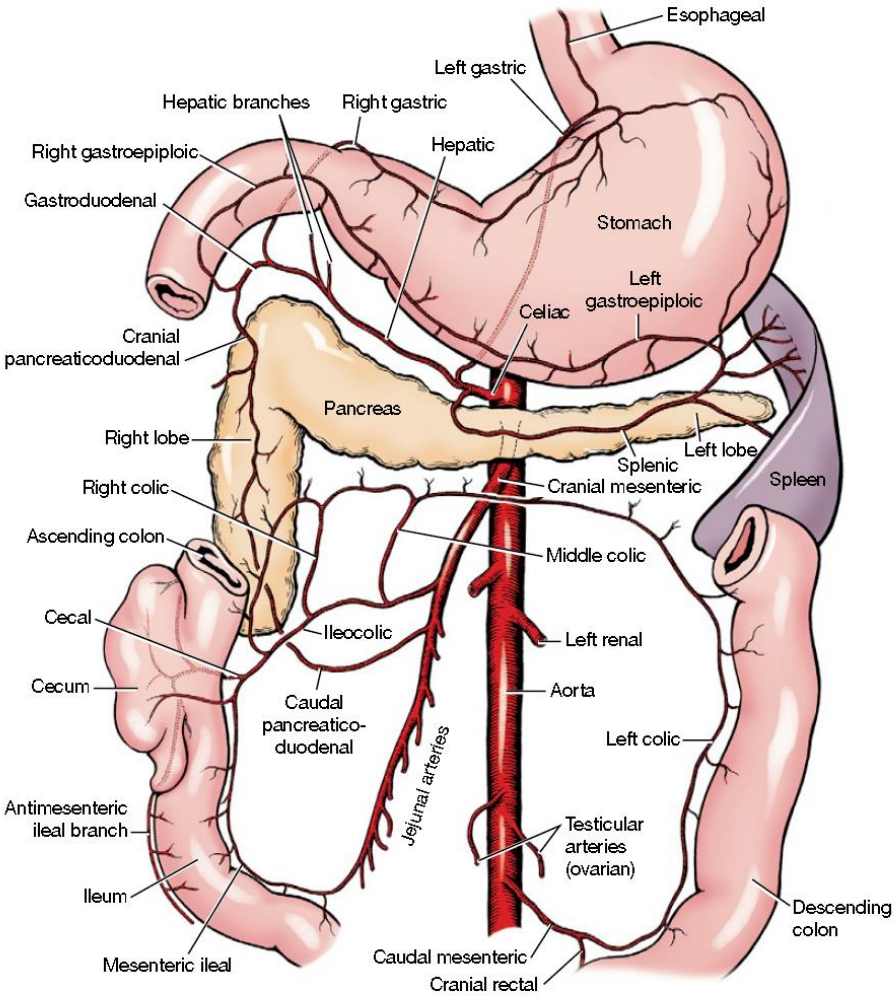

Fig. 4-29 Branches of celiac and cranial mesenteric arteries with principal anastomoses.

Sistema cardiovascular, irrigación de abdomen y pelvis.

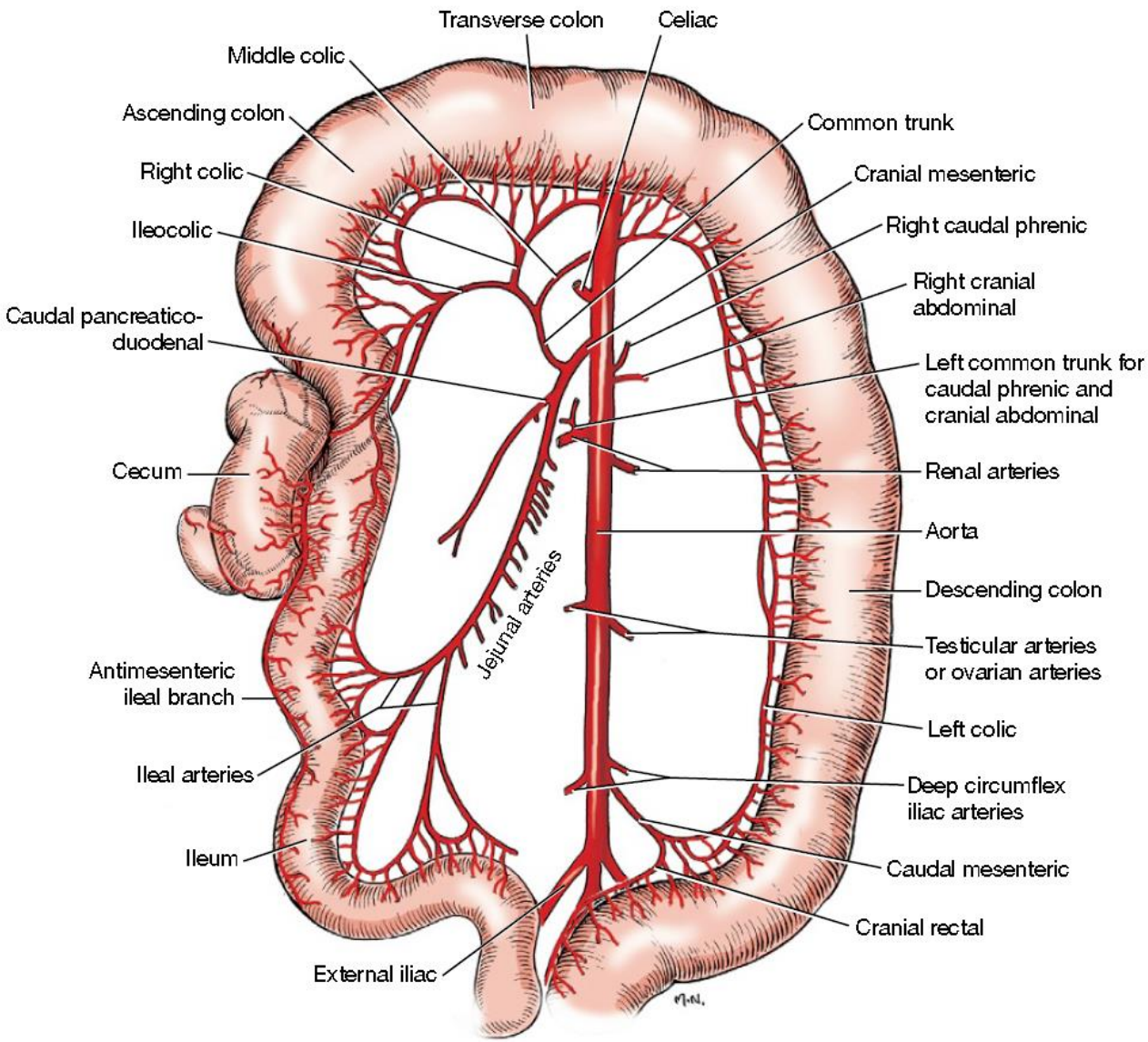

Fig. 4-31 Branches of cranial and caudal mesenteric arteries, ventral aspect.

Sistema cardiovascular, irrigación de abdomen y pelvis.

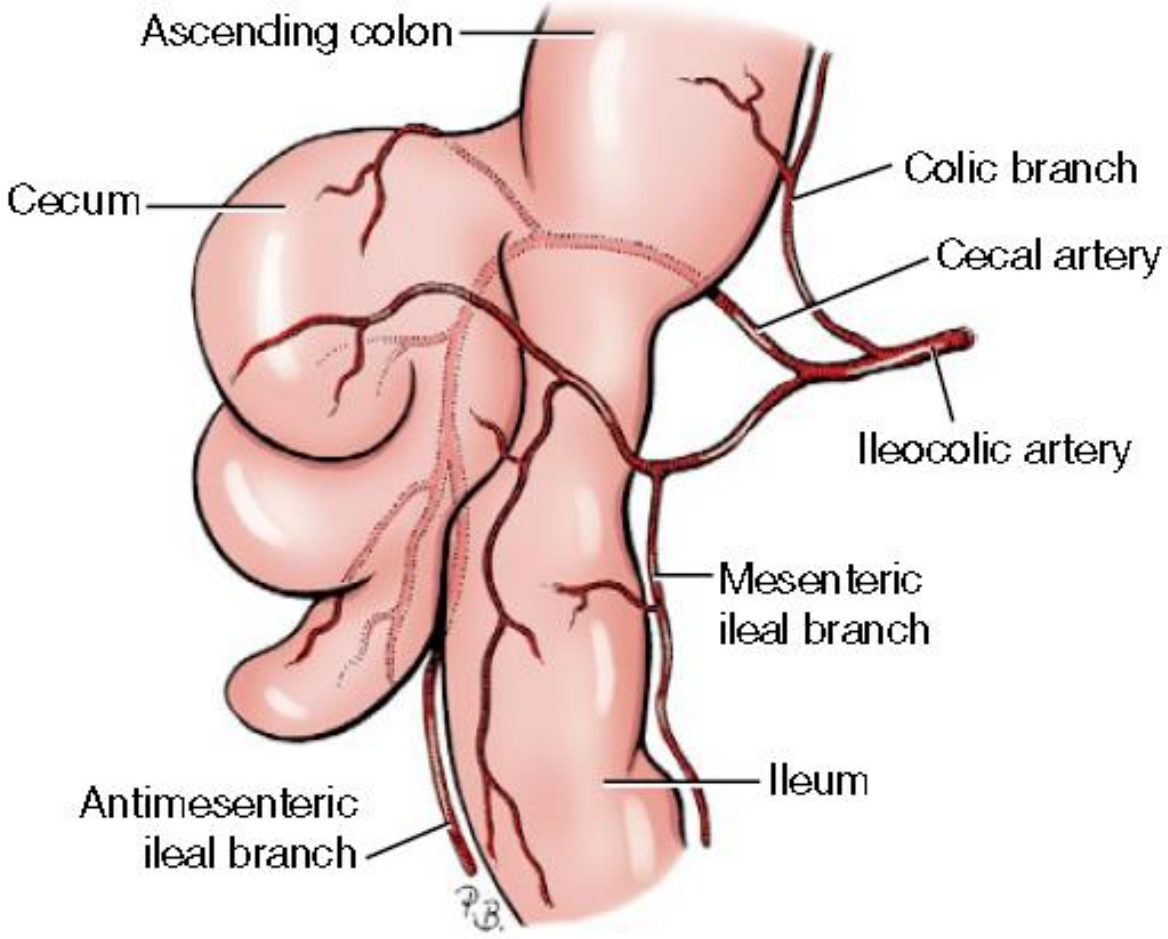

Fig. 4-32 Terminations of ileocolic artery.

Sistema cardiovascular, irrigación de abdomen y pelvis.

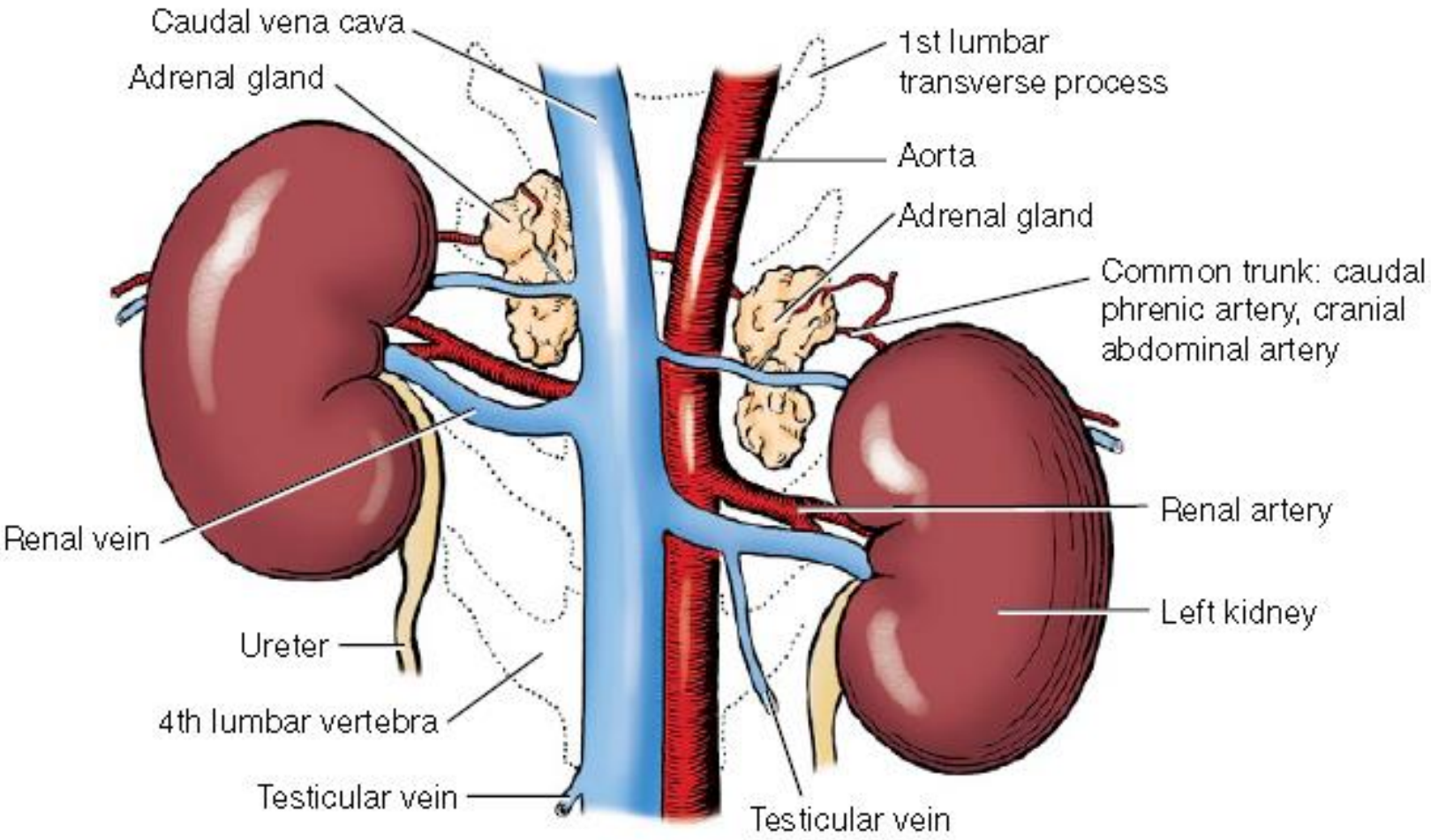

Fig. 4-22 Kidneys and adrenal glands, ventral view.

Sistema cardiovascular, irrigación de abdomen y pelvis.

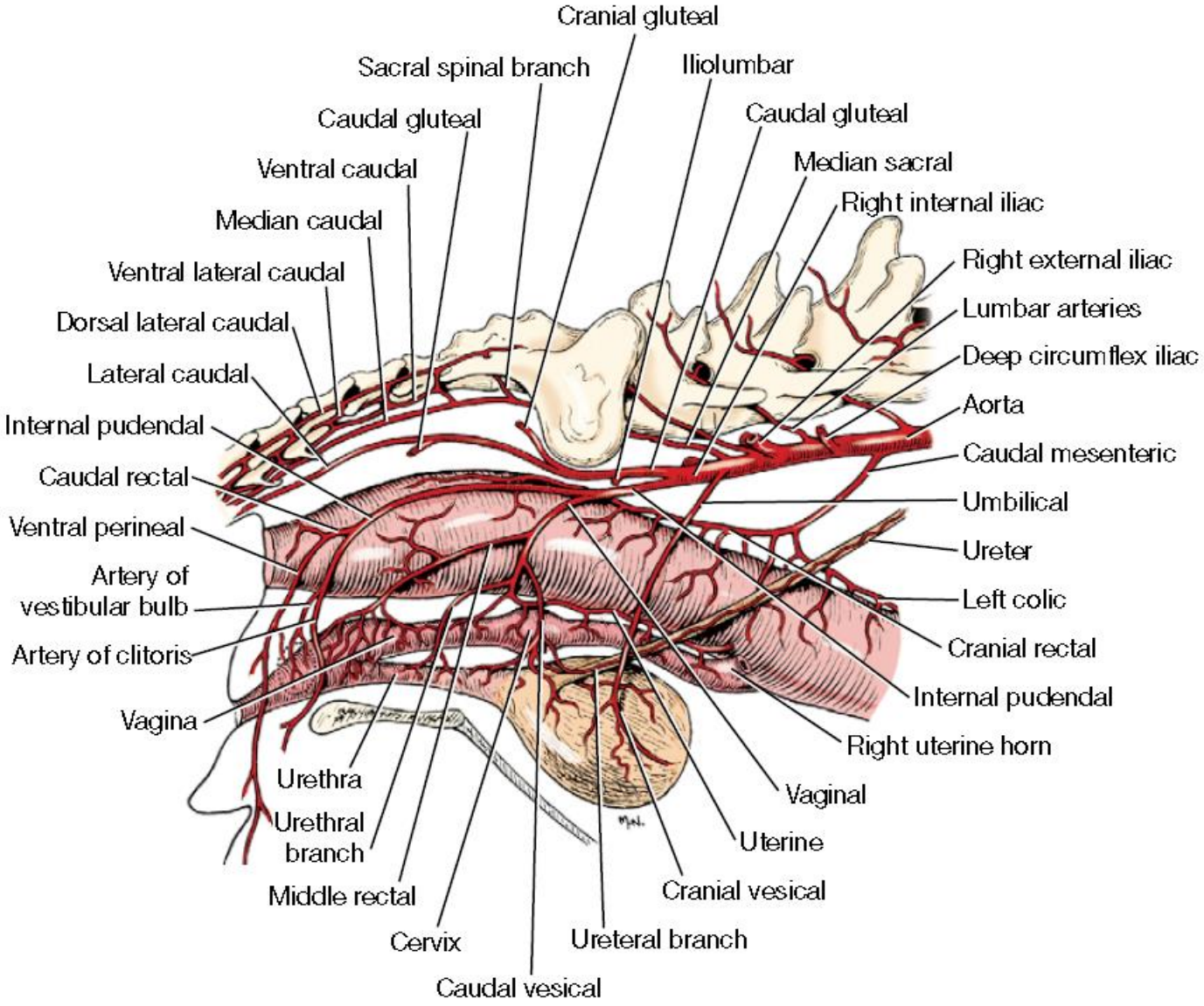

Fig. 4-38 Arteries of female pelvic viscera, right lateral view.

Sistema cardiovascular, irrigación de abdomen y pelvis.

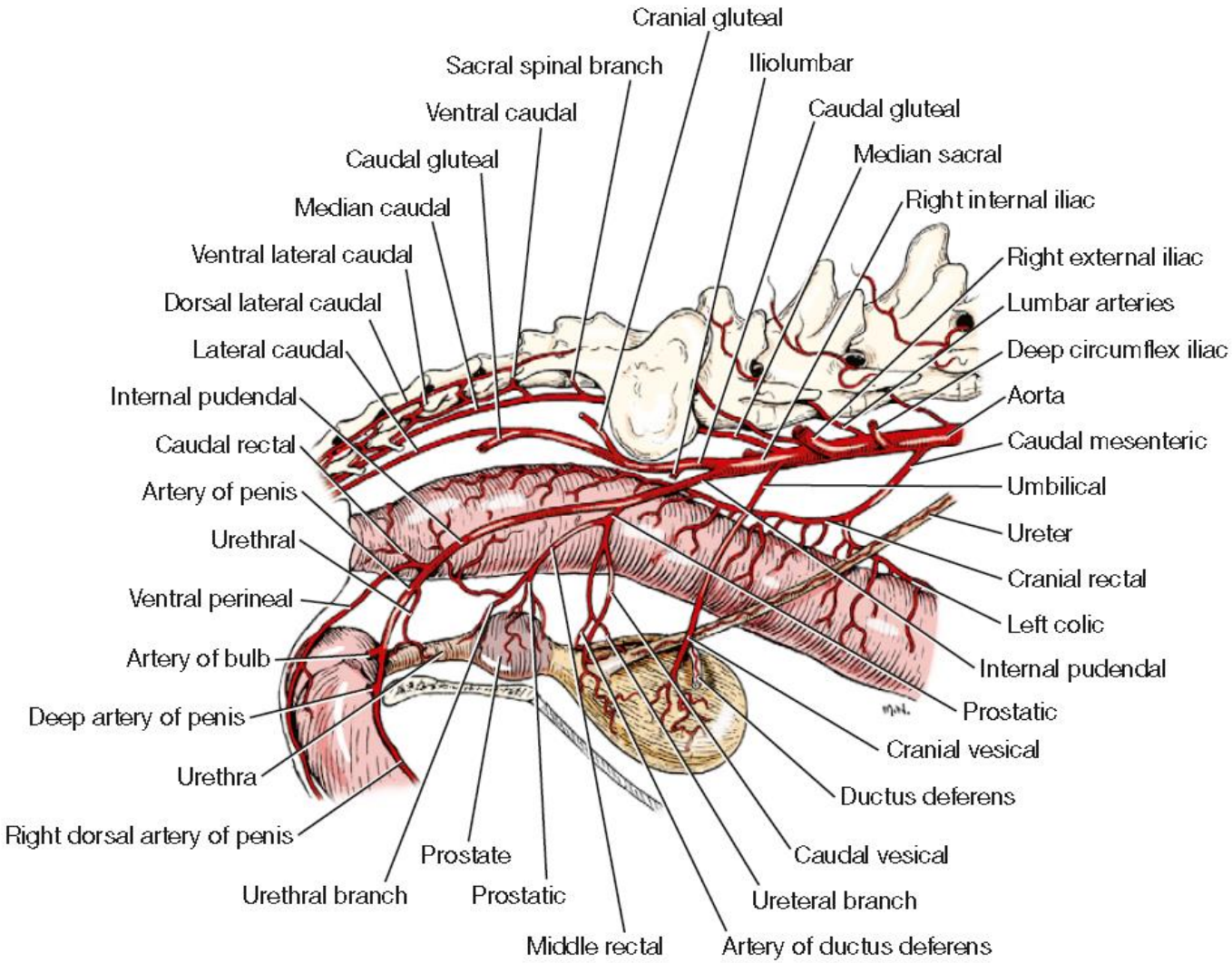

Fig. 4-39 Arteries of male pelvic viscera, right lateral view.

Sistema cardiovascular, irrigación de abdomen y pelvis.

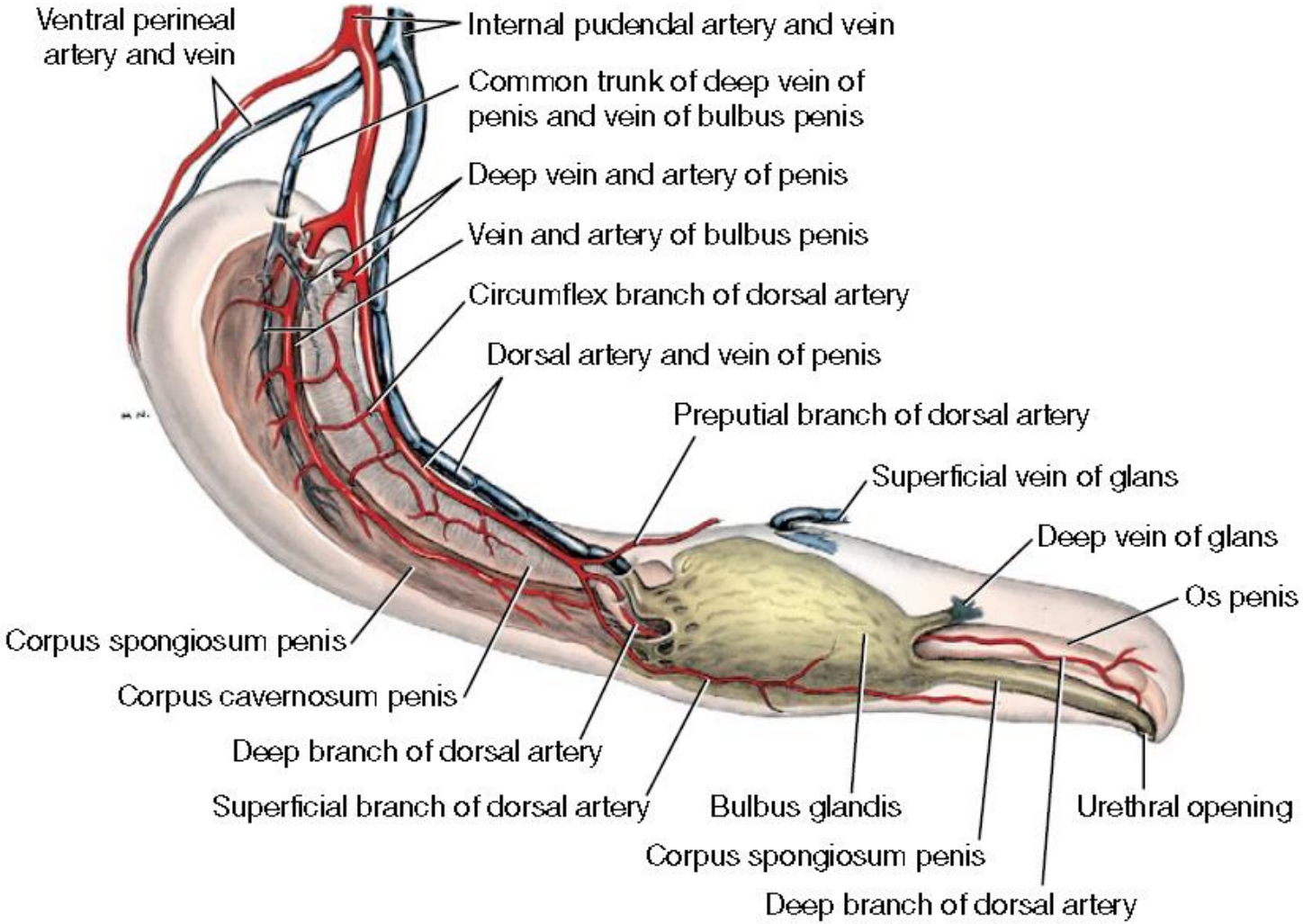

Fig. 4-48 Semidiagrammatic view of penis. The vessels of only one side are shown.

Sistema cardiovascular, irrigación de abdomen y pelvis.

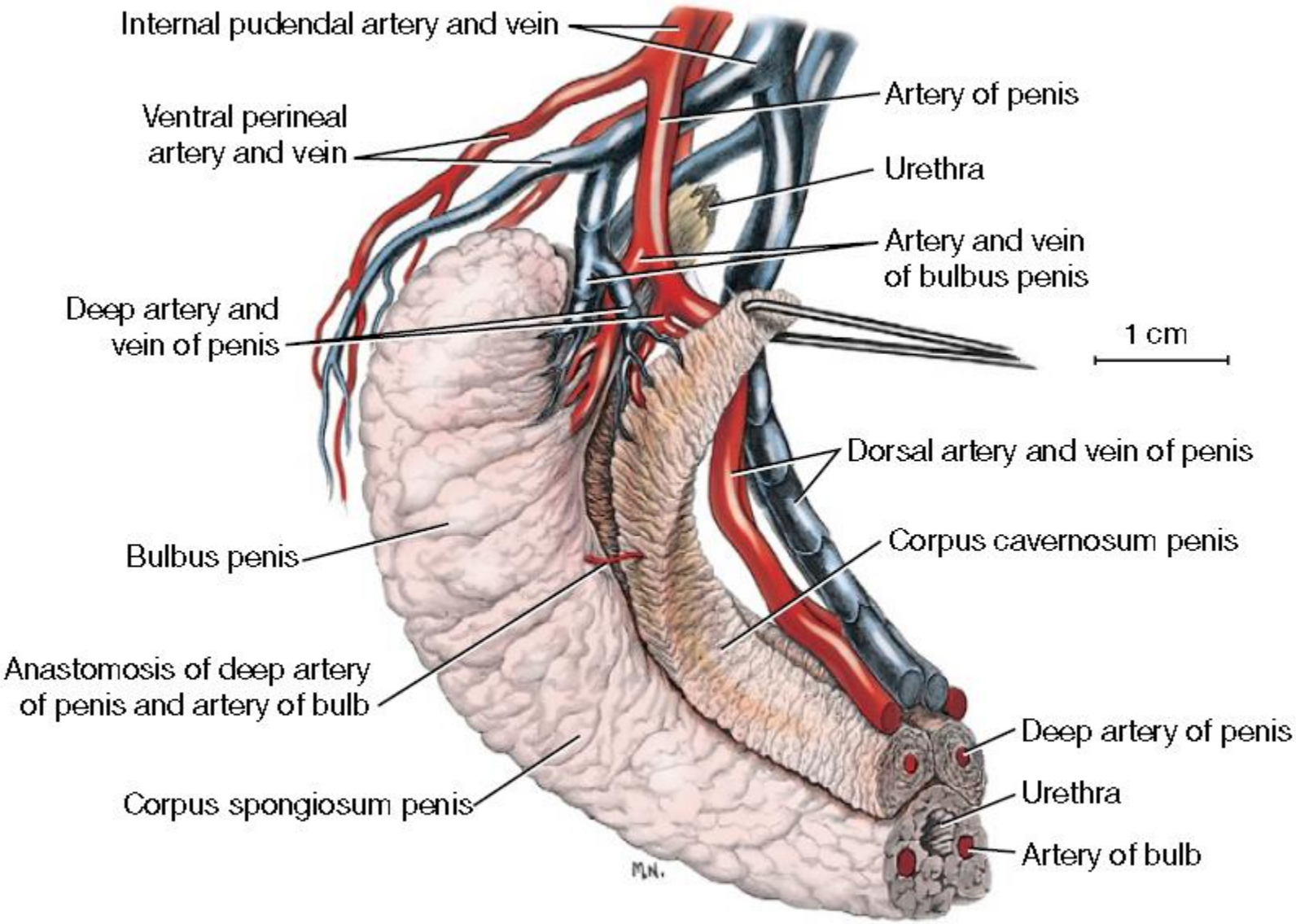

Fig. 4-49 Corrosion preparation of proximal half of the penis.

Sistema cardiovascular, irrigación de abdomen y pelvis.

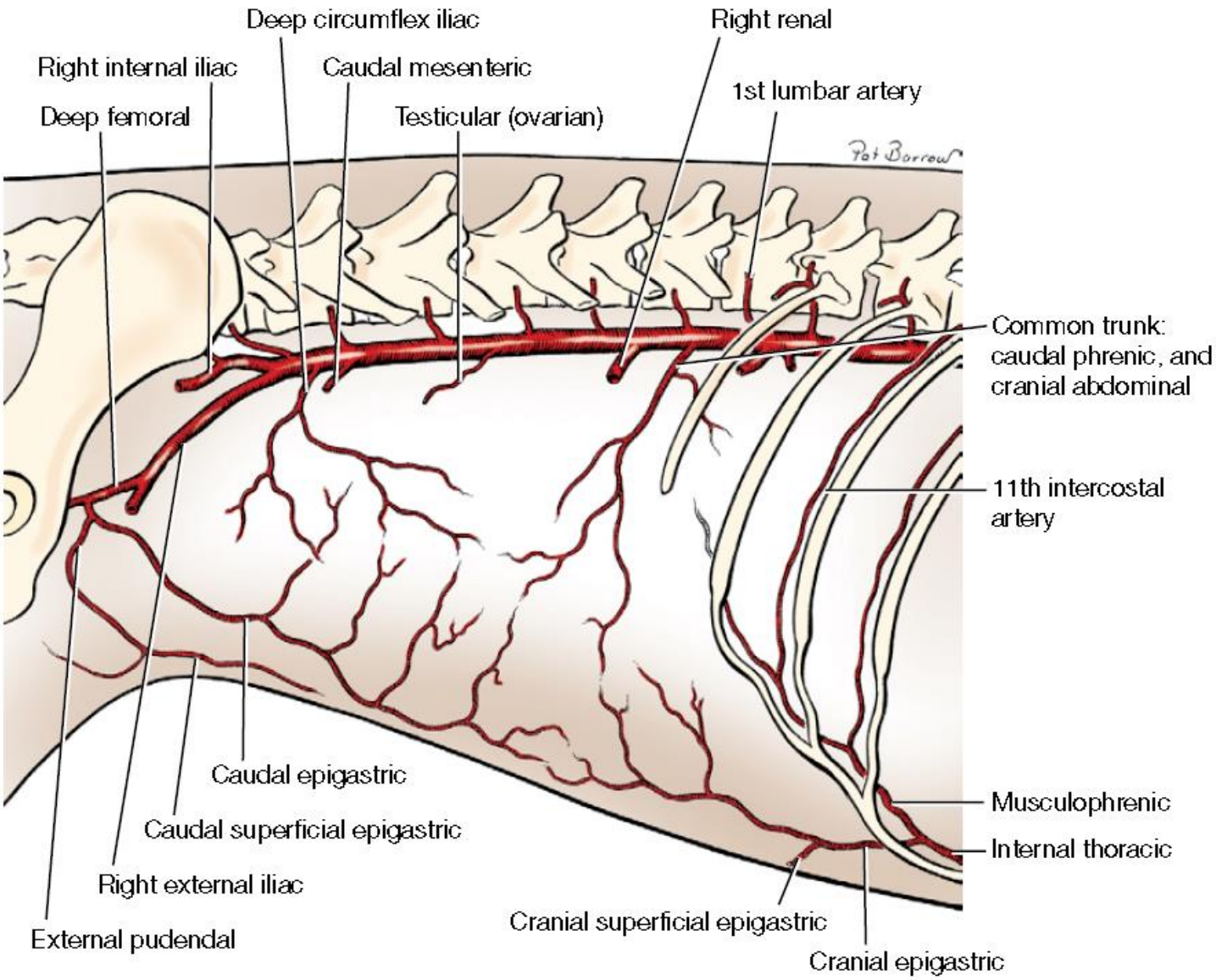

Fig. 4-33 Abdominal aorta in relation to epigastric arteries, lateral view.

Sistema cardiovascular, drenaje venoso de abdomen y pelvis.

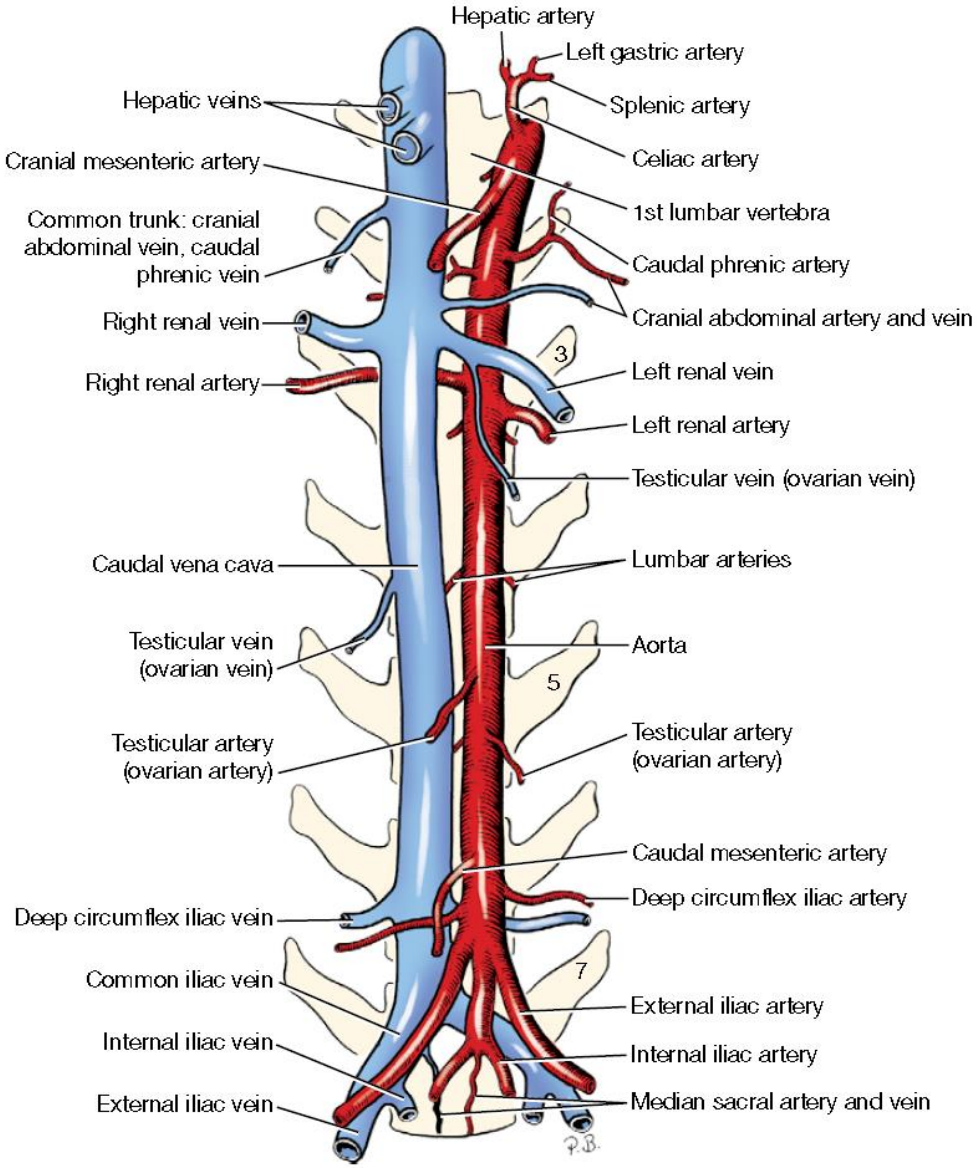

Fig. 4-28 Branches of abdominal aorta and tributaries of the caudal vena cava, ventral view.

Sistema cardiovascular, drenaje venoso de abdomen y pelvis.

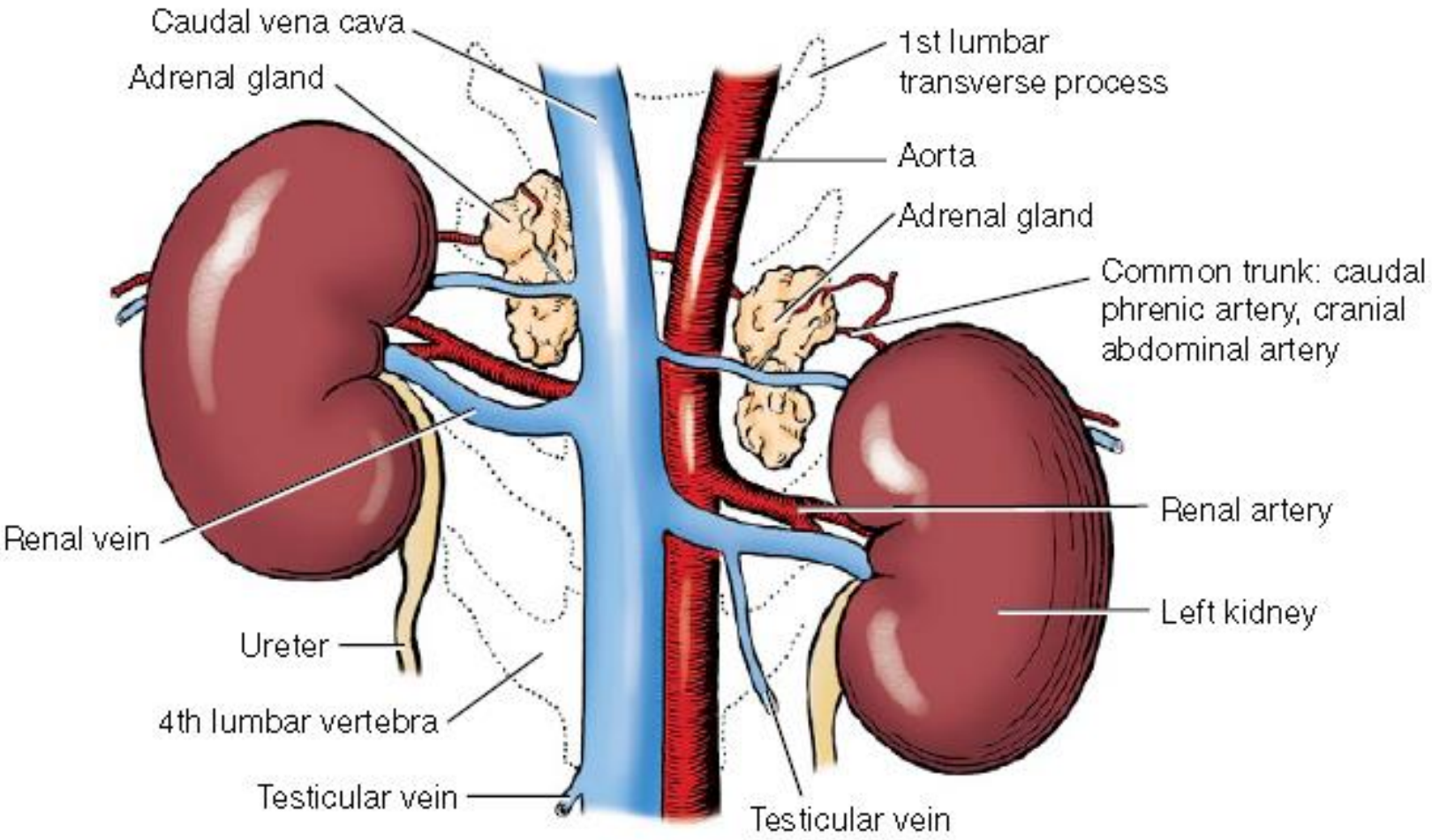

Fig. 4-22 Kidneys and adrenal glands, ventral view.

Sistema cardiovascular, drenaje venoso de abdomen y pelvis.

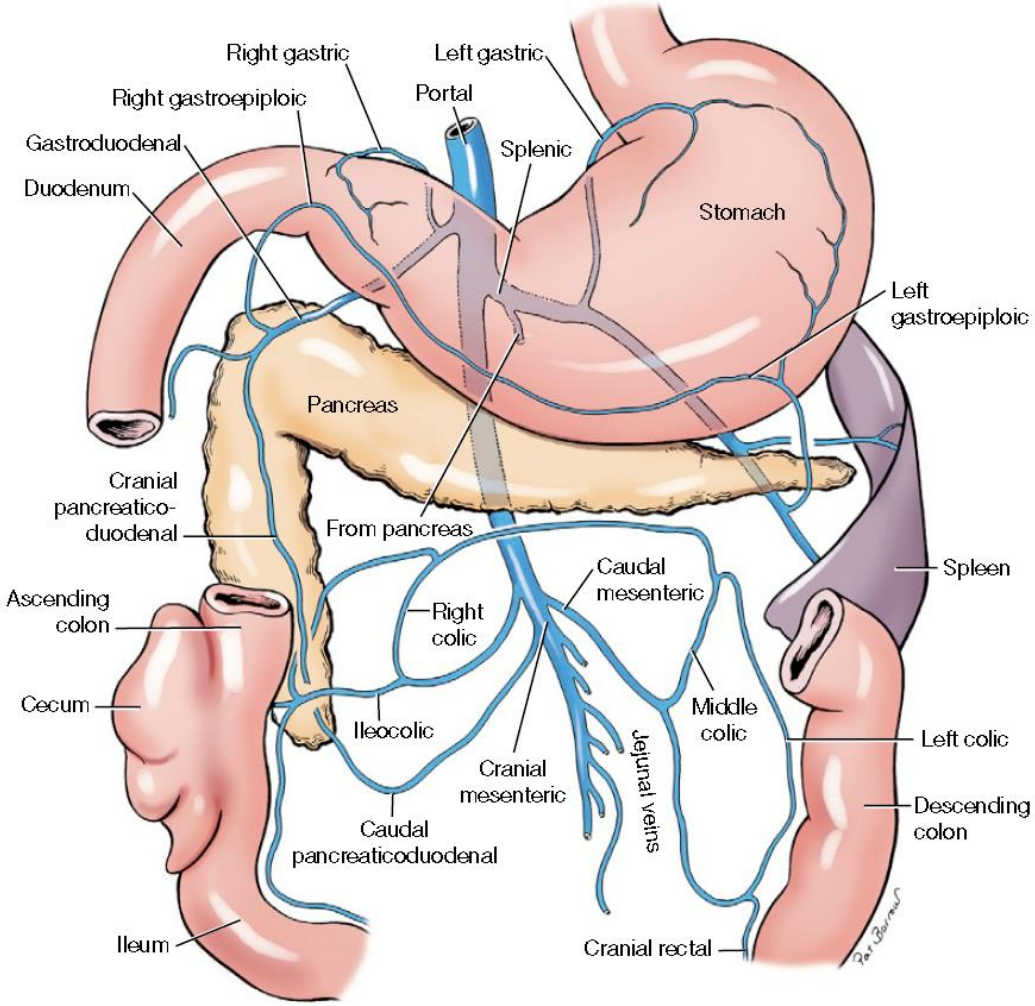

Fig. 4-34 Tributaries of portal vein, ventral view.

Sistema cardiovascular, drenaje venoso de abdomen y pelvis.

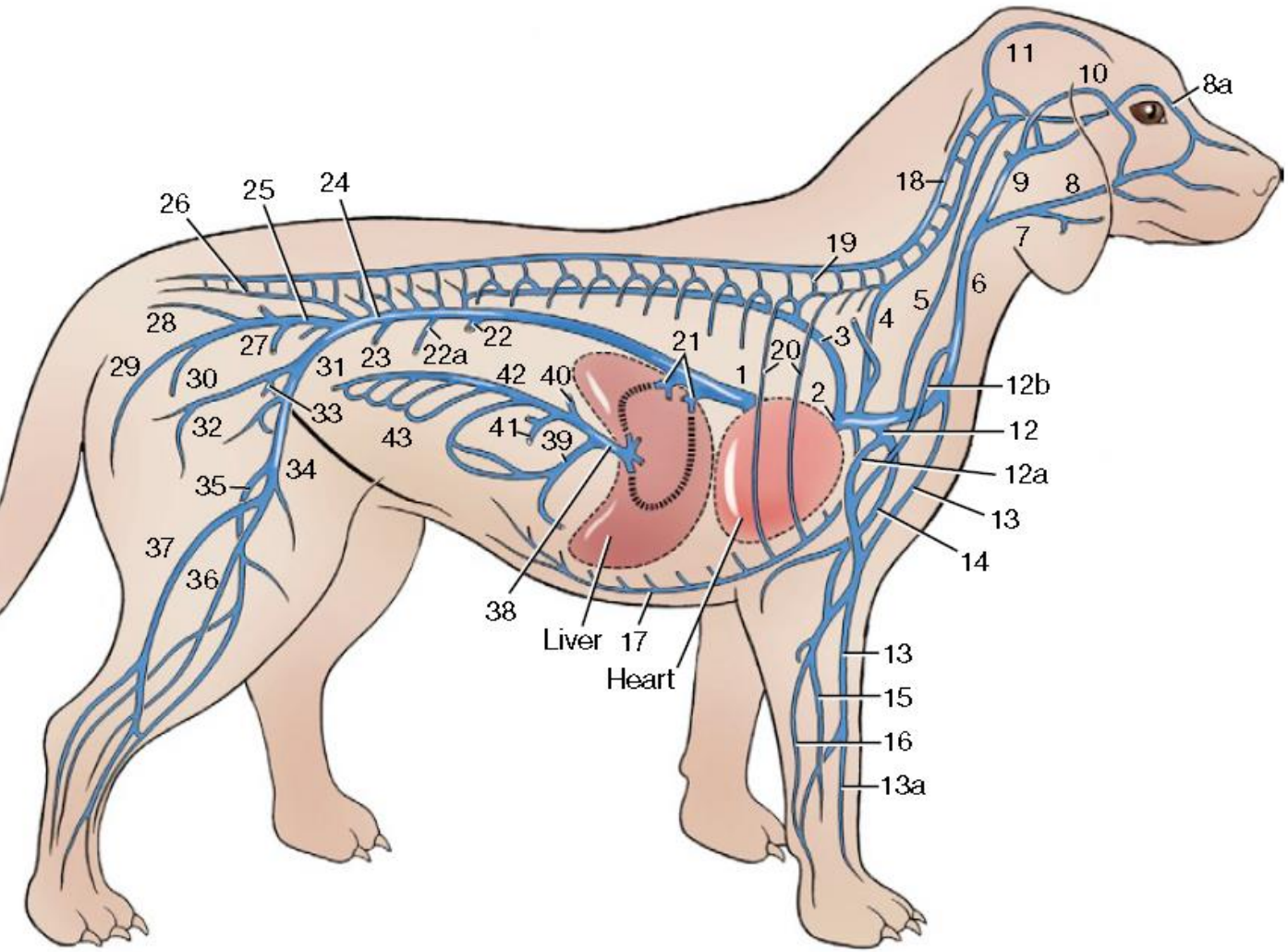

Fig. 4-35 Schema of the venous system, right lateral view.

1. Caudal vena cava
2. Cranial vena cava
3. Azygos
4. Vertebral
5. Internal jugular
6. External jugular
7. Linguofacial
8. Facial
8a. Angularis oculi
9. Maxillary
10. Superficial temporal
11. Dorsal sagittal sinus
12. Axillary
12a. Axillobrachial
12b. Omobrachial
13. Cephalic
13a. Accessory cephalic
14. Brachial
15. Median
16. Ulnar
17. Internal thoracic
18. Right internal ventral vertebral venous plexus
19. Intervertebral
20. Intercostal
21. Hepatic
22. Renal
22a. Testicular or ovarian
23. Deep circumflex iliac
24. Common iliac
25. Right internal iliac
26. Median sacral
27. Vaginal or prostatic
28. Lateral caudal
29. Caudal gluteal
30. Internal pudendal
31. Right external iliac
32. Deep femoral
33. Pudendoepigastric trunk
34. Femoral
35. Medial saphenous
36. Cranial tibial
37. Lateral saphenous
38. Portal
39. Gastroduodenal
40. Splenic
41. Caudal mesenteric
42. Cranial mesenteric
43. Jejunal

Sistema cardiovascular, drenaje venoso de abdomen y pelvis.

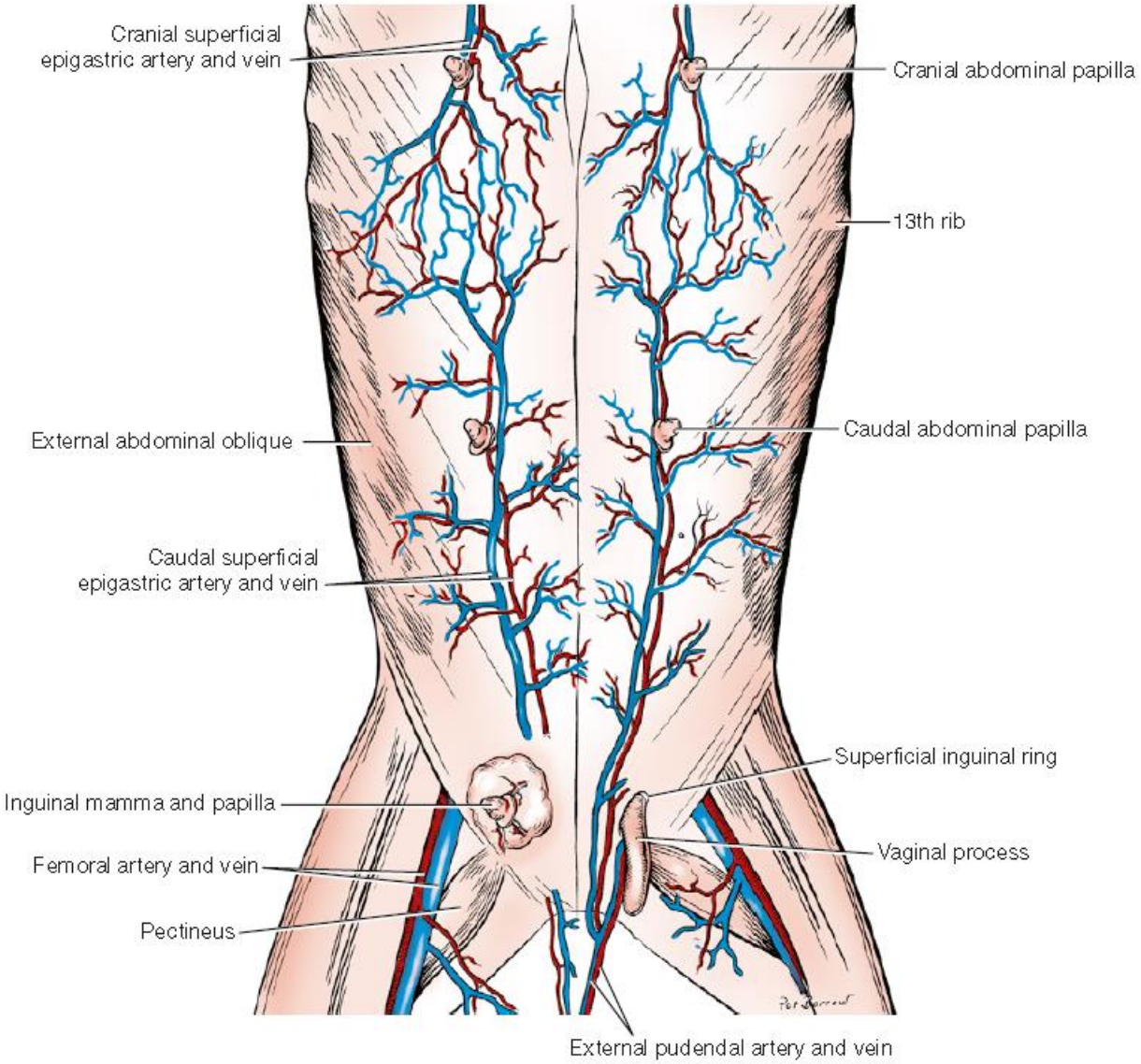

Fig. 4-2 Superficial veins and arteries of abdomen. Left vaginal process exposed.

Sistema cardiovascular, circulación fetal.

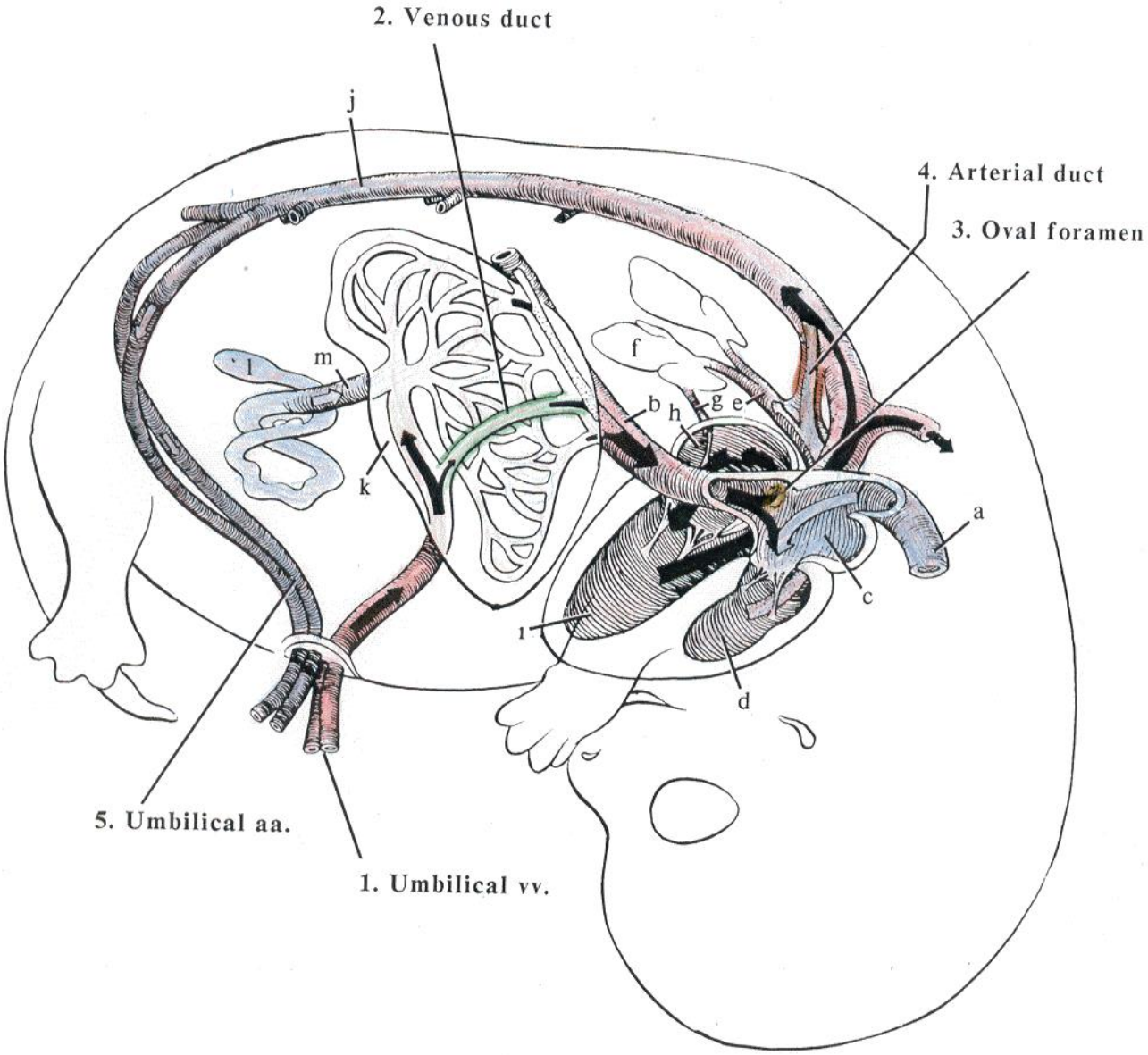

Universidad Santo Tomás.
Escuela de Medicina Veterinaria.
Anatomía I.

Sistema cardiovascular.

Cabeza, cuello, tronco y cola.

Dr. César Caro Munizaga, DVM.